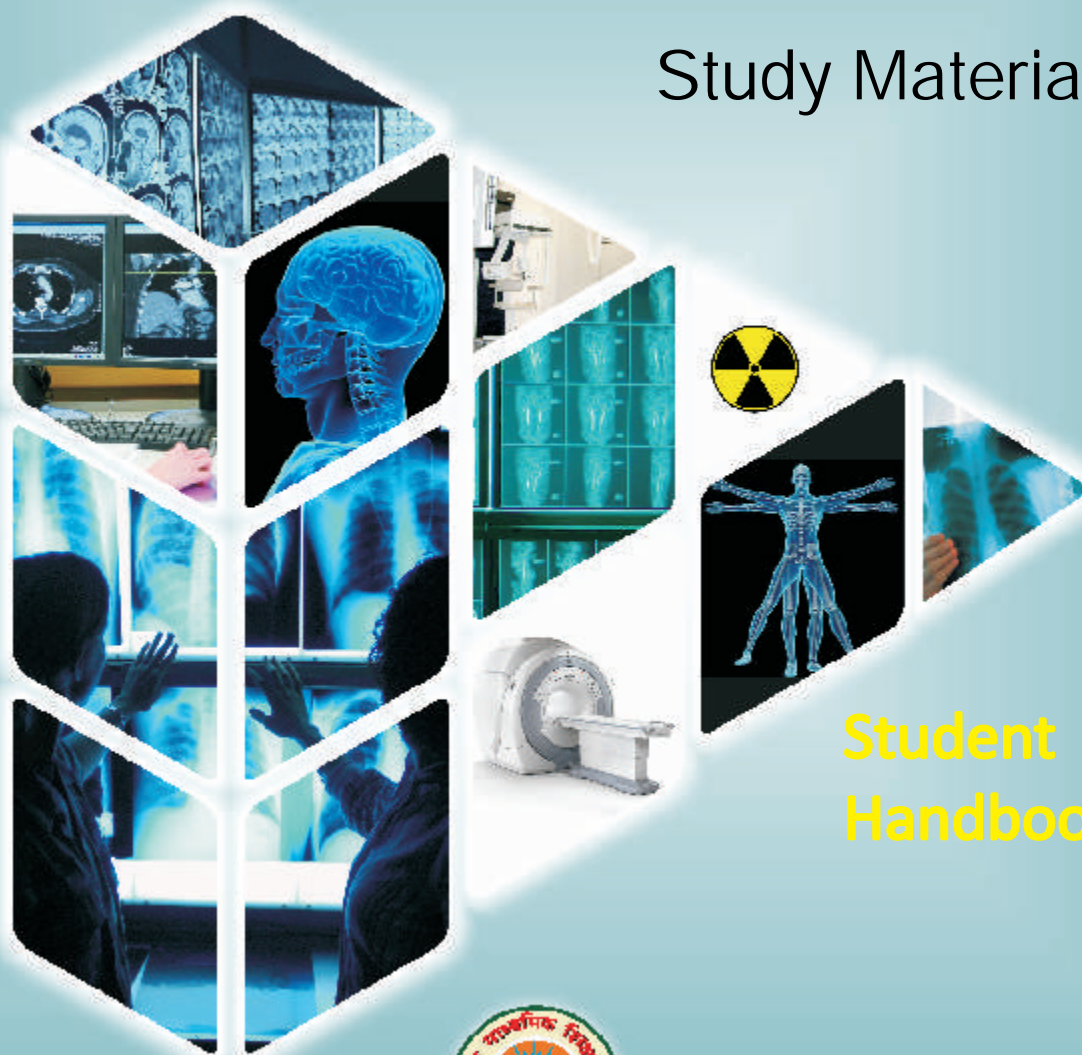


**CLASS-XI**



# DIAGNOSTIC RADIOLOGY

Study Material



**Student  
Handbook**



**Central Board of Secondary Education**

Shiksha Kendra, 2, Community Centre, Preet Vihar, Delhi-110301





# ***Diagnostic Radiology***

*(Student Handbook)*

## **Class XI**



**CENTRAL BOARD OF SECONDARY EDUCATION**

Shiksha Kendra, 2, Community Centre, Preet Vihar, Delhi-110301



**Diagnostic Radiology**  
Student Handbook, Class XI

**Price :** ₹

**First Edition :** May, 2016, CBSE

**Copies :**

**Paper Used :** 80 gsm. CBSE Water Mark White Maplitho

No Part of this publication may be reproduced, stored in a retrieval system or transmitted, in any form or by any means, electronic, mechanical photocopying, recording or otherwise without the prior permission of the publisher.

**PUBLISHED BY :** The Secretary, Central Board of Secondary Education,  
Shiksha Kendra, 2, Community Centre, Preet Vihar, Delhi - 110301  
**DESIGN & LAYOUT BY :** M/s. India Offset Press, A-1, Mayapuri Industrial Area, Phase-1,  
New Delhi - 110064  
**PRINTED BY :**



# भारत का संविधान

## उद्देशिका

हम, भारत के लोग, भारत को एक सम्पूर्ण 'प्रभुत्व-संपन्न समाजवादी पंथनिरपेक्ष लोकतंत्रात्मक गणराज्य बनाने के लिए, तथा उसके समस्त नागरिकों को:

सामाजिक, आर्थिक और राजनैतिक न्याय,  
विचार, अभिव्यक्ति, विश्वास, धर्म

और उपासना की स्वतंत्रता,  
प्रतिष्ठा और अवसर की समता

प्राप्त कराने के लिए  
तथा उन सब में व्यक्ति की गरिमा

<sup>2</sup>और राष्ट्र की एकता और अखंडता  
सुनिश्चित करने वाली बंधुता बढ़ाने के लिए

दृढ़संकल्प होकर अपनी इस संविधान सभा में आज तारीख 26 नवम्बर, 1949 ई० को एतद्वारा इस संविधान को अंगीकृत, अधिनियमित और आत्मार्पित करते हैं।

- 
1. संविधान ( बयालीसवां संशोधन ) अधिनियम, 1976 की धारा 2 द्वारा ( 3.1.1977 ) से “प्रभुत्व-संपन्न लोकतंत्रात्मक गणराज्य” के स्थान पर प्रतिस्थापित।
  2. संविधान ( बयालीसवां संशोधन ) अधिनियम, 1976 की धारा 2 द्वारा ( 3.1.1977 ) से “राष्ट्र की एकता” के स्थान पर प्रतिस्थापित।
- 

## भाग 4 क

## मूल कर्तव्य

**51 क. मूल कर्तव्य** – भारत के प्रत्येक नागरिक का यह कर्तव्य होगा कि वह –

- (क) संविधान का पालन करे और उसके आदर्शों, संस्थाओं, राष्ट्रध्वज और राष्ट्रगान का आदर करे;
- (ख) स्वतंत्रता के लिए हमारे राष्ट्रीय आंदोलन को प्रेरित करने वाले उच्च आदर्शों को हृदय में संजोए रखे और उनका पालन करे;
- (ग) भारत की प्रभुता, एकता और अखंडता की रक्षा करे और उसे अक्षुण्ण रखे;
- (घ) देश की रक्षा करे और आह्वान किए जाने पर राष्ट्र की सेवा करे;
- (ङ) भारत के सभी लोगों में समरसता और समान भ्रातृत्व की भावना का निर्माण करे जो धर्म, भाषा और प्रदेश या वर्ग पर आधारित सभी भेदभाव से परे हों, ऐसी प्रथाओं का त्याग करे जो स्त्रियों के सम्मान के विरुद्ध हैं;
- (च) हमारी सामासिक संस्कृति की गौरवशाली परंपरा का महत्त्व समझे और उसका परिरक्षण करे;
- (छ) प्राकृतिक पर्यावरण की जिसके अंतर्गत वन, झील, नदी, और वन्य जीव हैं, रक्षा करे और उसका संवर्धन करे तथा प्राणी मात्र के प्रति दयाभाव रखे;
- (ज) वैज्ञानिक दृष्टिकोण, मानववाद और ज्ञानार्जन तथा सुधार की भावना का विकास करे;
- (झ) सार्वजनिक संपत्ति को सुरक्षित रखे और हिंसा से दूर रहे;
- (ञ) व्यक्तिगत और सामूहिक गतिविधियों के सभी क्षेत्रों में उत्कर्ष की ओर बढ़ने का सतत प्रयास करे जिससे राष्ट्र निरंतर बढ़ते हुए प्रयत्न और उपलब्धि की नई उंचाइयों को छू ले;
- <sup>1</sup>(ट) यदि माता-पिता या संरक्षक हैं, छह वर्ष से चौदह वर्ष तक की आयु वाले अपने, यथास्थिति, बालक या प्रतिपाल्य के लिये शिक्षा के अवसर प्रदान करे।

- 
1. संविधान ( छयासीवां संशोधन ) अधिनियम, 2002 की धारा 4 द्वारा प्रतिस्थापित।

# THE CONSTITUTION OF INDIA

## PREAMBLE

**WE, THE PEOPLE OF INDIA**, having solemnly resolved to constitute India into a **'SOVEREIGN SOCIALIST SECULAR DEMOCRATIC REPUBLIC'** and to secure to all its citizens :

**JUSTICE**, social, economic and political;

**LIBERTY** of thought, expression, belief, faith and worship;

**EQUALITY** of status and of opportunity; and to promote among them all

**FRATERNITY** assuring the dignity of the individual and the<sup>2</sup>unity and integrity of the Nation;

**IN OUR CONSTITUENT ASSEMBLY** this twenty-sixth day of November, 1949, do **HEREBY ADOPT, ENACT AND GIVE TO OURSELVES THIS CONSTITUTION.**

---

1. Subs. by the Constitution (Forty-Second Amendment) Act. 1976, sec. 2, for "Sovereign Democratic Republic" (w.e.f. 3.1.1977)

2. Subs. by the Constitution (Forty-Second Amendment) Act. 1976, sec. 2, for "unity of the Nation" (w.e.f. 3.1.1977)

---

# THE CONSTITUTION OF INDIA

## Chapter IV A

### FUNDAMENTAL DUTIES

#### ARTICLE 51A

**Fundamental Duties** - It shall be the duty of every citizen of India-

- (a) to abide by the Constitution and respect its ideals and institutions, the National Flag and the National Anthem;
- (b) to cherish and follow the noble ideals which inspired our national struggle for freedom;
- (c) to uphold and protect the sovereignty, unity and integrity of India;
- (d) to defend the country and render national service when called upon to do so;
- (e) to promote harmony and the spirit of common brotherhood amongst all the people of India transcending religious, linguistic and regional or sectional diversities; to renounce practices derogatory to the dignity of women;
- (f) to value and preserve the rich heritage of our composite culture;
- (g) to protect and improve the natural environment including forests, lakes, rivers, wild life and to have compassion for living creatures;
- (h) to develop the scientific temper, humanism and the spirit of inquiry and reform;
- (i) to safeguard public property and to abjure violence;
- (j) to strive towards excellence in all spheres of individual and collective activity so that the nation constantly rises to higher levels of endeavour and achievement;
- <sup>1</sup>(k) to provide opportunities for education to his/her child or, as the case may be, ward between age of 6 and 14 years.

---

1. Subs. by the Constitution (Eighty - Sixth Amendment) Act, 2002



# *Preface*

*R*adiology is an indispensable specialty in the medical field and utilizes various radiological and imaging modalities like X-rays, special contrast investigations ultrasound, computed tomography, magnetic resonance imaging and digital subtraction angiography to reach a definite diagnosis for patient management. With expanding horizons of the medical field and the need of documentation of the patient's medical condition there is an increased requirement of radiological establishments both in the public and private sectors. As the imaging modalities require sophisticated machines to be operated by well trained technologists (radiographers) there is an ever increasing demand of radiographers as well.

This highly specialized field needs a well balanced, optimal performance of the machine, the radiographer and the radiologist to give best results. A radiologist interprets the images acquired by the technologist to make an imaging diagnosis, hence the adequacy of a particular radiological examination and quality of the images are the limiting factors in the clinical performance of the radiologists. This makes the role of the technologist very important and challenging.

This book makes an attempt to introduce the diagnostic of Radiology and Imaging to the students during their career choosing years in a clear and easy manner. It provides a holistic view of the field and also deals with all the facets of Radiology and the radiographer's role all along. Hopefully the content will motivate the students to pursue a graduate course in medical technology to fulfill their aspirations of serving the society through the medical profession.

**Chairman, CBSE**



# Acknowledgements

## Advisors

1. **Sh. Y. S. K. Seshu Kumar**, *Chairman, CBSE.*
2. **Sh. K.K. Choudhury**, *Controller of Examination and Director (V.E.), CBSE.*

## Material Customization Group

1. **Prof. Satish Kumar Bhargava**, *Head, Dept. of Radiology & Imaging, Rama Medical College Hospital & Research Centre, Hapur Road, Hapur (U.P.)*
2. **Dr. Kanchan Varma**, *Senior Consultant & Group Director of Radiology for Kailash Group of Hospitals, Noida (U.P.).*
3. **Dr. Shuchi Bhatt**, *Associate Professor, University College of Medical Sciences & GTB Hospital, Delhi University, Delhi-95*
4. **Dr. Shaili Tomer**, *Associate Professor, Lady Harding Medical College, New Delhi*
5. **Dr. Sumeet Bhargava**, *Consultant Radiologist, Kailash Hospital, Noida (U.P.).*

## Editing & Coordination

1. **Dr. Biswajit Saha**, *Additional Director, (V.E.), CBSE.*



# *Contents*

## **Module-I: Introduction to Radio Diagnosis, Radiation Hazards & Protection**

<b>Chapter 1:</b>	<b>Introduction</b>	<b>2</b>
<b>Chapter 2:</b>	<b>What is Radiation?</b>	<b>4</b>
<b>Chapter 3:</b>	<b>Biological Effect of Radiation</b>	<b>7</b>
<b>Chapter 4:</b>	<b>Radiation Protection</b>	<b>11</b>

## **Module-II: The Hospital, Patients and Radiographer**

<b>Chapter 1:</b>	<b>The Hospital, Patient and Radiographer</b>	<b>18</b>
-------------------	---	-----------

## **Module-III: Dark Room**

<b>Chapter 1:</b>	<b>Dark Room-Construction</b>	<b>28</b>
<b>Chapter 2:</b>	<b>X-ray Films and Cassettes</b>	<b>33</b>
<b>Chapter 3:</b>	<b>Intensifying Screens, Fluoroscopic Screens and IITV</b>	<b>43</b>
<b>Chapter 4:</b>	<b>Latent Image Formation and Processing of the X-ray Films</b>	<b>47</b>
<b>Chapter 5:</b>	<b>Silver Recovery</b>	<b>53</b>
<b>Chapter 6:</b>	<b>Radiographic Faults and Remedy</b>	<b>55</b>

## **Module-IV: Basic and Radiation Physics**

<b>Chapter 1:</b>	<b>Basic Physics and Units of Measurement</b>	<b>58</b>
<b>Chapter 2:</b>	<b>The Structure of an Atom</b>	<b>60</b>
<b>Chapter 3:</b>	<b>Electrostatics</b>	<b>64</b>
<b>Chapter 4:</b>	<b>Magnetism</b>	<b>70</b>
<b>Chapter 5:</b>	<b>Transformer</b>	<b>74</b>



<b>Chapter 6:</b>	<b>X-ray Circuit Rectifier</b>	<b>78</b>
<b>Chapter 7:</b>	<b>X-rays (Roentgen Rays) and X-ray Tubes</b>	<b>84</b>
<b>Chapter 8:</b>	<b>Interaction of X-rays with Matter</b>	<b>94</b>
<b>Chapter 9:</b>	<b>Scattered Radiation and Methods to Reduce it and Grids</b>	<b>110</b>

#### **Module–V: Regional Radiography, Special Procedures and Contrast Media**

<b>Chapter 1:</b>	<b>General principles of Radiography and Positioning and Terminology in Radiography</b>	<b>116</b>
<b>Chapter 2:</b>	<b>Special Radiographic Procedures</b>	<b>177</b>
<b>Chapter 3:</b>	<b>Contrast Media Used in Radiology and Imaging</b>	<b>202</b>

#### **Module–VI: Various Imaging Modalities and Recent Advances**

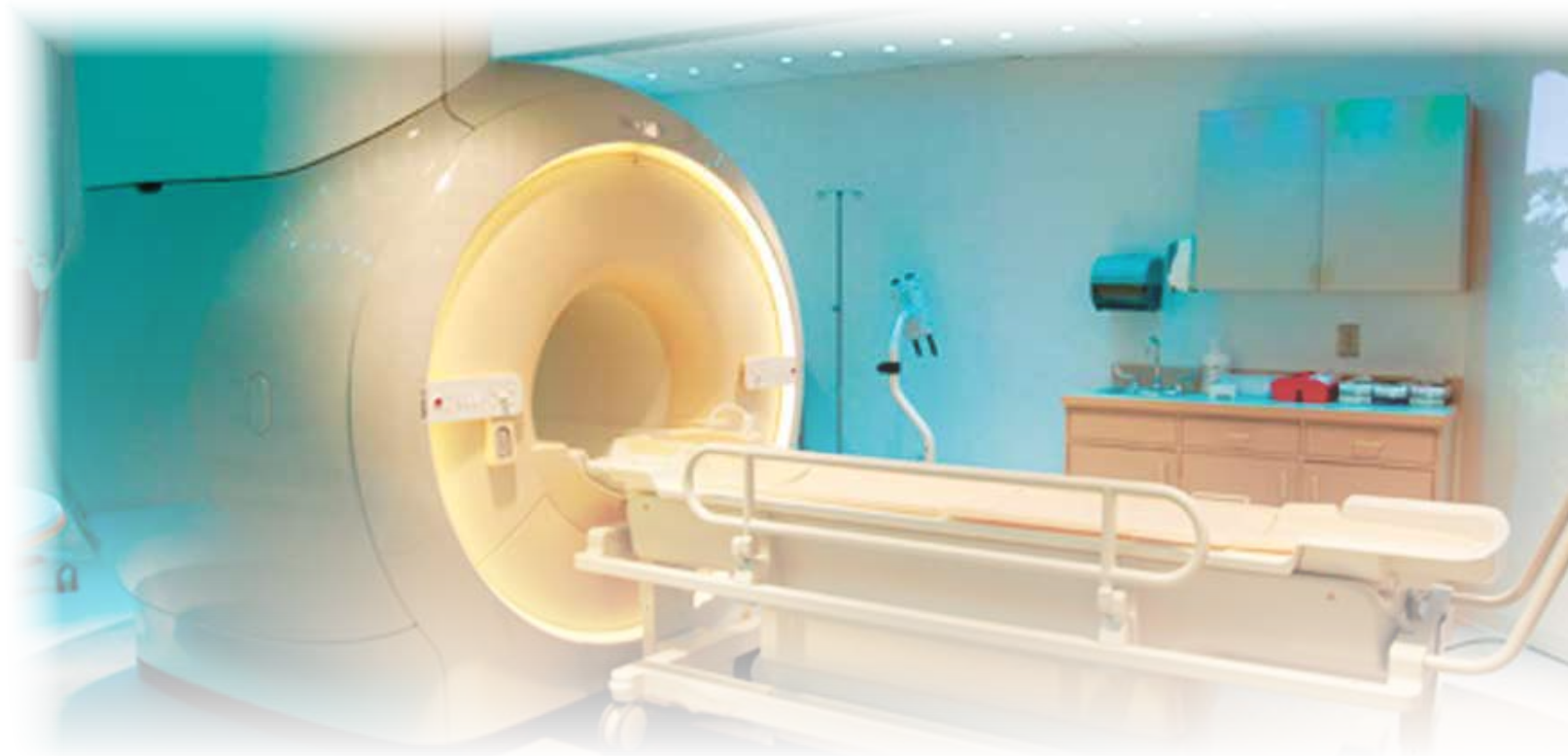<b>Chapter 1:</b>	<b>Ultrasound and Applied Aspect of Sonography</b>	<b>210</b>
<b>Chapter 2:</b>	<b>CT Scan and its Applied Aspect</b>	<b>217</b>
<b>Chapter 3:</b>	<b>MRI and Its Applied Aspect</b>	<b>227</b>
<b>Chapter 4:</b>	<b>Radio Nuclide Scanning</b>	<b>235</b>
<b>Chapter 5:</b>	<b>Recent Advances in Radiology</b>	<b>240</b>





## MODULE - I

# *Introduction to Radio Diagnosis, Radiation Hazards & Protection*





## Chapter-1

# Introduction

To the human observer, the internal structures and functions of the human body are not generally visible. However by various imaging techniques, images can be created through which the medical professionals can look into the body to diagnose abnormal condition and guide therapeutic procedures. The medical imaging is a window to the human body.

**Objectives: After completing the chapter the students will be able to:**

- ➡ What radio diagnosis means ?
- ➡ Who is a radiologist ?
- ➡ Who is a radiographer ?
- ➡ What are the various modalities used in Radiodiagnosis department ?

### What is Radio-Diagnosis

Radio-diagnosis is the branch or specialty of medicine that deals with the study and application of imaging technology to diagnose and treat the disease.

### Who is Radiologist

A radiologist is a medical professional who is specially trained to interpret medical images such as X-rays, USG, CT scan and MRI.

### Who is Radiographer

A Radiologic technologist, medical radiation technologist or radiographers are the health care professionals who perform diagnostic imaging procedures such. X-ray examination. MRI scan, CT scan etc.

For proper and efficient working in the radiology department as a radiographer, one has to be familiar with X-ray machines and other facilities available in department.

Various facilities which are available in a fully developed radiology department are:-

1. X-rays
2. Ultrasonography
3. Computed tomography or CT scan.
4. Nuclear medicine



5. Positron Emission Tomography.

6. Magnetic Resonance Imaging.

Interventional Radiology is the performance of (usually minimally invasive) medical procedures with the guidance of imaging technologies.

### **Review Questions**

Q 1. What is Radiodiagnosis?

Q 2. Who is Radiologist?

Q 3. Who is Radiographer?

Q 4. Enumerate the various modalities used in Radiodiagnosis departments?



## Chapter-2

# What is Radiation

### Introduction

Radiation is a form of energy which can travel from one place to another without any medium. Light and heat are form of radiation.

Human beings are surrounded by continuous radiation, which is both natural and man made. The natural source includes cosmic radiation from space, radiation emitted by radio-active materials present in the soil, building material, milk and body itself. Artificial source of radiation include X-Ray equipment, radio-active medication and nuclear weapons.

*Objectives: After completing the chapter the students will be able to:*

- ➡ What is radiation and its various source
- ➡ Various units used in radiation protection

### Radiation Definition & Properties

Radiation is defined as energy in transit. Radiation comprises of electromagnetic rays i.e. X-Rays, radio waves, radiant heat, visible light or gamma rays and particulate radiation i.e. electrons, protons, neutrons, alpha particles and heavily charged ions

X-Rays and gamma rays are identical except they differ only in the source of origin. X-Rays are produced mechanically by making electrons strike on a target that causes the electrons to give up their energy as X-Rays where as gamma rays are produced by nuclear disintegration of radio-active isotopes.

The Radiation that has property of producing positive and negative ions are called ionizing radiation e.g. X-Ray, alpha, beta and gamma rays.

This chapter discusses the various quantities and unit in radiation protection like radiation exposure, absorbed dose, equivalent dose and effective dose.

### Radiation Exposure

Exposure is a quantity to express the amount of radiation delivered to a point in air.

The conventional unit of radiation exposure is **Roentgen**.

Roentgen is defined as a unit of radiation exposure that will liberate a charge of  $2.58 \times 10^{-4}$  coulombs per kilogram of air

$$\text{Exposure} = \text{charge} / \text{mass of air.}$$



$$1 \text{ R} = 2.58 \times 10^{-4} \text{ coulombs / Kg}^{-1} \text{ of air.}$$

The SI unit (System of International Units) of exposure is coulomb / Kg.

In simple words, A Roentgen is the approximate exposure of body surface for an A-P film of the abdomen for a patient of average thickness. Roentgen is independent of area or field size.

### Absorbed Dose

Is the amount of energy that ionizing radiation delivers per gram of the irradiated material. Its conventional unit is '**Rad**'. One Rad of absorbed dose corresponds to energy absorption of 100 ergs / gm.

SI unit of absorbed dose is Gray (GY)

$$1 \text{ GY} = 100 \text{ rads}$$

$$10 \text{ m GY} = 1 \text{ rad (m = milli).}$$

$$1 \text{ c GY} = 1 \text{ rad (c = centi).}$$

### Equivalent Dose

Same dose of different radiation do not produce the same biological effect in a given tissue. So to make the unit independent on the type of radiation, equivalent dose is used which is derived by multiplying the absorbed dose with the radiation weighing factor (previously called quality factor).

Equivalent dose = Absorbed dose in rad

$$\text{Rem} = \text{Rad} \times W_R$$

$W_R$  = Radiation weighing factor

If absorbed dose is expressed in rads the unit of equivalent dose is rem and if the former is expressed in Gray (GY) then the equivalent dose is expressed in sieverts (Sv).

$$\text{Thus } 1 \text{ Sv} = 100 \text{ Rem}$$

The rem is a unit used only in radiation protection. The dose of radiation protection may also be expressed as milli sieverts (m Sv).

$$1 \text{ m Sv} = 1 / 1000 \text{ Sv}$$

$$1 \text{ m Sv} = 100 \text{ m Rem.}$$

### Effective Dose Equivalent

The sum of the product of the equivalent dose to the organ or tissue ( $H_T$ ) and the weighing factor ( $W_R$ ) for each organ or tissue irradiated is called the effective dose equivalent ( $H_E$ ). The purpose of the effective dose equivalent is to relate exposure to risk.



For example – The  $H_E$  resulting from a chest radiographic examination is 0.06 mSv (6 m rem). An  $H_E$  of 0.06 mSv means that the risk involved from a chest examination is the same as the risk involved in exposing the entire body to an X-Ray exposure of 0.06 mSv.

Notice that  $H_E$  does not measure exposure to the chest.  $H_E$  does assign a risk value resulting from an exposure to the chest.

### Activity:

The activity of a radiation source (radio-isotope) signifies the output of radiation from the source. The activity of a source is defined in terms of disintegration per second as it undergoes.

Unit of activity is Becquerel (Bq)

1 Bq = 1 disintegration per second formerly used unit was curie (ci)

1 ci =  $3.7 \times 10^{10}$  disintegration / sec.

### Review Questions

- Q 1. What is the SI unit of radiation protection?
- Q 2. What is conventional unit of radiation protection?
- Q 3. What is conventional unit and SI unit of absorbed dose?
- Q 4. What is SI unit of equivalent dose and effective dose?
- Q 5. What is the unit of Radiation exposure? Define Roentgen.
- Q 6. What do you understand by Rad, Rem, and sieverts?
- Q 7. Define equivalent dose?
- Q 8. What is the importance of effective dose?





## Chapter-3

## Biological Effect of Radiation

**Introduction**

As we know that X-rays are ionizing radiation, they produce somatic and genetic effect. There can be early effect and late effect depending on the amount of dose and organ exposed. This chapter briefly discusses the various effect that might be produced when X-Rays interacts with the body tissues.

The objective of this lesson is to familiarize you about various effects of X-rays on human beings. This is essential in the protection of staff and general public and also helps in understanding the usefulness of X-rays.

**Objective: After studying the lesson the student will be able to :**

- ➡ Know the various effect of X Rays on human beings
- ➡ Classify types of radiation injury
- ➡ Elaborate the effect of radiation on foetus
- ➡ Enlist various factors affecting radiation hazards
- ➡ Differentiate between acute and chronic and between somatic and genetic effects

**Classification of Radiation Injury**

Radiation effects are classified either as: **acute or chronic**, or as **somatic or genetic Effects**.

These can be directly proportional to dose i.e. **deterministic (certainty)** effects, or not directly proportional to dose i.e. **stochastic effects**.

**Acute responses** to radiation therapy are seen in tissues with rapid turnover (gastrointestinal mucosa, bone marrow, skin, oropharyngeal and esophageal mucosa). Acute radiation damage leads to cell necrosis.

**In chronic radiation** injury atrophy, necrosis, ulceration, metaplasia, dysplasia or neoplasia can occur in epithelial and parenchymal cells. In the stromal tissue, changes that are seen are; fibrosis, necrosis and presence of atypical fibroblasts. Arteries and capillaries show endothelial cell damage, thrombosis, rupture, myo-intimal proliferation and vasculitis. Small veins show intimal proliferation, fibrosis and veno occlusive disease (as in the liver).

**1. Somatic Effects :** Can be of two types:

- a) **Deterministic effects** show the following features:-
  - ◆ Related with certainty to a known dose of radiation



- ◆ Dose threshold exists
- ◆ Severity of the effect is dose related
- ◆ These effects are seen in radiation exposed individuals during his or her lifetime. Radiation can induce nonmalignant changes in skin, epilation (loss of hair) and cataract in the eye and affect functions of various organs.

Deterministic effects are seen after radiation accidents and patients undergoing radio-therapy.

b) **Stochastic Effects** show the following features:-

- ◆ Random events without threshold
- ◆ Probability increases with dose
- ◆ Severity of the effect may not be dose related

2. **Genetic** : These are stochastic by their nature

### Acute Total Body Irradiation

At a dose in excess of 100 Gy to the total body death usually occurs within 24 to 48 hrs from neurological and cardio-vascular failure.

A dose between 5 and 12 Gy death may occur in days as a result of gastro-intestinal syndrome.

At doses between 2 and 8 Gy death may occur several weeks due to effect on bone marrow which result in faulty blood production.

### Chronic Radiation Effect

These effects results from prolonged exposure of lower intensity or may appear as late effects in survivors of more acute exposures. These effects can occur in various systems as central nervous system, skin, heart and blood vessels, lungs, digestive tract, haemopoietic system, eye, bladder and testes and ovaries.

### Somatic Stochastic Effect

These are the late effects which occur at random with no dose threshold. All stochastic effects are late but not all late effects are stochastic. The effect of shortening of the life span and induction of malignancies are considered somatic stochastic effects. Various radiation induced malignancies are leukemia, malignancy of skin, lung, bone, breast, thyroid and meningiomas.

### Genetic Effect of Radiation

Radiation can either damage the DNA or affect the chromosome itself which can lead to mutations which may be manifested in late generations as congenital defects or malignancies.

### Effect of Radiation on Foetus (Unborn Child)

Effect on the foetus may be both deterministic and stochastic. Radiation can cause fetal death, gross malformation, mental retardation and growth retardation.



Fetal malformations may be microcephaly, absence of eyes, and absence of lens, cataract, stunting, cleft palate, club feet, deformed arms, spina bifida and genital deformities.

The foetus is most sensitive in 8-15 weeks of gestation and examination involving radiation to the foetus should not be done during this period.

### Factors Affecting Radiation Hazards

The hazard depends upon the nature and type of radiation and the source by which the radiation is being received, whether externally or internally. It also depends upon total dose and dose rate, and the extent and part of body exposed, age and sex of individual and radiation sensitivity of the organs exposed.

The external hazards are caused due to radiation received from the sources which are located outside the body like x-ray, gamma therapy and brachy therapy sources. The body can be exposed by keeping any source on the body or away from the body. Internal hazards are due to those isotopes which get located into the body by inhalation or through mouth or nose or by ingestion through the wounds.

The net injury depends upon the energy imparted per unit weight or volume of body tissue. Thus greater the energy absorbed per unit volume, greater will be the damage to the body.

**Table: Biological Effects Due to Acute Exposure to Only One Part of Organ**

Region	Dose	Effect
Skin	3 Sv to 20 Sv	Epilation and erythema, ulceration and necrosis (over period of days)
Eye	5 Sv to 8 Sv	Cataract (within 5-10 yrs)
Ovary	1 Sv to 4 Sv	Temporary to permanent sterility
Testis	0.25 Sv to 4 Sv	Temporary to permanent sterility

### Factors Affecting Radiation Hazards

Dose	Immediate Effect
0.1 Sv (10 Rem)	None detectable
0.1 Sv (0.25 Rem)	Chromosome aberrations
(10 rem to 25 rem)	Detectable
0.25 Sv to 1.0 Sv	Change in blood picture, decrease in blood count
(25 Rem – 100 Rem)	Non lethal 100% recovery.
1.0 Sv to 3.0 Sv (100 Rem – 300 Rem)	Nausea, vomiting, Diarrhoea etc. Death is possible in some cases.
3.0 Sv to 5 Sv	Severe radiation sickness (loss of weight and appetite etc) Death may occur in case of 50% exposed persons death may occur in 50% case, if exposed
Above 5 Sv (500 Rem)	All above effects and death within few days



### Review Questions

- Q 1. What is acute radiation exposure?
- Q 2. What is chronic radiation exposure?
- Q 3. What is somatic effect?
- Q 4. What is stochastic effect?
- Q 5. What are biological effect of radiation?
- Q 6. What do you understand by maximum permissible dose for occupationally and occasionally exposed person?
- Q 7. What are the radiation induced cancers?
- Q 8. What are the harmful effect of radiation on foetus?
- Q 9. What are stochastic and non-stochastic effect of radiation?



## Chapter-4

# Radiation Protection

### Introduction

In earlier chapter we have studied the biological effect of radiation. Now in this chapter we shall learn protection for staff and general public from X-ray which is an essential part of knowledge. Further with dose optimization the dose to the patients can be reduced without compromising on the quality of images.

This chapter also discusses various ways through which efficient radiation technologist can reduce the dose to the patient and also, protect him and general public from harmful effect of radiation.

**Objectives:** After studying the lesson the student will be able to:

- ➔ Know how to reduce the dose to the patients
- ➔ Use protective devices to minimize the harmful effects of radiation
- ➔ Know how to detect radiation exposures
- ➔ Enumerate the duties of radiation safety officer (RSO)

### Regulatory Bodies

The regulatory bodies lay down norms for protection against radiation and also recommend the dose limits for radiation workers and the general public. The **ICRP** or the International Commission for radiation protection is the international regulatory body. Each country has its national counterpart of the ICRP. In America the counterpart is the **NCRP** or the National Commission for Radiological Protection and in India it is the **AERB** or the Atomic Energy Regulatory Board.

**ALARA** and **ORP** are concepts of the ICRP and the NCRP. ORP stands for optimization of radiation protection. ALARA stands for “As low as reasonably achievable”. ALARA recognizes that there will always be some radiation exposure to patients involved in radiological procedures using ionizing radiation, but it also recognizes that these exposures can be minimized.

Regulatory bodies have divided individuals into four classes who are exposed to radiation.

1. **Occupationally Exposed:** They are working in radiation environment. They are expected to accept some amount of higher radiation as a professional hazard.

Limits for exposure (MPD-maximum permissible dose) for occupationally exposed individuals is 2 rem / year = 20 m Sv / year.



2. **Occasionally Exposed:** They occasionally visit an X-ray department or visit some other scientific site where radiation / radioactive source are present.

The dose limit for occasionally exposed is 0.2 rem / year = 2 mSv / year.

3. **Trainee Under 18 Year of Age:** There are individuals beginning training in industrial or medical use of radiation under 18 years.

NCRP recommended limits of exposure of trainee 0.1 rem = 1 mSv / year.

4. **Fetus Exposure:** NCRP recommends a total dose equivalent limit (excluding medical exposure) of 0.05 rem (0.5 mSv)/month for the embryo/ fetus. Exposure of the embryo/ foetus should not be greater than 0.05 rem (0.5 mSv) in any month.

In actual practice, radiation level should be kept at the lowest practicable level, and we should not think of permissible dose as being perfectly safe. We should remember that **ALL IONIZING RADIATION IS HARMFUL**

**Radiation Protection:** Harmful effect of radiation can be minimized by

- a) Reducing the exposure.
- b) By using the protective devices.

#### A. Methods of Reducing Exposure

Exposure can be reduced by:

1. By increasing distance between source and area under consideration.
2. By reducing the duration of exposure.

##### 1. Distance

The intensity of radiation varies inversely as the square of distance.

$$I \propto \frac{1}{D^2}$$

I = intensity of radiation and D = distance

Therefore, increasing the distance from the source of radiation reduces the exposure to the individual concerned. So a radiographer and technician should stand as far as possible from any mobile machine (which does not have a protective barrier), by using a long exposure cord. Minimum distance between tube of machine and radiographer should be 2 meters.

##### 2. Time

**Radiation dose = Exposure Rate X Duration of Exposure**

Radiation dose can be minimized by reducing the duration of exposure. Therefore, machines using shortest exposure time and having high tube rating are to be preferred.





## **B. Methods of Protection**

The following methods should be adopted to provide protection against harmful effects of radiation.

The protection is achieved by

1. Shielding
2. Satisfactory work practices

### **1. Shielding**

Shielding implies that certain material (concrete, lead) will reduce the intensity of X-ray when they are placed between the source of radiation and the exposed individual. So if protective shield of proper thickness is used, radiation exposure can be reduced. There are four aspect of shielding in diagnostic radiology.

#### **I. X-Ray Tube Shielding**

The X-ray tube housing is lined by thin sheet of lead which prevent the leakage of radiation.

#### **II. Room Shielding**

The walls of the radiology department are lined by lead or made up of thick brick( 9 inches of concrete) to protect the individual located outside the X-ray room from unwanted radiation. These are called protective barriers.

#### **III. Personal Shielding**

Shielding apparel should be used by occupational workers which comprise of lead aprons, eye glasses with side shields, hand gloves and thyroid shield.

This apparel protects an individual only from secondary radiation and not from the primary beam. The thickness of the apron should be at least 0.25 mm lead equivalents. The minimum protective lead equivalents in hand gloves and thyroid shields should be 0.5 mm.



**Lead Gloves**



**Lead Aprons**

## Care of Lead Apparel

It is important that aprons are not abused, such as by dropping them on the floor, piling them in a heap or improperly draping them over the back of a chair. Because all of these actions can cause internal fracturing of the lead, and may compromise the apron's protective ability. When not in use, all protective apparel should be hung on properly designed racks. Protective apparel also should be radiographed for defects such as internal cracks and tears at least once a year.

### 2. Satisfactory Work Practice

Step should be taken to prevent the unnecessary exposure to any one whether the radiation worker, patient or public.


To avoid unnecessary exposure one should be ensured that the red light warning signal is made 'on' outside the room before giving the exposure:

None else except the person undergoing examination should be allowed in the room and two machines should not be installed in the same room. The collimator devices should be used to limit the beam. Palpation by bare or even by gloved hand should never be done during fluoroscopy. A palpation spoon should be used.

To reduce the radiation dose to the patients the number of radiographs during a particular examination must be reduced. The frequency of such examination can be minimized by facilitating the free movements of radiographs from one hospital to another.

## Detection of Radiation Exposure

Despite the precautions to reduce radiation exposure, some amount of radiation exposure is bound to occur to the persons working in the radiology department. Therefore devices to measure the radiation exposure are necessary, so that whether the dose limits have been exceeded or not, can be known. These devices are: Pocket Dosimeter, Film badge and Thermoluminescent dosimetry (TLD) badge.



TLD Dosimeter Badge



During radiography (when no protective lead apron is worn), the personnel dosimeter is worn at one of two regions :

1. On the trunk of the body at the level of the waist, on the anterior side of the individual,
2. On the upper chest region at the level of the collar area on the anterior surface of the individual.

During fluoroscopy a protective apron should always be worn. It is further recommended that ideally two dosimeters should be worn by radiation personnel.

One at the collar level outside the lead apron and the other at the trunk level underneath the lead apron.

### Radiation Protection Survey Programme

The responsibility for establishing a radiation protection programme rests with the hospital administration / owners of the x-ray facility. The administration is expected to appoint a **Radiation Safety Committee (RSC)** and **Radiation Safety Officer (RSO)**.

It is the duty of RSO is to perform a regular **radiation protection survey**.

**AERB** has recommended regular medical examination of radiation worker to assess their protection status.

Every radiation worker prior to commencing radiation work and at subsequent intervals not exceeding 12 months shall be subjected to the following medical examinations:

- ◆ X-ray examination of Chest
- ◆ All general laboratory investigations such as examination of blood and excreta.
- ◆ Special investigations such as examination of skin, hands, fingers, nails and eye.

### Review Questions

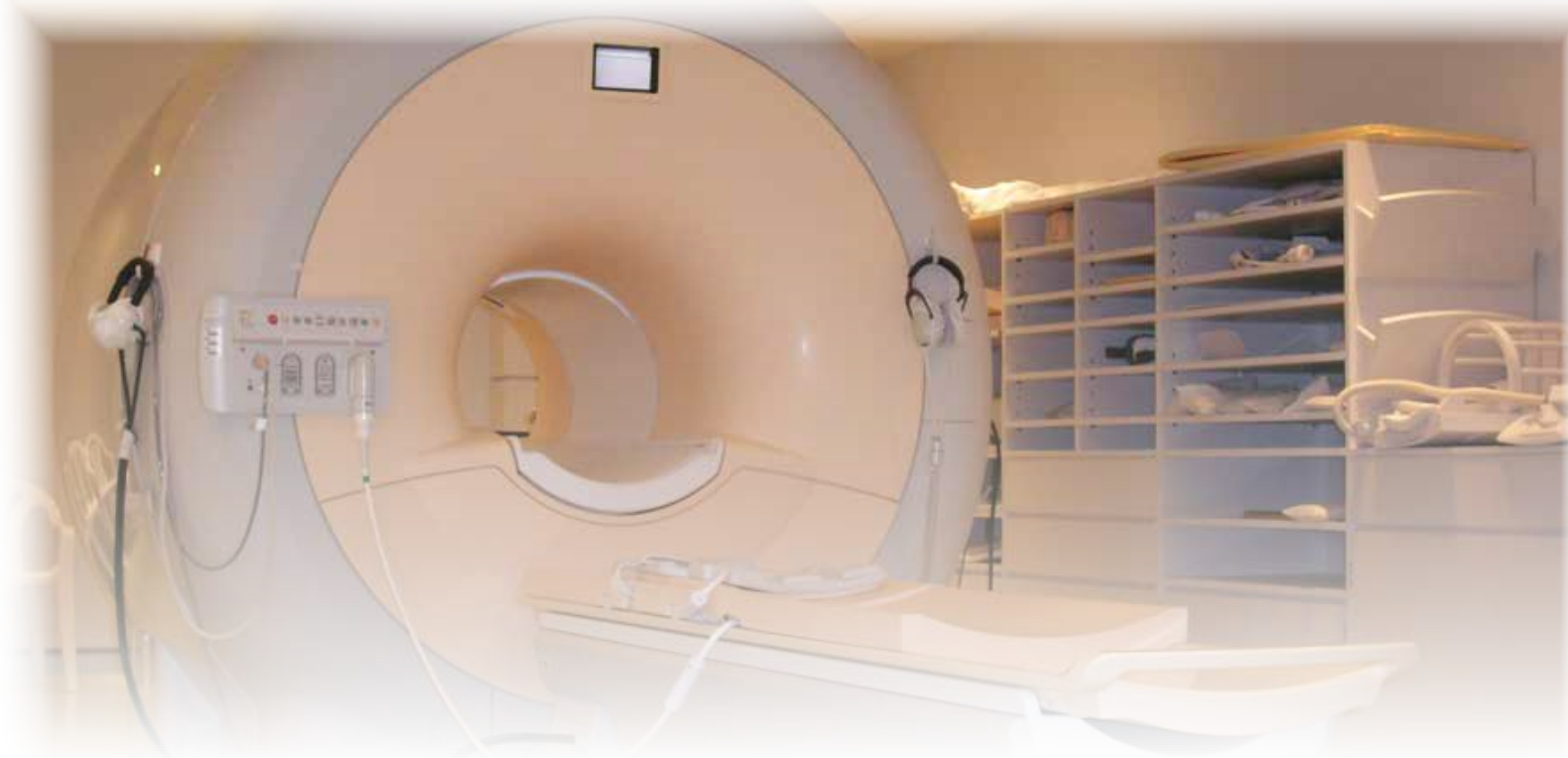- Q 1. What is ALARA?
- Q 2. What is ORP?
- Q 3. What are the methods to reduce the exposure of radiation?
- Q 4. What are the various methods of protection?
- Q 5. What should be the minimum thickness of lead apron?
- Q 6. Name the regulatory authority for radiation protection in India?
- Q 7. What are the good work practices to reduce radiation exposures?
- Q 8. What are the precautions to be used for care of the lead apparel in radiology department?
- Q 9. What are the device for measurement of radiation exposure to occupationally exposed person?
- Q 10. What are the duties of RSO?





## MODULE - II

# *The Hospital, Patients and Radiographer*







## Chapter-1

# The Hospital, Patient and Radiographer

### Introduction

This chapter highlights the important function of a radiographer who has the responsibility to carry out proper X-rays of the patient. A radiographer has the primary role and therefore clinical, ethical and legal responsibility must be known to him. It is also essential for the radiographer to carry out X-rays of the patient who are critically ill and vulnerable with minimum discomfort to them.

Patients requiring special investigations should be explained and properly prepared for investigation by radiographers.

### *Objectives – After studying the chapter the students will be able to :*

- Discuss how patient will reach X-Ray department & maintenance of hygiene in department
- Familiarize with clinical, ethical and legal responsibility of radiographer
- Apply appropriate procedure in event of accident
- Identify and use of various medicines used for radiographic procedure
- Maintain the records
- Follow the rules of radiation safety

### Clinical Responsibility

Some knowledge of diseases, practical procedures and elementary patient care is required by the radiographer. A radiographer has an important role in providing the right kind of environment to the patient. Important things are:

- ◆ Sympathetic attitude towards the patient.
- ◆ Respect for patients as human beings.
- ◆ Avoid aversion to unpleasant sights or smells with the patient.
- ◆ Cheerful and enthusiastic attitudes.
- ◆ Neat and clean appearance. Female radiographers should avoid long nails and jewellery.
- ◆ Avoid discussion with the patient about the disease. Instead for any queries, patient should be directed to the doctor or radiologist.





### Ethical Responsibility

- ◆ These are two special elements in this code of conduct. The first is discretion in speech and absolute necessity not to reveal information about patient which is confidential. The second is the inescapable duty of radiographer to give minimum radiation dose to patients.

### Legal Responsibility

- ◆ Disclosing or discussing any information about the patient with any person except with the referring clinician means the radiographer constitutes breach of professional confidence.

### Procedure in the Event of an Accident

The procedure to be adopted in such cases fall into three categories.

- |                           |   |
|---------------------------|---|
| 1. Care of victim         | Most important  |
| 2. Reporting the incident | Important from legal point of view  |
| 3. Recording the incident | May also highlight any aspect of departmental working which makes accident more likely. |

### Radiographer and the Hospital

- ◆ Radiographer is an integral part of hospital care staff. The whole staff is oriented towards one aim i.e. patient care. The cooperation with other staff of the hospital is essential to reduce patient discomfort.

### General Preliminaries to Examination

Patient reaches X-ray department in three ways:

1. On wheel chair
2. On stretcher
3. In the bed

### Patient on Wheel Chair

- ◆ If patient is able to stand, wheel chair is brought to foot end of the table. Radiographers foot acts as a break against the hind wheel where patient is supported with arm in axilla. Care should be taken that patient does not stand on foot rest.
- ◆ If patient cannot stand two methods can be used.

### Australian Lift

Wheel chair is placed sideways facing the foot end. Radiographers stand on either side of the patient with one arm in axilla and hands clasped at the back. The other arm is under the thigh.

This method is not useful for painful shoulder or thorax.



### Orthodox Method

- ◆ Patient's arms are folded across the chest. Arms of radiographer are not in axilla. Rest of the procedure is same. This is done for painful shoulder.

### Patient on Stretcher

- ◆ If patient can help himself stretcher is brought adjacent to the X-ray table and patient transports himself, provided stretcher is at the same heights as table. If patient can't help himself, three radiographers with arms under shoulder and chest, trunks and legs respectively, help in lifting the patient. Weight of the patient should be born on upper arm and chest of radiographer and not on forearm. Enquiries should be made regarding any particular tender part of the patient.

### Anaesthetised Patients

With the increasing intervention for radiology in anaesthetised patients, some important elements of care are:

- ◆ Check patient's identity.
- ◆ Check patient preparation.
- ◆ Don't leave any unconscious patient alone. Take care that any part of unconscious patient is not under undue strain. If patient is restless, don't struggle.
- ◆ Assist the anesthetist, if required.
- ◆ General and vital element care of patient.

### Hygiene in X-Ray Department

Important steps are:

- ◆ Hand washing between handling individual patient
- ◆ Patient's hygiene must be maintained by giving him clean gown to wear and providing clean utensils, bed pans, urinals, drinking mugs etc.
- ◆ Use of disposable paper towels
- ◆ Cleaning the X-ray table top and erect bucky stand with antiseptics and tissue paper.
- ◆ Radiolucent mattresses to be washed, cleaned and kept in polythene sheeting.

### Patient Preparation

General abdominal preparation is required for plain X-ray abdomen, X-ray dorsolumbar spine, urography etc. To avoid confusing shadows due to faeces and gas. The preparation requires:

1. Use of purgative



2. Use of enema
3. Prevention of intestinal gas

### 1. Use of Purgatives

**A. Irritant Purgative** – like Bisacodyl (Dulcolax) which produces peristalsis on contact with mucous membrane of bowel, it has irritant effect on sensory nerve endings in mucosa. Two tablets are taken at bed time.

Senna and cascara are vegetable irritant purgatives.

Castor oil is another purgative which prevents normal absorption of fluids thus increasing the contents and producing peristalsis.

Contraindications to its use are inflammation of appendix with possible abscess formation or obstruction of bowel.

### B. Lubricant Purgatives

◆ Liquid paraffin softens the stools in doses of 15-30 ml. But it must not be given to patients on anticoagulants for vascular diseases.

◆ Dicotyl sodium sulphosuccinate also softens the faeces.

**C. Bulk Purgatives** – Increase the volume for intestinal contents either by absorbing water as in isogel or by osmosis like in magnesium sulphate.

### 2. Use of Enema

◆ Used mainly for colon. Soapwater, glycerine, olive oil and mixed phosphates can be used in enema. Use of enema is contraindicated in

1. Colostomy
2. Prolonged diarrhoea
3. Hirschprung's disease

◆ There are some patients who should not be prepared prior to barium examination as patient of ulcerative colitis, megacolon or acute intussusception.

### 3. Absorption of Intestinal Gas

Intestinal gas is more problematic than faecal residue. The factors responsible are diet consisting of starchy foods, vegetables and beans, effervescent drinks and confinement to bed.

#### To reduce gas

- ◆ Use flatus tube
- ◆ Charcoal tablets or biscuits at bed time.



From the evening before the examination any meal should be limited to fluids, clear soups, black coffee or tea with sugar if desired, but not with milk or cream. No fruit drinks are to be taken.

### **Preparation of a Diabetic Patient**

A patient not taking insulin may postpone a meal for a short period. He should be told to skip breakfast and placed first in morning and a suitable meal should be ensured before leaving the department.

For patients on insulin, morning dose of insulin and the breakfast have to be skipped and patient should take both before leaving the department.

### **Preparation of an Infant**

A customary meal may be given at 6 am but not again before the completion of examination. For barium studies, replace the child's ten O'clock feed with a normally prepared barium drink administered by feeding bottle.

### **Working With a Mobile X-Ray Set**

Explanation to the patient and proper care of the equipment are essential components of using a mobile X-ray unit as accidents are more common with it than with fixed installation.

### **Patient having Oxygen Therapy**

Oxygen supply should be cut off while the X-ray set is operating to avoid risk of fire or sparking however care should be taken to cut off oxygen for as short as possible.

### **Patient having Intravenous Infusion**

Care to be taken to prevent dislodgement of needles and kinking of the tube. Any dislodgement of needle or obstruction to flow of fluid should be immediately reported to ward staff.

### **Patient with Tracheostomy Tube**

It is important to know that patient can be temporarily speechless for 24-28 hrs after tracheostomy. It is also important to check that outer end of the tube is not unduly extruded, or the tube has not come out or there are no loose tapes. Signs of respiratory obstruction or cyanosis should be watched, which include bluish colouration, increased and later irregular pulse, increased respiratory effort possibly with widening of nostrils, reversed or see-saw inspiration (chest moves inward during respiration instead of the out ward movement), restlessness, loss of consciousness or deepening of unconscious state.



### Patient on Traction

Presence of blocks under the bed and any overhead work should be noted so that any accident does not occur. The bulldog cups attaching slings to splints should be replaced by safety pins to prevent abnormal radiological shadows.

### Operation Theatre

**Asepsis** – mobile X-ray equipment is a potential source of infection and it is impossible to completely sterilize it. Therefore a mobile unit permanently within the theatre is helpful. The tube head and image intensifier should be enclosed in sterile linen.

Radiographer must wear a clean gown, face mask and cap and take care not to touch anything sterile. Undue movement in theatre should be limited.

**Explosion risk** – Inflammable anesthetic gases may explode. With the use of electrical equipments even static electricity may produce sparks. Various antistatic measures are available but X-ray equipment cannot be made spark proof and therefore inflammable gases are best avoided.

### Radiation Safety

- ◆ Work with mobile equipment is likely to result in increased radiation dose to the staff as:
- ◆ Patient requires support during radiographic exposure
- ◆ Radiographer has to stand very close to the source of exposure
- ◆ There are difficulties in limiting the beam strictly.

If necessary, bed should be moved away and staff should be warned to keep clear while the exposure is made. Radiographer should wear a lead apron if close to the patient and X-ray tube. Any supporting of patient should be done by nurse or other non radiographic staff and a lead apron should be worn.

### Infectious Patient

Such patients should preferably be imaged at bed side only with portable equipment. If at all they have to come to the department, direct contact with other patients, as well as X-ray equipment and cassettes should be avoided, using clean bed sheets and pillows and disposable covering for cassettes and equipment. Hands should be washed before handling the next patient.

### Examination during Pregnancy

General guidelines are

- ◆ No X-ray examination for abdomen, lumbar spine or pelvis unless emergent.
- ◆ Avoid repeated examination.
- ◆ For dental and chest radiographs shield the abdomen.



### Ten Day Rule

All non-urgent abdominal and pelvic X-ray examinations should be done within 10 days of last menstrual period to avoid any possible risk of X-ray exposure during pregnancy.

### Effect of Radiation in Pregnancy

Ionizing radiation causes chromosomal damage which is the cause of foetal malformation in exposed women.

During the first month the risk is failure of implantation of fertilized ovum. During second month there may be malformation of specific organs. During third and fourth months there may be mental retardation due to defective development of forebrain.

### Radiography of Children

Two important principles while doing X-rays of children (less than 12 years) are:

- ◆ Minimize the X-ray dose and avoid repeated exposures because children are more likely to have manifestation due to longer life.
- ◆ Avoid motion unsharpness by
  - Selection of a short exposure interval,
  - Using accessory equipment to restrict patient physically and avoiding forceful handling of children.

### Gonadal Dose

When the pelvis is directly irradiated, the gonad dose received by female is greater than the male. When the radiation is scattered, gonad dose in male is higher.

### Measures to Reduce Radiation Dose

- ◆ Fast imaging systems
- ◆ Gonad shields or other similar protective device
- ◆ Proper limitation of area by X-ray beam.
- ◆ Appropriate choice of projections. i.e. eyes receive a smaller dose in occipito-frontal projection than in fornto-occipital projection.

### Lead Aprons

Use of lead line aprons and gloves is mandatory for department personnel and patients relatives standing close to patient during exposure.





To act as effective barrier, the aprons should have minimum lead equivalent of 0.25 mm for X-ray generated at voltages upto 150 KV.

### **Use Gonadal Shields**

It is easier to use gonadal shield in males than females, while taking abdominal radiography. There are a number of devices mostly in the form of a lead strip mounted on a T shaped or at triangular Perspex base, which is placed on the patient in appropriate position over the thigh or lower abdomen. A mask placed at the X-ray beam's exit port from tube head in conjunction with light beam collimator also serves a similar purpose.

### **Apron Protection for Patient**

- ◆ An apron which can be worn by a patient seated in a chair for dental radiography and provides cover to front of the body from the neck to knee.
- ◆ A waist apron which can be secured round the patient or suspended from adjacent supports in order to cover the lower back and abdomen during chest radiography.

### **Limitation of Irradiated Area**

A beam collimator or diaphragm provides visual evidence of the field size covered by beam and helps in limiting the beam.

A cassette sensor can be used with some X ray tubes bucky combinations, so that when a cassette is placed in a bucky tray, automatic collimation of beam occurs and helps in reducing the dose.

### **Protection during Fluoroscopy /Image Intensifier**

In fluoroscopy a timing switch which indicates the period during which the patient is actually subjected to fluoroscopy is helpful.

A limiting device which prevents opening of fluoroscopic diaphragms to field size beyond the margins of image receptor can be used.

When test exposures are made the shutters should be fully closed and tube should be directed away from the patient.

### **Importance of Maintenance of Records**

The importance of proper record keeping is also important, both for patients as well as department or hospital. The diagnostic radiograph itself is a record.

Maintenance of record is important for assessment of

- ◆ Planning of services



- ◆ Academic work
- ◆ Maintenance and renewal of equipments
- ◆ Supplies of films, chemicals and drugs
- ◆ Financial requirements
- ◆ Movements of staff
- ◆ Holiday dates
- ◆ Museum
- ◆ Personal monitoring for radiation protection

Radiographer is in unique position to help in record maintenance by virtue of familiarity with the procedures undertaken in department.

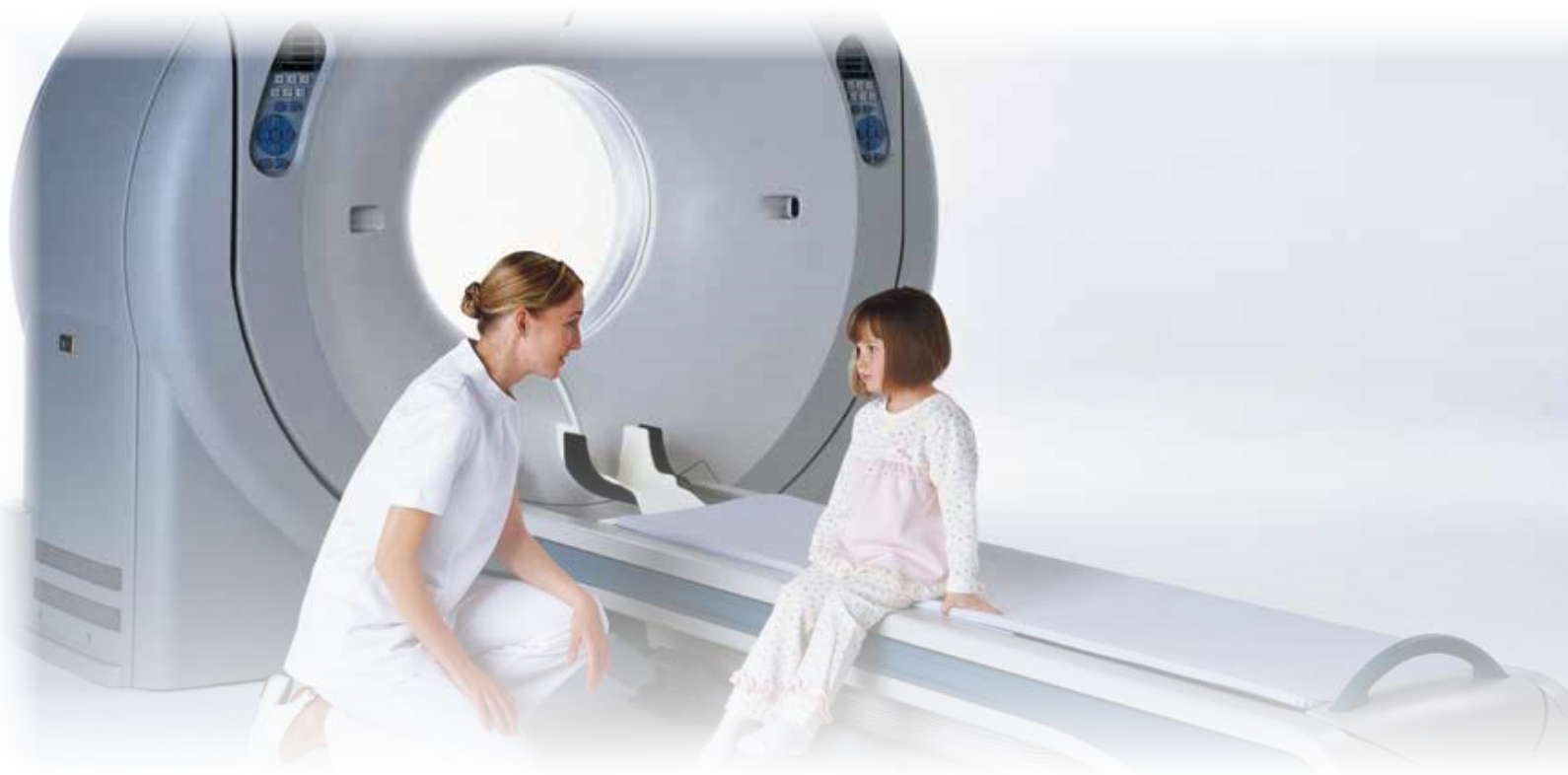### Review Questions

- Q 1. Write three clinical responsibility of the radiographer.
- Q 2. Write name of any purgative used in x- ray department for patient preparation.
- Q 3. What are the responsibilities of a radiographer?
- Q 4. How a patient on wheel chair is shifted to X ray table for X ray examination?
- Q 5. What precautions should be taken during X ray examination of a anesthetised patients, child, and patient with tracheostomy?
- Q 6. What precaution should be taken during X Ray examination of a pregnant lady?
- Q 7. What is the importance of maintaining records?
- Q 8. How is bowel preparation done?
- Q 9. Describe measures to reduce radiation exposure.



## MODULE - III

### *Dark Room*





## Chapter-1

# Dark Room – Construction

### Introduction

Dark room has very important place in radiology. It is basically a processing room where unexposed films are loaded in the film cassette and films are processed here after exposure. Its role in providing good quality radiographs should not be underestimated. Proper understanding of darkroom procedures is very necessary. In this lesson you will learn about dark room and its components, processing methods and faults in radiography and their remedy.

**Objectives – After reading this lesson you will be able to:**

- ➡ Discuss about the dark room & its various components
- ➡ Describe processing methods

### Darkroom

Darkroom construction, dry and wet sides, defects of x-ray film, film quality, intensifying screens, cassette, processing of film, faults in radiographs and remedy with some idea of silver recovery from used fixer and discarded films.

Darkroom is also called as 'Processing room'. It is the place where loading of unexposed films and processing of exposed films is done. Darkroom in real terms is not completely dark, safe illumination is provided to facilitate working. Darkroom plays a very important role in maintaining radiographic quality.

### Location

It should be located adjacent to radiography room to save time. If more than one radiographic room is in use it should be in central location. It should not be located in hot or damp basement.

### Size

The size of dark room should be large enough to accommodate all the necessary equipment without overcrowding. Ideally 100 ft. floor space and 11 ft ceiling height is needed.

### Building Essentials

#### A. Radiation Protection

The walls of darkroom should have proper lead equivalent so that radiation from adjacent



radiographic room could not produce fogging of films. The lead equivalent of 1.5 mm thickness of lead is sufficient to work up to 100KV.

### B. Floor

The floor of darkroom should be protected from corrosive substance, stainfree, non slippery and easily cleanable. Natural clay or ceramic tiles are the most satisfactory. Ordinary linoleum and concrete should not be used.

### C. Wall Covering

The colour of walls do not have to be dark. It should reflect maximum safe light. The walls should be covered with chemical resistant materials such as special paint, varnish, concrete or ceramic tiles.

### Ventilation

Air conditioning is ideal, but an electric fan is used, the air should be blown into the room rather than out, in order to create a slightly positive air pressure so preventing dust being drawn in through the cracks of doors and other opening.

### Electric Wiring

It is essential to earth all exposed non-current carrying metallic objects to prevent electric shock.

### Pass Book

It has two light tight and x-ray proof doors that are so interlocked that both cannot be opened at the same time. It is divided into two compartments, one for exposed and other for unexposed films.

### Entrance

The simplest type of entrance is a single door which must be made light tight and should have an inside lock to prevent opening while films are being processed.

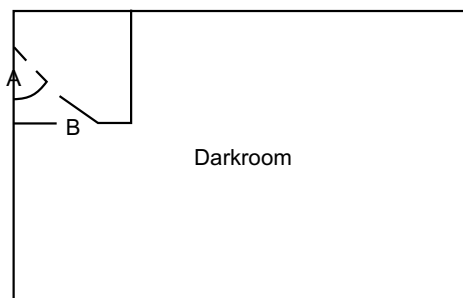


Fig. 4.1.1

Another type of entrance is a small hall with two electrically interlocked doors (Fig 4.1.1), so designed that one door cannot be opened until the other is completely closed thereby preventing entrance of light.

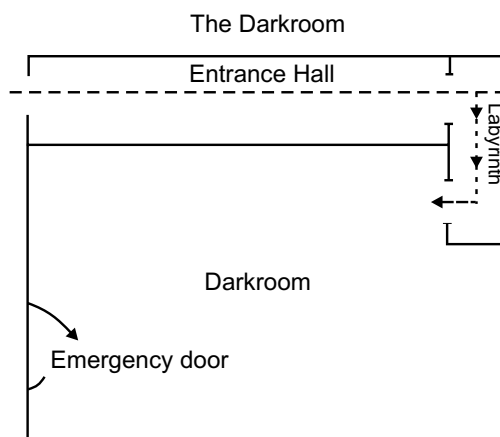


Fig. 4.1.2

More elaborate type of entrance is maze (Fig 4.1.2). It has no doors, serves as light trap. Because of high cost of the required floor area, mazes are rarely used today.

## Illumination

Generally 3 types of illumination is provided:

### 1. Safelight

It should provide a source of light which does not fog films and still provide adequate illumination for loading, unloading and processing of films. Safe light lamps with filters of proper colour such as written series, 6B filter for ordinary X-ray film are available. Working distance of at least three feet from safe light and use of bulb with the wattage indicated on the lamp housing (usually less than 15 watts) should be used. If bulb of higher wattage is used it may produce fog. Periodic checking of safe light is essential.

### Testing of Safe Light

Subject a film in a cassette to a very small x-ray exposure, just enough to cause slight greying. Screen film is more sensitive to fogging by light after initial exposure to the fluorescence or intensifying screen. Then remove the film from cassette in dark room, Cover one half the film with black paper & leave it exposed under conditions simulating as closely as possible those normally existing when a film is being loaded & unloaded. Process the film as usual if the uncovered portion appears darker than covered, you may conclude that darkroom lighting is unsafe.

### 2. General Illumination

For general purposes like cleaning and changing of solutions an overhead light is provided.

### 3. Radiographic illumination

A viewing box should be mounted over the working compartment for viewing wet radiographs.





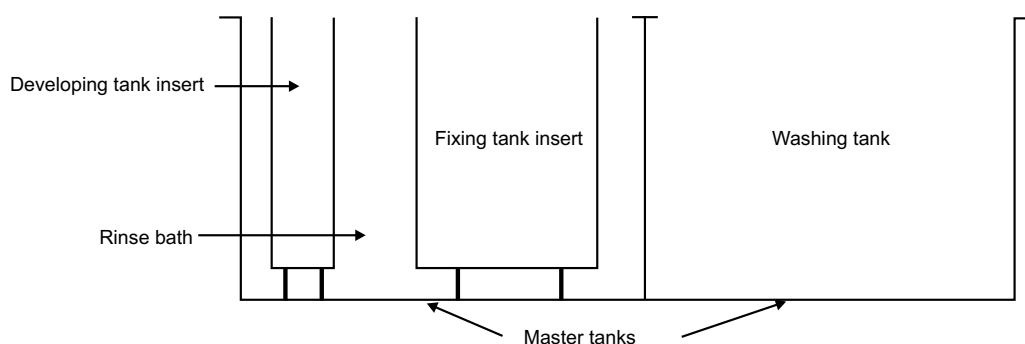
### The Dry Side

It consists of loading bench, compartments for cassettes, film bin, storage for reserve film, brackets for film hangers and waste paper receptacle.

### The Wet Side

Consists of processing tanks and solutions. The simplest type of processing tanks consists of 3 compartment tank, one end of compartment being used for developing and opposite end for fixing. The middle compartment serves both to rinse and wash the films and should be supplied with running water.

A more satisfactory arrangement is that shown in fig. 4.1.3 consists of a larger, insulated, stainless steel, double compartment master tank. Two stainless steel insert tanks are placed in one of the compartments, the insert being the developing tank and the other, the fixing tank. Water between the inserts in this compartment serves both to rinse the films and to control the temperature of solutions. A fixing tank should have about twice the volume of a developing tank since the time required for fixing films is approximately twice that for development. The other main compartment serves as the washing tank and should be about twice the size of the fixing tank, since washing requires about twice as long as fixation.



**Fig. 4.1.3: A Popular Type of Processing Tank Arrangement**

Thermostatic temperature control is necessary for optimal results. Stainless steel is used for construction of tanks helps in rapid equalization of temperature and is corrosive free.

Drying devices to dry the processed films essentially consists of a rack to hold the films and a fan to circulate air around them. A source of heat is usually included to hasten the drying. Such dryers are commercially available as enamel or stainless steel cabinets. To minimize heat and humidity in the darkroom, drying should be done outside.

### What have You Learnt

In this lesson you have learnt about

Darkroom, its location, size, building essentials, ventilation, electric wiring, pass box, entrance, illumination and its types, dry side and the wet side.



### Review Questions

- Q 1. What should be minimum floor area of a Dark room?
- Q 2. What lead equivalent thickness of lead is used for the wall of darkroom?
- Q 3. What is maximum power of bulb used in Dark room for safelight?
- Q 4. What material used in processing tank?
- Q 5. What is the best ideal location for the darkroom? How should the wall be shielded?
- Q 6. Discuss the various kinds of darkroom entrances with their advantages and disadvantages?
- Q 7. What are pass boxes?
- Q 8. Describe a darkroom safe light lamp. How safety of safe light lamp is tested?



## Chapter-2

# X-Ray Films

### Introduction

X-ray film is a film of a photographically active, or radiation sensitive emulsion that is usually coated on both sides of a transparent sheet of plastic called base. Firm attachment between the emulsion layer and the film base is achieved by use of a thin layer of adhesive (substratum layer). The delicate emulsion is protected from mechanical damage by layers known as the super coating or topcoat layer. In the previous lesson you have learnt about dark room, its components and processing methods, in this lesson you will learn about x-ray films, its characteristics, types of films, package and storage of films.

**Objectives – After reading this lesson you will be able to:**

- ➔ Describe the structure of x-ray films & its characteristics
- ➔ Explain various parameters affecting quality of x-ray films
- ➔ List of various types of films used in radiology
- ➔ Explain packing of films and storage of unexposed films

### X-Ray Film

Aim of this chapter is to provide structure of X-ray films, characteristics of X-ray film, parameters affecting quality of X-ray film and various types of films used in radiology.

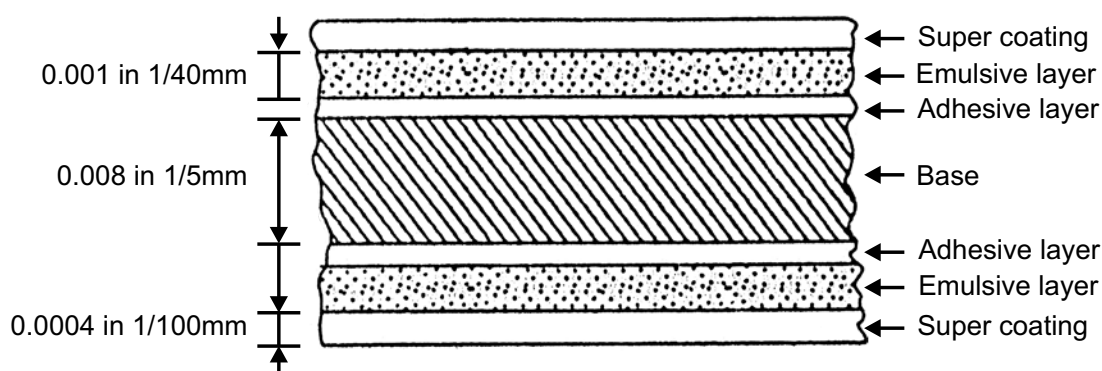


Fig. 4.2.1: Cross Section of A Double Coated Film



## The Base

The base is usually made of cellulose triacetate polyester.

The base should have following characteristics:

1. Dimensionally stable to maintain uniform image stability during processing and storage.
2. Sufficiently firm and rigid to avoid kinking.
3. Inert so that the sensitometric properties of the emulsion are not affected.
4. Sufficiently transparent for viewing the radiograph clearly.

The base thickness in case of Cellulose Triacetate (CTA) is 180 microns and 160 microns in case of polyester. The thickness should be uniform as otherwise variations in the depth of the emulsion layer may occur. The X-ray film base is given a blue tone to:

1. Give a more pleasing appearance
2. Good visual contrast
3. Avoiding glare while viewing

## The Substratum

Is a gelatin containing layer which binds the emulsion layer to the base.

The emulsion: Is coated over the substratum contains the light sensitive silver halide grains in a gelatin medium. This layer also contain various additives like chemical sensitizers, wetting agents, antifoggants, hardeners etc. which impart the required qualities to the film.

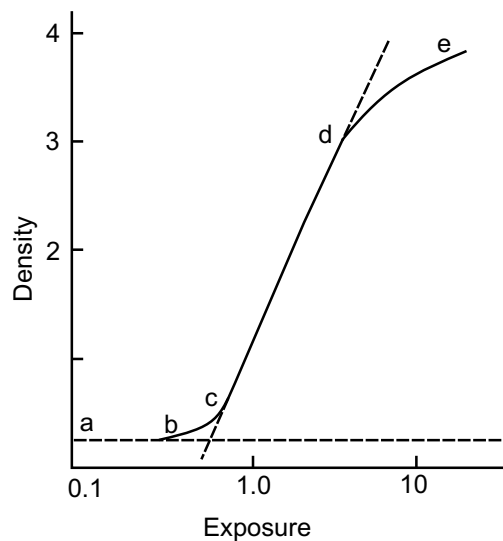
**The top coat:** is a protective layer of gelatin applied over the emulsion layer, protecting it from abrasion and handling damages

**Manufacturing process:** Consists of the 5 stages (1) base casting (2) subbing (3) emulsion preparation (4) coating, and (5) conversion. The x-ray emulsion being light sensitive, the last three stages of the manufacture are carried out under controlled lighting conditions.

## Characteristics of X-Ray Films

Medical X-ray film is a blue sensitive screen type of film. The silver halide emulsion is coated on both sides of the film to minimise the x-ray exposure to the patient and to provide maximum contrast required for obtaining a good radiograph.

Characteristic Curve (Sensitometric Curve)



**Fig. 4.2.2: Characteristic Curve**

The relationship between the exposure of a film and the density produced by exposure is plotted as a curve known as characteristic curve or 'H' and 'D' curve. Film density is plotted on the vertical axis and film exposure on the horizontal axis.

As the exposure is increased, film density at first increases gradually with an upward curve in the toe portion, then more steeply along a straight line and finally along a shoulder portion. The slope of the straight line joining the point on the curve near the toe and the point on the curve near the shoulder has been defined arbitrarily as the average gradient. The average gradient includes the useful exposure density range of a film and varies with the type of film. Those films with greater average gradients show greater contrast for a given subject contrast. It also shows that a contrast at low densities (toe portion) and at high densities (shoulder portion) is poor. Maximum contrast is obtained in straight portion.

### Density

The density is defined as the amount of film blackening which is directly proportional to the amount of metallic silver present on the processed film and is measured using a densitometer in terms of number.

$$\text{Density} = \log_{10} \frac{\text{Incident light Intensity}}{\text{Transmitted light intensity}}$$

Density is an extremely important factor in radiographic quality.

Factors governing the density of radiograph are (1) KV (2) mA (3) Time of exposure (4) Distance (5) Radiographic object (tissue density)



## Speed

The speed of a film refers to its degree of light sensitivity i.e. whether it requires more or less exposure in order to produce a definite density.

The speed or intensifying factor of a pair of intensifying screens may be defined as the ratio of exposure required without screens to the exposure required with screens to get the same degree of blackening of X-ray films.

$$\text{Intensification Factor} = \frac{\text{Exposure without screen}}{\text{Exposure with screen}}$$

**Contrast:** The contrast in radiography is the measure of the density difference between the lightest and darkest points on a radiograph. At least 2% difference in density of adjacent areas is needed to be perceived by human eye.

- Types:**
- (a) Radiographic Contrast
  - (b) Subject Contrast
  - (c) Film Contrast

(a) **Radiographic Contrast:** Is the overall contrast of a radiograph which depends on subject contrast and film contrast.

(b) **Subject Contrast:** X-ray beam while passing through the body is attenuated by different amounts varying depending upon the thickness, densities and atomic number of structures in the body. This difference in intensities in the emerging beam is called the subject contrast.

Various pathologies and administration of contrast media alters the subject contrast.

(c) **Film Contrast:** Film themselves vary in their inherent contrast depending on their emulsion characteristics. The development process also affects the film contrast. The use of intensifying screens, proper developing time, proper temperature of solutions and gentle agitation during developing improves contrast.

A film with double sided emulsion will give greater contrast than one with an emulsion on one side only.

**Film Blur (Unsharpness):** Sharpness is the ability of the X-ray film or film screen system to define the edge. Causes of image blurring are:

1. **Geometric unsharpness :** X-rays do not originate from a point source but from the small area of the focal spot of x-rays tube. This give rise to geometrical unsharpness (penumbra) to the image. It depends on:
  - (a) Effective focal spot size
  - (b) Focus film distance (FFD)
  - (c) Object film distance (OFD)





$$\text{Geometric un-sharpness} = \frac{\text{Effective focus size} \times \text{object film distance}}{\text{Focus object distance}}$$

It can be reduced by

- (a) Small Focal Size
  - (b) Large FFD
  - (c) Small object to film distance
2. **Motion unsharpness:** This is because of patient, equipment or film movement during the exposure. It can be minimised by:
- (1) Proper immobilisation of the part
  - (2) Suspension of respiration during examination
  - (3) Using short exposure time
3. **Absorption unsharpness (object blur):** It is caused due to the absorption of x-rays in the subject. Unless the structure has a particular shape with its edges parallel to the divergent beam, absorption of the x-ray beam will vary across the object. As in a spherical object of uniform density, absorption will be greatest at the centre and least at the periphery due to the difference in thickness giving rise to ill-defined boundary of the object. Little can be done to reduce it.
4. **Photographic unsharpness (Screen Blur):** The x-ray image is first converted to a light image by intensifying screens. This increases the photographic effect of the x-rays and thus allows exposure to be greatly reduced. The intensifying screen contains crystals which fluoresce when irradiated by x-rays. The main cause of photographic unsharpness is the spread of light between the crystals and the photographic emulsion.

It can be reduced by

- (a) Maintaining good screen film contact
- (b) Using fine grain-film

## Fog

Fog is the development of unexposed silver halide grains that do not contain a latent image. Fog represent those silver halide grains in the film emulsion that are developed even though they were not exposed by light or x-rays. Fog produces unwanted, film density which lowers radiographic contrast.

Another type of fog is “exposure fog” which produces unwanted film density as a result of accidental exposure of film to light or x-rays.

Fog is increased by following conditions:

1. Improper film storage (high temperature or humidity)



2. Contaminated or exhausted developer
3. Excessive time or temperature of development
4. Use of high speed film

### Latitude

The ability, of an emulsion to display a radiographic image with a reasonably long tonal range, from white, through various shades of gray, to black. It varies inversely with film contrast. Another aspect of latitude is exposure latitude the range of exposure factors that will produce an acceptable radiograph.

### Types of Films

1. Double Emulsion Film
2. CRT Film

It is an orthochromatic medical x-ray film of 180 microns thick, blue tinted, base coated on one side with fast, high contrast and fine grain emulsion and an anti halation, backing on the other.

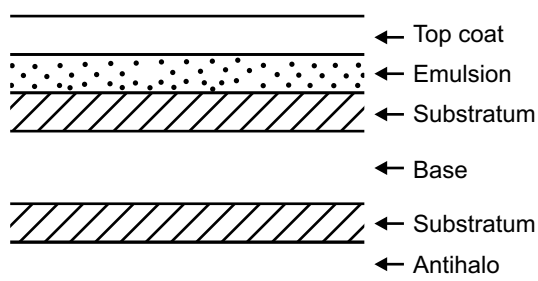


Fig. 4.2.3: Medical Imaging Film

Film is used for the following purposes.

- ◆ CT scanning
- ◆ Ultrasound
- ◆ Nuclear Imaging
- ◆ CRT System
- ◆ Digital radiography
- ◆ Magnetic resonance Imaging
- ◆ Positron Emission Tomography

Antihalo layer prevents halation and ensures mottle free sharp images. Without antihalation the light from the object passes through emulsion layer and gets reflected from the film back to give secondary exposure and thus halation leading to unsharp image.



### **3. Photo Fluorographic Medical Film (MMR Film)**

It is an orthochromatic film of high sensitivity and good contrast with low fog level.

The film is specially sensitised to match the fluorescent emission of the intensifying screens generally used in Mass Miniature Radiography (MMR), equipment's and so it gives excellent contrast and high image quality.

### **4. Mammographic Film**

It is an orthochromatic screen type medical x-ray film coated on 180 microns thick blue-tinted polyester base, on one side with medium speed, high contrast fine grain emulsion and an antihalation backing on the other.

### **5. Duplicating Film**

It is used to copy radiographs

### **6. Dental Film**

This is a direct exposure (non screen type) film also known as envelop wrapped film because of its exposure to x-rays only. Each film is individually folded wrapped in paper and mounted with a stiff card for support inside a moisture resistant paper envelope.

Types

1. Periapical – 31×41 mm film for single or groups of teeth.
2. Occlusal – 56×76 mm film for imaging mandible or maxillae in the occlusal plane.
3. Bitewing – a similar film to the periapical but with a flap which is slid around the film to enable the film to be positioned vertically behind the upper and lower teeth the patient biting on the flap. Used for demonstrating gums.

### **7. Radiation Monitoring Film**

Outwardly similar to dental film in appearance, this film is duplitized, has one very important difference. On one side of the base is a high speed emulsion, while on the other side is a slower emulsion. This permits a wide range of exposure levels to be recorded.

### **8. Laser Film**

#### **Packaging of Films**

X-ray films are packed in hermetically sealed black polythene envelopes which are impervious to humidity and chemical fumes. Further contact between the emulsion surfaces of films in the pouches is avoided by keeping a layer of yellow inter leaving paper between them. Two sealed polythene pouches of 25 sheets each are packed in thick cardboard cartons with the



identification of batch No. and expiry date. X-ray films are available in following sizes (Both CTA & Polyester)

14" × 17"      14" × 14"      12" × 15"      12" × 15"      11" × 14"  
 10" × 12"      8" × 10"      6½" × 18½"

Medical Imaging films are available in

5" × 7"      8" × 10"      10" × 12"      11" × 12"      14" × 17"  
 18" × 24 cms      24 × 30 cms

MMR Films are available in

70mm × 3 mtrs

100mm × 100 mm (100 sheets)

Mammographic films in

8" × 10"      18 × 24 sm.

Serial changes films available in the following sizes

11" × 14"      14" × 14"      12" × 12"

### Storage of Unexposed Films Packets

X-rays films should be stored at 18-20° C and at a relative humidity of 55.5 %. Too warm and too humid store room may cause increased fog level and decomposition of the emulsion. Very low humidity may result in dessication and consequently static marks on the film may occur.

The store room should be free from chemically reactive gases and fumes like ammonia, hydrogen, sulphide vapours, etc.

The film packets should not be kept flat one above the another, so that they are not damaged by the pressure. It should be vertically arranged.

### Cassette

It is the rigid holder that contain the screens and the film. The front surface, the side facing the table, should be made of material with a low atomic number, like plastic or card board or Aluminium and should be their yet sturdy. The front screen is attached inside the front cover and back screen (anterior) to back cover.

The radiographic film is located between these two screens. These days most cassettes are loaded with identical screens for front and back. Between each screen and the cassette cover a compressive device like felt or rubber is placed to maintain screen film contact. To prevent back scatter, back cover of the cassette is made up of heavy metal. Sometimes the cassette



hinge or holds down clamps on the back cover are imaged. This is due to backscatter radiation and normally occur only during high KVp radiography when the x-ray beam is sufficiently penetrating.

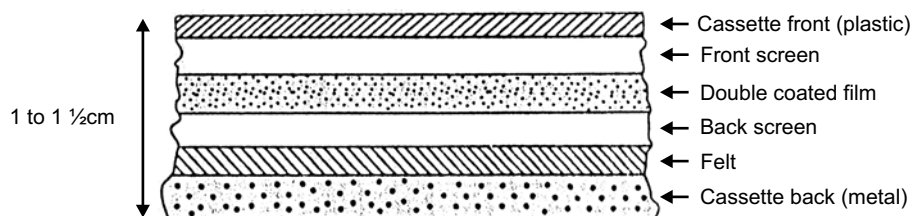


Fig. 4.2.4: A Double Coated Film Between Two Intensifying Screen in a Cassette

### What have you learnt

In this lesson you have learnt about

- ◆ X-rays film, its structures and characteristics
  - ◆ Fogging of films
  - ◆ Types of films
  - ◆ Packaging of film
1. Film/Screen contact is evaluated by a
    - a. Line pair test
    - b. Densitometer
    - c. Wire mesh test
    - d. Sensitometer
  2. When a medium- Speed screen system is substituted for detail screen.
    - a. Patient dose is reduced
    - b. Spatial resolution is improved
    - c. Quantum mottle will be decreased
    - d. Patient motion Artifacts will generally increase
  3. Changing from 200 speed to 50 speed details requires .....mAs
    - a. Increase by a factor 2
    - b. Increase by a factor 4
    - c. Decrease by a factor 2
    - d. Decrease by a factor 4



## Review Questions

- Q 1. Storage of unexposed film packets Which type of base-material commonly used now a days in an X-ray film?
- Q 2. What is the photographic sensitive material used in emulsion layer of X-ray film?
- Q 3. Which colour of tinting dye is used in base material to give a more pleasing appearance.
- Q 4. List what information about the film can be obtained from characteristic curve of a film?
- Q 5. If optical density of one film is 0.75 and optical density of other film is 1 and both film are superimposed. What should be total optical density?
- Q 6. Which of the following film screen combination would require the highest mAs  
(a) Low-speed or detail (b) Medium-speed (c) High speed
- Q 7. What is the common sizes of film used in MMR?
- Q 8. What is the size of Periapical film and where it is used?
- Q 9. What are the various components of x-ray film?
- Q 10. What are the characteristics for x-ray film?
- Q 11. Describe characteristic curve.
- Q 12. Describe Density, Contrast, latitude and speed of x-ray film.
- Q 13. What is image unsharpness? How does it affect radiographic quality?
- Q 14. What is fog? How it can be prevented? What is its effect on radiographic quality?
- Q 15. What are various types of film?
- Q 16. How unexposed film are stored?
- Q 17. Write about cassette.





## Chapter-3

# Intensifying Screens & Fluoroscopic Screens

### Introduction

These are the devices which convert the energy of the x-ray beam into visible light. This visible light then interacts with radiographic film., forming the latent image. Approximately 30% of the x-ray incident on an intensifying screen will interact with the screen. But only, 3.6% of x-ray radiation (1% radiation absorbed by front screen to emit visible light, 1% directly absorbed by each side of x-ray emulsion to form latent image & 0.6% radiation is absorbed by back intensifying screen) coming out of the patient's body alone contributes for the latent image formation. For each such interaction a large number of visible light photons are emitted. Thus intensifying screen acts as an amplifier of the remnant radiation reaching the screen film & cassette. In the previous lesson you have learnt about X-ray films, its structure and characteristics, types of films, package and storage of films.

**Objectives – After reading this lesson you will be able to:**

- ➔ Describe the structure of screen
- ➔ Discuss the types of screens, fluoroscopic screen and image intensifier tube

### Intensifying Screen

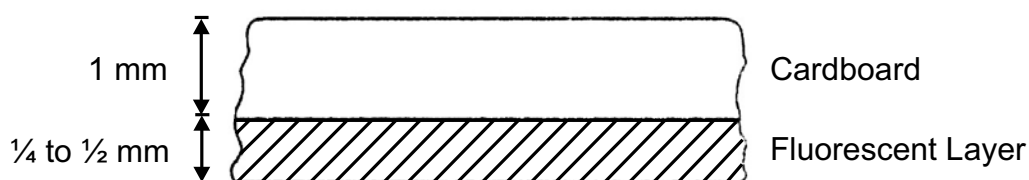

Fig. 4.3.1: Intensifying Screen

This results in considerably lower patient dose and increases radiographic contrast.

There are four layers in most screens.

#### a) Protecting Covering

Transparent layer, closest to the film. It protects the screen from abrasion and damage due to physical handling, eliminates the build up of static electricity and provides a surface for routine cleaning without disturbing active phosphor.

#### b) Phosphor

This is the active layer which emits light when X-rays falls on it. The important characteristics



required are :-

- ◆ High atomic number so that probability of X-ray interaction is high.
- ◆ Should emit a large amount of light per X-ray interaction.
- ◆ Light emitted must be of proper wavelength (Colour) to match the sensitivity of X-Ray film.
- ◆ The after glow should be minimum. Materials viz Calcium tungstate, Zinc sulphide, barium lead sulphate and recently the rare earth like gadolinium, lanthanum and yttrium are used. Rare earth screens are faster and more used now a days.

#### c) Reflective Layer

Shiny substances like magnesium oxide or titanium dioxide are present between the phosphor and the base to redirect the light emitted from phosphor in directions away from film and redirects towards the film. Hence it increases the efficiency of the intensifying screen.

#### d) Base

A high grade card –board, polyester or metal etc. layers serves as a base and gives mechanical support to the phosphor –layer.

### Screen Speed

Fast screen is when a smaller exposure produces a given output light and blackening of film. A term intensification factor is important here :

$$\text{Intensification Factor} = \frac{\text{Exposure without screen}}{\text{Exposure with screen}}$$

Conventional screens are available in five speeds at 70 KV.

Ultra Speed	200
High Speed	100
Medium or far	50
Detail Slow	35
Ultra detail	15

Although screens are widely used they have disadvantages of low resolution compared with direct exposure radiographs. Greater the intensification factor, lower the resolution. Other disadvantages of high intensification factor are :

- 1) **Mottling** – Irregular pattern of density variation due to non - uniformity in coating fluorescent chemical
- 2) **Failure of reciprocity law** – The intensity required to produce a given density is proportional to the reciprocal of two of exposure.



There is no failure, if the X-Ray are directly contributing to latent image formation. But this law fails where the visible light is involved in latent image formation. Where the screen are used, the latent image is formed through the blue light emitted through the screen and therefore law fails, Failure of law is more prominent at very high and very low exposure timing.

### Handling and Usage

Improper mounting of screen, buckled cassettes, bent or broken cassettes or deposition of dust will all result in under images therefore proper handling is a must.

### Luminescence

Phenomenon of emission of light in response to outside stimulation is called Luminescence, and is due to excitation of electrons.

The Luminescence within 10 sec after absorption of an x-ray photon is called fluorescence and that after 10 sec is phosphorescence in an intensifying screen is called screen fog or afterglow, and can be objectionable.

### Fluorescent Screens

Fluorescent Screens are used in fluoroscopy. The visible light emitted by screen is viewed directly by radiologist. Zinc cadmium sulphide is used in fluorescent screens. Fluorescent layer is mounted on a card board with a layer of refractive material, while magnesium oxide interposed between the two. Between the screen and the radiologist, there is a sheet of lead glass having 60% lead by weight.

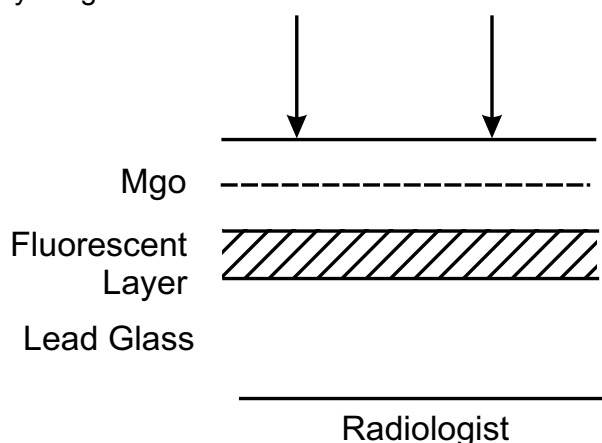


Fig. 4.3.2: Fluorescent Screen

Image intensifier fluoroscopy has overcome the disadvantages of conventional fluoroscopy which were

- Dim vision
- Dark adaptation required by radiologist



- Darkroom makes patients apprehensive
- Radiologist is in the line of primary radiation components of intensification that are an input screen (input phosphor made of CSI), a photocathode (combination of antimony and caesium compounds), an anode and an output screen (output phosphor of very small crystals of {CdS:ZnS, Ag}).

X- rays from the patient are absorbed in input phosphor, light is produced. The Photocathode absorbs light and emits electrons, which are attracted by anode kept at +25 kV relative to cathode. Electrons accelerated towards anode are focussed by electron lenses and are made to strike on an output phosphate through an opening in anode. As the electrons pass through a cross over point near the anode opening, the image on the output phosphor is inverted and reversed. The image is visualized through a system of lenses and displayed on the TV monitor.

The brightness gain in final image is function of two factors i.e. minification gain results from transfer of image from larger input phosphor (6-9 inches) to smaller output phosphor (0.5-1 inch). Flux gain results from acceleration of electrons due to 25 kV difference between photo cathode and anode. Thus, the resultant electrons converge to a smaller area and also gain energy. Most images intensifiers provide brightness gain from 4000-6000.

### What Have You Learnt

In this lesson you have learnt about

- ◆ Intensifying screen
- ◆ Luminescence
- ◆ Fluorescent screens

### Review Questions

- Q. 1. Which are rare earths materials?
- Q. 2. Which type of film should be used with green emitting rare earth screen?
- Q. 3. How the radiographic noise or quantum mottle can be reduced?
- Q. 4. What is the range of fluoroscopic mA currents?
- Q. 5. Input phosphor of an image Intensifier is made of ..... and output phosphor is made of .....
- Q. 6. What is the function of input phosphor of an image intensifier?
- Q. 7. What is the function of output phosphor of an image intensifier?
- Q. 8. What is the function of intensifying screen?
- Q. 9. What are phosphors used in fluoroscopic and intensifying screens?
- Q. 10. Describe screen speed.
- Q. 11. Write about care of screens.



## Chapter-4

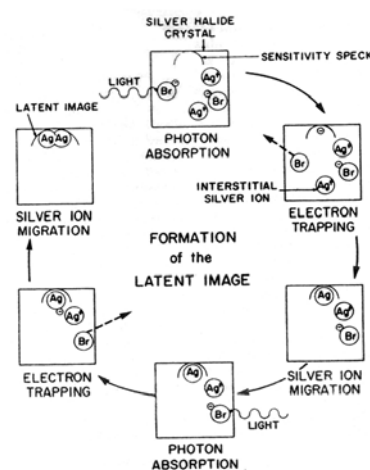
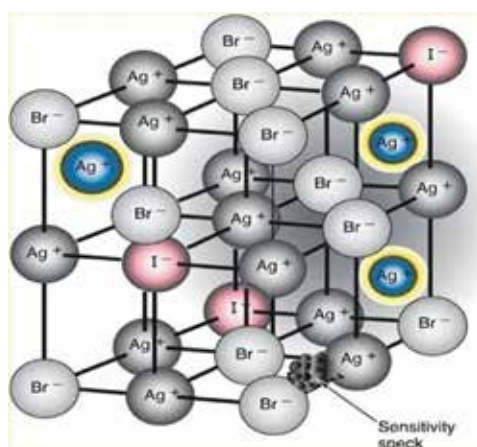
# Processing of X-Ray Films

### Principal of Latent Image Formation

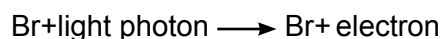
When the X-Ray film is to be developed in the developing solution, the image is to be formed by the action of developing chemicals.

Metallic silver is black; it is silver that produced the dark area seen on the Developed radiograph.

From the exposure of the sensitized silver iodobromide grains the film emulsion to light (from intensifying screen) or to the direct action of X-Rays, initiates the formation of atomic silver to form a pattern.



The energy absorbed from a light photon gives an electron in the bromine ion enough energy to escape. The Electron can move in the crystal for relatively large distance as long as it does not encounter a region of impurity in the crystal.



A site of crystal imperfection such as a dislocate on defect, or an AgS (silver sulfide) sensitivity speck may act a electron trap where the electron is captured and temporally fixed. The electron gives the sensitivity speck a negative charge and this attracts the mobile interstitial positive silver ion ( $\text{Ag}^+$ ) in the crystal. At the speck, the silver ion is neutralized by the electron to from a single silver atom.



This single atom of silver then acts as an electron trap for a second electron. The negative charge causes a second silver ion to migrate to the trap to from a two atom silver nucleus.





Growth of silver atom at the site of original sensitivity speck continues by repeated trapping of electrons followed by their neutralization with interstitial silver ions. The negative bromine ions that have lost electrons are commuted into neutral bromine atom which leaves in the crystal and are taken up by gelation of the emulsion.

A single silver halide crystal may have one many of these centers in which atomic silver is a direct result of the response of the grain to light exposure, but no visible change has occurred in the grain. These small clumps of silver atoms can, however, are seen with electron microscope.

These clumps of silver atoms are termed as latent image centers and are the sites at which the developing process will cause visible which the developing process will cause visible amounts of metallic silver to be deposit. At least two atoms of silver must be present at a latent image centres to make a grain developed.

The more silver atoms that exists at a latent image centre, the greater the probability the grain will be developed.

### Processing of X-Ray Films

There are two types of processing: Manual processing and automatic processing.

Manual processing involves the exposed film to be processed manually by submerging films in each of the processing tanks. Stages in the manual processing involves development, rinsing, fixing, washing and drying, whereas in automatic processing rinsing stage is omitted and film are automatically transported from developing tank to fixing tank and then Washing and Drying. In the previous session you have learnt about intensifying screen, luminescence and fluorescent screens.

**Objectives – After reading this lesson you will be able to :**

- ➡ Explain processing of x- ray films
- ➡ Describe silver recovery
- ➡ State various faults on films & their remedy
- ➡ Process the films both by manual and automatic processing methods

### Manual Processing

Development- function of development is to convert the latent image to a visible image by means of a developing solution.

#### Developing Solution

Main function is to reduce the of exposed silver halide crystal to metallic silver halide crystals. Four crystal ingredients are:





1. **Organic reducing agents-** Usually a mixture of hydroquinone and metol. Hydroquinone is slow acting and is responsible for blackest shades (Contrast) while metol acts fast and influences lighter shades of gray giving fine detail.
2. **Activator-** Sodium carbonate or sodium hydroxide which swells the emulsion for easier penetration of developing agents and also for providing alkaline medium for hydroquinone to react.
3. **Restrainer-** Potassium bromide and iodide(antifogging agents)restrict action of developing agent to only the exposed silver halide crystals; without them, even the unexposed silver would react with unexposed silver ions thus increasing the fog(development fog)
4. **Preservative-** Sodium sulphide protects the reducing agents from oxidation by air, thereby prolonging the life of developer. Hydroquinone is particularly sensitive to oxidation. Oxidized developer attains a brownish colour.

### Practical Factors in Development

Two most important factors in development are temperature of solution and total time of development. Optimum temperature is 20-22° C (68-72 F). With cold developer, temperature below 16° C (60 F), the action of hydroquinone ceases and the resulting radiograph lacks contrast and density. Quality of image is improved in cold developer by prolonging the developing time. Too warm developer i.e. above 24° C (75 F) may soften the emulsion and also produce chemical fog. With non-screen film, developing time is increased by 50% due to greater thickness and silver content of emulsion. With manual development, radiographic exposure is based on 5 minute development at 20° C (68 F). This produces radiographs of superior contrast with about 5KV less exposure than required for 3 minute development. Processing of films on the above basis is called time-temperature development. The inspection method of checking completeness of development should not be used except for rare emergencies, as repeated removal of film from developer during inspection may result in slight fogging due to oxidation.

When films are immersed in developer they should be agitated gently at first and about once every minute thereafter to ensure uniform development and prevent streaking.

### Replenishment

With continued use, reducing agents are gradually exhausted as well as the level of developer in the tank declines as it is carried progressively with each film, because of this loss of strength and volume of developer, a special solution called replenisher is added periodically to ensure consistent quality of radiographs at the same time when more number of radiographs are being processed. In comparison to developer replenisher has

- ◆ No bromide because this ion is already accumulated in developer after being released films.



- ◆ Higher concentration of hydroquinone, metol and alkali because these ingredients are exhausted with continued use of developer.

### Rinsing

After development the film is suspended in the rinsing bath for 30 seconds where water must be kept circulating to remove developer, which otherwise would contaminate the fixer and give rise to colour fog. Also streaks may form on the film due to uneven action of fixer.

Film may also be rinsed in acid bath (15 gm of glacial acetic acid in one gallon of water).

### Fixation-Purpose

1. Removal of unexposed & undeveloped silver halide
2. Preserve film image
3. Harden the emulsion so that it will not be easily damaged.

### Ingredients

1. Fixing agent- Hypo (sodium thiosulphate in powdered fixer, ammonium thiosulphate in liquid fixer) clears the film by dissolving out unexposed undeveloped silver halide. Leaving the metallic silver in exposed and developed areas of film more readily discernible. Without fixation, the undeveloped silver halides would leave the radiograph nearly opaque and would eventually turn black.
2. Preservative- sodium sulphide-protects the fixing agent from decomposition and helps clear the film.
3. Hardner- Chrome alum or potassium alum hardens the gelatin in emulsion, for protection against scratches.
4. Acid- Sulfuric or Acetic Acid neutralizes the alkali remaining over the film and provides optimum medium for Fixer and Hardner.

### Rapid Fixer

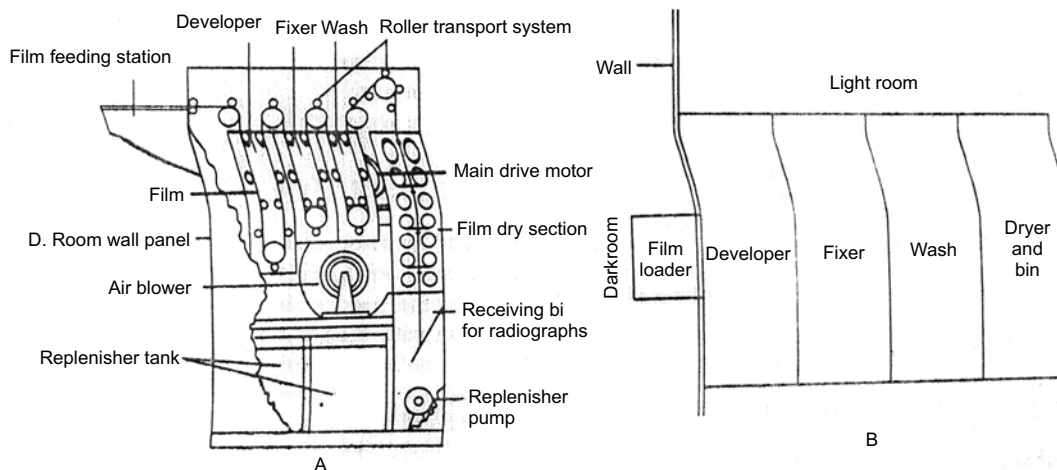
Contains ammonium chloride in addition and reduces fixing time by half.

A satisfactory fixer requires 1-4 minutes to clear the film but 2-3 times of this time is required in hardening the emulsion. Fixer is called exhausted if fixing time is prolonged beyond 10 minutes. Film should not be exposed to light during fixation to avoid deposition of residual emulsion on film. Prolonged fixation also damage the film quality by making hardner adhere to film and turning the film brown. Bleaching of image may also occur. Optimum temperature for fixation is 18°- 24° C. At low temperature, the action is retarded while at high temperature emulsion may be softened and damaged.



Replenishment-requires periodic addition of fresh fixer after discarding equal volume of old fixer.

Washing- To remove the residual hypo from film surface, washing is required which otherwise will change deposited black silver to brown silver sulphide.



**Fig. 4.4.1: Automatic Processing A Side View & B Top View**

Washing under running water requires 20 minutes at 20° C. A fixer neutralizer shortens the time to 5 minutes where films are initially rinsed briefly in rinse tank and then immersed for two minutes in a tank containing special solution which removes the fixer.

Drying- Done in hot dry cabinets the temperature of which should not exceed 35° C.

## Automatic Processing

### Advantages

- Total processing time shortened to 1 ½ minutes.
- Better quality due to accurate temperature controls and better replenishment.
- Increased capacity to handle films.

### Essential mechanisms

1. Transport-mechanism- A series of roller to move films through each section. Constant speed and adequate time in each compartment are essential.
2. Processing chemicals- These differ from those used in normal processing by
  - Increased concentration – To shorten processing time. Hydroquinone and phenidione are used as developing agents.
  - Increased temperature 35° C (95F) in developer, fixer and washer, and 57° C (135 F) in dryer. To combat fog at such high temperature, antifogging agents (aldehydes) are used.



- Hardening of emulsion – To prevent softening and sticking of emulsion, special hardening agents are used like glutaraldehyde, potassium bromide.
- Control of emulsion thickness – sulfates are added to prevent swelling of emulsion and constant thickness is ensured.

Precise replenishment: replenishment of the developer and fixer to maintain the proper alkalinity of the developer, acidity of the fixer and the chemical strength of both solutions, approx.. 60-70 ml. of developer and 100-110 ml of fixer for every 14<sup>th</sup> inch of film are to be added. However, it has to be adjusted.

3. Temperature control – Thermostatically controlled heating elements maintain developer temperature of 35° C and water wash temperature 2.8° C lower.
4. Circulation System – Continuous agitation of developer and fixer is ensured. In wash water section continuous inflow of water and outflow into the sewer is maintained.
5. Film Characteristic – Constant thickness of base and emulsion and minimum curling tendency is required to prevent jamming. Also stickiness of emulsion has to be minimized to prevent adherence to rollers.
6. Processor maintenance – Greatest cause of break down is failure to keep rollers clean as per manufacturers instructions. Another cause is improper rate of replenishment of solutions, sensitometry is coming into wide use to check connections of developer replenishment.

#### **In Dark Room Always Remember**

- Avoid using old films. Follow the date printed on the box of film.
- Store films at the coolest place.
- Don't put boxes of film one over another. Instead put them upright like books on a shelf as undue pressure spoils the films.
- Don't touch film surface with finger nails or hard objects.
- Don't bend the film. Keep the film away from dust.



## Chapter-5

# Silver Recovery

It is reclamation of silver after it has been used for its intended Radiographic purposes.

**Objectives – After reading this lesson you will be able to :**

- List the sources of silver recovery
- Explain the reasons for silver recovery
- Describe the methods of recovery

### Sources

1. Used fixer solution
2. Discarded or scrap films

### Reasons for Silver Recovery

1. Project
2. Economic
3. Air Pollution
4. Conservation
5. Efficiency

As amount of silver in fixer solution increases, the activity of fixer falls & it becomes less efficient in providing image contrast because film hardening is less effective. Films may emerge from processor damp & or stained.

### Methods of Recovery from Used Fixer Solution

#### A. Electrolysis

Used fixer solution contains silver thiosulphate complexes which are negatively charged & some silver-ions which are positively charged. These two exist in electrochemical balance or equilibrium. If two electrodes, an anode & a cathode are placed in the solution and a DC current is passed between them, the positively charged silver ions will be attracted towards the negatively charged cathode where they will be deposited as metallic silver.

#### B. Metallic Replacement

If base metal, such as copper ion or Zinc are placed in a solution containing salts the base metals dissolve into the solution whilst the silver is deposited out of the solution in exchange.



## Methods of Silver Recovery from Films

1. **Chemical treatment** – After chemical wash, this solution is passed through electrolytic recovery cells
2. **Burning of the film** – Silver is recovered from the ash produces.

## What have you Learnt

In this lesson you have learnt about

- ◆ Sources of silver recovery
- ◆ Reasons for silver recovery Automatic Processing
- ◆ Methods of recovery from used fixer solution
- ◆ Methods of recovery from films
- ◆ Manual processing of x-ray films
- ◆ Automatic processing
- ◆ Silver recovery
- ◆ Faults in radiography & remedy

## Review Questions

- Q 1. What is the function of Developer solution?
- Q 2. What is the function the fixer solution?
- Q 3. What is the pH of developer solution?
- Q 4. Silver recovery systems remove silver from which solution?
- Q 5. Replenishment system in automatic processor replenishes which solution?
- Q 6. What do you understand by developing and fixing?
- Q 7. Write the constituents of developer & fixer? Discuss the action of each constituents.
- Q 8. Discuss the factors which affect development of x-ray films.
- Q 9. What is replenisher & why it is added to the solutions?
- Q 10. What do you know by automatic processing? How does it differ from manual processing?
- Q 11. From where silver can be obtained?
- Q 12. How silver is recovered from used film & solutions?





## Chapter-6

**Faults in Radiograph and Remedy****Introduction**

Errors in improper exposing or processing films can produce undesirable radiographs of non-diagnostic quality. These are known as faults in radiograph. In the previous lesson you have learnt about sources, reasons of silver recovery and methods of recovery. In this lesson you will learn about common film defects and remedies.

**Objectives – After reading this lesson you will be able to :**

- Explain common films defects
- Take remedial measures of faulty radiographs
- Employ measures to prevent faulty radiograph

**Common Film Defects are:****1. Fog**

There are many causes of film fogging, that is, a general darkening of the film.

**a) Exposure to light**

This may occur when the dark room is not light proof: the safelight contains too large a bulb; the safe light not functioning or filter is cracked: The safelight filter series is incorrect; or the exposure of the film to the safelight is prolonged, especially at short distance.

**b) Exposure to X-rays or Radionuclides**

Films should be shielded from these sources of radiation and sufficient thickness of lead.

**c) Chemical Fog**

The many causes include overdevelopment or develop excessively in high temperatures: oxidized deteriorated developer may also stain the film (oxidized developer is brown or repeated inspection of film during development and from corroded tanks.

**d) Age Fog**

Either mottled or uniform fogging due to outdated films stored under conditions of high temperature and excessive.



## 2. Stain

Various types of discolorations may appear on films after processing. These can generally be avoided by the use of fresh solutions and correct processing.

- a) Brown. Oxidized developer
- b) Variegated color pattern. Inadequate rinsing.
- c) Grayish yellow or Brown. Excessive fixation or use of fixer.
- d) Grayish white scum. Incomplete washing.

## 3. Marks and Defects

There are several different kinds of characteristics markings when films are not handled gently

- a) Grinkle Marks are curved black or white lines about 1 cm result from bending the film acutely over the end of the film.
- b) Static marks are lightening or tree-like black marks created on by static electricity due to frictions between the film and such as intensifying screens and loading bench. To avoid film should always be handled gently. In addition, their should be grounded in order to prevent the build up electricity.
- c) Water Marks are caused by water droplets on the film, which leave round dark spots of various sizes because of silver particles.
- d) Cassette marks are caused by foreign matter such as fragments or paper etc. or by screen, defects corresponding whiter mark on the radiograph.
- e) Airbell Marks result from formation of air bubble in the developer. A bubble prevents developer from reaching the underlying film and so leaves a small, clear circular spot on the radiograph.
- f) Streaking is caused by a variety of technical errors and is one of the most troublesome types of films defects. It usually results from i) failure to agitate the films in the developer, ii) failure to rinse the films, iii) failure to agitate the films when first immersed in the fixer; and iv) failure to stir the processing solutions thoroughly after replacement.

## What have You Learnt

In this lesson you have learnt about

- ◆ Common film defects
- ◆ Remedy for faulty radiography

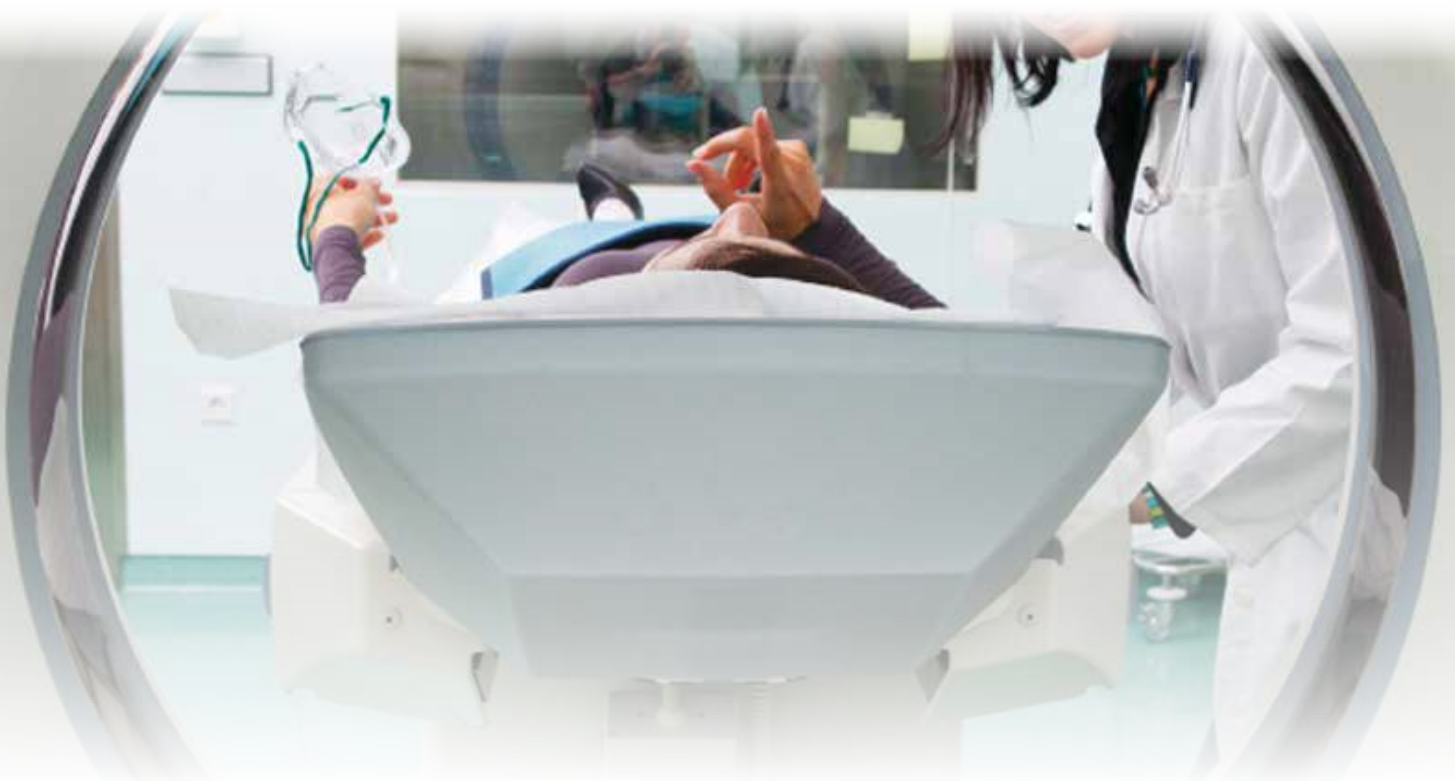## Review Question

Q 1. Discuss various Dark Room faults, it's Causes & Remedial Measures.



## MODULE - IV

# *Basic and Radiation Physics*





## Chapter-1

# Basic Physics and the Units of Measurement

### Introduction

Physics is that branch of science which deals with matter and energy, and their relation to each other. It includes mechanics, heat, light, sound, electricity and magnetism and the fundamental structure and properties of matter. Physics pertaining to the origin, nature and behaviour of X-rays and related type of radiation is called radiological Physics. In this lesson you will learn about fundamental and derived units.

**Objective – After reading this lesson you will be able to :**

- ➡ Discuss the fundamentals & derived units
- ➡ Illustrate various physical quantities and units

### Standard Units

Unit is a quantity adopted as a standard of measurement by which other quantities of the same kind can be measured e.g. inch, ounce and second standard units employed in physics are usually divided into two general types :-

- a) **Fundamental units** – deals with length, mass and time
  - b) **Derivative units** – obtained by combinations of the fundamental units
- A. Fundamental Units** – metric system is internationally used system. It is also known as MKS ( meter, kilogram, second) or CGS ( Centimeter-gram-second) system.
- 1) **Length**  
Metric system unit- meter  
1 meter = 100 centimeters= 1000 millimeters  
 $1\text{\AA} (\text{angstrom}) = 10^{-8} \text{ cm}$   
1Km ( kilometre) = 1000 m (meters)  
1 in (inch) = 2.54 cm
  - 2) **Mass-Units is kilogram**  
1 kg =1000g ( grams)
  - 3) **Time – Unit is second**



## B. *Derived Units*

- 1) **Area** : is the measure of a given surface, and depend on length. In metric system area is represented by square meter for larger surfaces and square centimeters for smaller one.
- 2) **Volume** : is a measure of the capacity of a container and is also derived from length. In metric system expressed in cubic centimeters (CC) or millimetres. 1 Litre=1000ml=1000cc
- 3) **Density** : is the mass per unit volume of a substance and expressed in g per ml
- 4) **Velocity** : is speed in a given direction and can be expressed in cm per sec or km per sec.

## What have you Learnt

In this lesson you have learnt about

- ◆ Standard units
- ◆ Fundamental Units
- ◆ Derived Units

## Review Questions

- Q 1. What is science?
- Q 2. Why standard units are necessary?
- Q 3. What do you understand by unit?
- Q 4. What are the fundamental and derived units?



## Chapter-2

# The Structure of An Atom

### Introduction

By definition matter is anything which occupies space and has inertia. It is made up of molecules which is the smallest subdivision of a substance having the physical properties of that substance.

A substance is any material that has a definite, constant composition eg pure salt, substances may be simple or complex. Simple ones, called elements, cannot be decomposed to simpler substances by ordinary means. Example of elements are sodium, iron, oxygen, hydrogen and chlorine. There are ninety two such naturally occurring elements.

The atom is the smallest fragment of a particular element that is still recognizable as such. The atom cannot be further subdivided by ordinary chemical or electrical methods, but can be broken down into smaller particles by special high energy, atom smashing machines as the nuclear reactor and the cyclotron.

**Objective – After reading this lesson you will be able to :**

- ➡ Describe basic structure of atom and their isotope which is essential for understanding of radiation physics
- ➡ Describe about ion and Thermion Emission

### Atomic Structure – The Electrical Nature of Matter

The most widely accepted theory of atomic structure is that originally proposed by Niels Bohr in 1913, in which the atom is represented as a miniature solar system analogous to the sun with planets revolving around it.

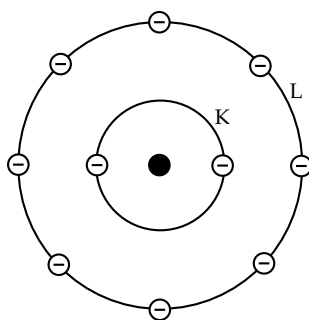


Fig. 2.2.1: Structure of Atom





In the center of the atoms lies the positively charged core known as the nucleus which contains protons and neutrons. Revolving around the nucleus are the much lighter orbital electrons, each carrying a single negative charge. Electrons move in orbits which have a definite distance from nucleus and energy level. These shells are identified by letters of the alphabet. The innermost K shell, next L and so on. Number of electrons in each shell can be calculated by  $2n^2$ , where  $n$  = number of orbit

Eg. No. of electrons in M shell –  $2(3)^2 = 18$  electrons

Atomic Number – is the number of protons or positive charges in the nucleus of an atom

Mass number – is the total number of protons and neutrons in the nucleus of an atom

Isotopes – are the atoms that having same number of nuclear protons (equal to the atomic number of the element) but different numbers of nuclear neutrons.

Ions – are charged atoms having positive or negative charges. The oppositely charged particles attract each other and form a ionic bond. When this compound is dissolved in water and two electrodes are put in it which are connected with battery, positive ions( cation) collect at cathode and negative ion (anion) at anode. This process is called ionization and electrolysis respectively.

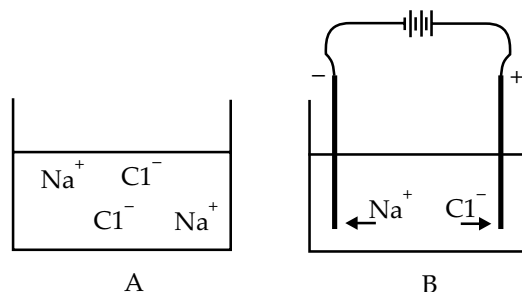


Fig. 2.2.2: Chemical Ionization and electrolysis

**In A is shown a solution of ordinary salt (sodium chloride – NaCl) where ct-ions have separated to form equal number of nat and cl-ions. In B pair of electrodes has been immersed in the solution.**

**The Na + ion move towards the negative electrode (cathode) & the CL-ions drift towards the positive electrode (Anode) and process is called electrolysis.**

**Thermionic Emission :** When a metal is heated to a incandescence (glowing hot) electrons are released from its surface this is called as thermionic emission or thermionic effect.

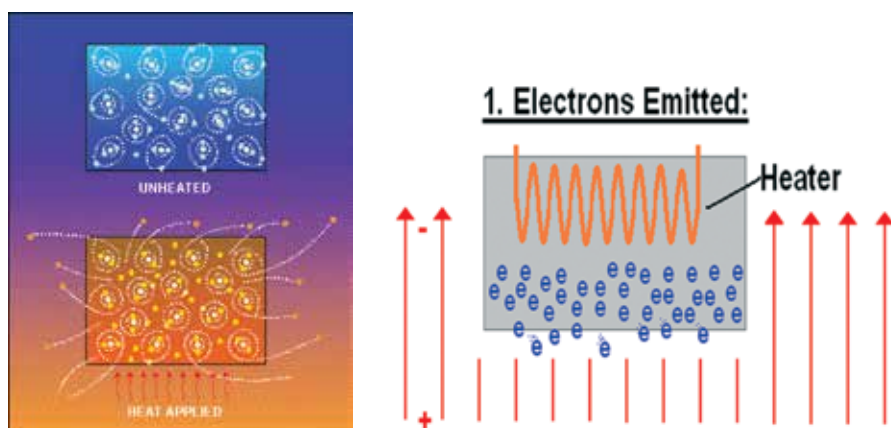
### Thermionic Emission

A substance which readily released electrons when heated is known as thermionic emitter and the process responsible for the release of the electron called Thermionic emission.

The atom which makes up a material, the outer shell electrons are most loosely bounded than the inner electron because they are further away from the nucleus. The application of heat to a body increase the Kinetic energy of its atoms and so increase the violence of their collisions. As a result of these collisions the outer electron may be dislodged from the atom. Electrons so



released near the centre of the body travel only a relatively short distance but they are released near the surface of the material.



In thermionic emission, this is the mechanism by which the electrons are emitted. The higher the temperature of a body, the higher the Kinetic Energy of the Atom and so a greater number of electrons will have sufficient energy to break free from the influence of the surface of the atom of the body.

The efficiency of thermionic emitters may be compared by comparing their work function. Which is normally pressed electron volt (ev). The work function is the amount of work which must be performed by an electron in escaping from the body. Substances which are good thermionic emitters have a lower work function, then those which are poor thermionic emitters. Since in the former, less work is required to allow the electron to escape. The amount of thermionic emission from a body is controlled by

1. The temperature of the body
2. The material of the body
3. The surface of the body

### What Have You Learnt

In this lesson you have learnt about

- ◆ Atomic structure
- ◆ Atomic Number
- ◆ Mass Number
- ◆ Isotopes
- ◆ Ions
- ◆ Thermionic Emission



### **Review Questions**

- Q 1. Define element and compound
- Q 2. What constitutes the nucleus of an orbit?
- Q 3. What is orbit shell?
- Q 4. Define Isotopes
- Q 5. What is an Ion? By what methods ionization be produced?
- Q 6. Define Thermionic Emission



## Chapter-3

# Electrostatics

### Introduction

Electrostatics is the branch of physics that deals with stationary or resting electric charges (static electricity). In the previous lesson you have learnt about atomic structure, isotopes and ions. In this lesson, you will learn about electrostatics, potential differences, electromotive force, Ohm's law, Conductors, Insulators and semiconductors.

**Electrification :-** All atoms contain electrons revolving about a nucleus. If one or more of these electrons are removed, the atom is left with an excess of positive charge and if this is removed, electron become attached to neutral atom then the latter will become negatively charged. This process of adding or removing electrons can be done with body of matter consequently electrified or charged body will have either an excess or deficiency of electrons. This process is called electrification.

Electrification can be done by friction, contact and by induction.

Like charges repel each other and unlike charges attract each other.

**Objective – After reading this lesson you will able to :**

- ➔ Describe potential and potential differences in electric current
- ➔ Explain electromotive force, Ohm's Law
- ➔ Describe conductors, Insulators and semi- conductors
- ➔ Explain resistance & electric power
- ➔ Describe electric capacitor

### Electric Current

It is a flow of charged particles (electrons) which can occur in vacuum by jumping a gap between two oppositely charged electrodes as in vacuum tubes, in gas, water and in metallic conductor.

An electric circuit is defined as the path over which current flows.

The unit of current is the ampere which is one coulomb quantity of electricity flowing per second or  $6.3 \times 10^{17}$  free electrons per sec.

### Potential and Potential Difference

The electric field around a charged body can be described by scalar quantity called electric potential. This is represented by letter V



The electric potential at any point in an electric field defined as the amount of work done in bringing a test charge or a unit positive charge from infinite to that point. The infinity distance may be any where outside the electric field.

### Potential Difference

Let us consider two points A and B in an electric field which are so close to each other the electric field intensity between these points may be taken to be practically constant. The potential of the point A is higher than that of the point B because greater amount of work is done in bringing a coulomb of charge from infinity to the point A than to point B.

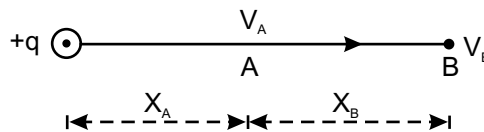


Fig. 2.3.1:

Thus the differences in potential between two points is equal to the work required to move a charge of one coulomb between these two points.

If the potential of the point A is  $V_A$  and that of B is  $V_B$  then since for  $E$  newton acts on the charge of one coulomb, the work done in moving it from B to A is given by :

$$W = \text{force} \times \text{distance}$$

$$W = E \times AB$$

But the work done in bringing a charge of one coulomb from one point to another gives the potential differences between them, therefore

$$W = (V_A - V_B)$$

$$\text{Hence: } V_A - V_B = E \times AB$$

$$E = \frac{V_A - V_B}{AB} = \frac{V_A - V_B}{XA - XB}$$

Point A may be at higher potential than B if work done in moving a unit positive charge from B to A (test charge) is positive. Electrical potential is an important quantity which determines the flow of electric current like water flow from a higher level to a lower level, heat flows from a body at higher temperature to lower temperature, the electric current flows in a conductor from a point at the higher potential to a point at lower potential. If both points in a conductor are at the same potential then current does not flow through them.

### Electromotive Force (Emf) and Potential Differences of a Cell

EMF of a cell is the potential difference across the terminal of the cell when the cell is an open circuit i.e. when no current is drawn from the cell. The current is drawn from the cell then it is called potential difference. Voltmeter measures only potential differences and not the EMF.



## Resistance

It is the property of a substance by virtue of which it offers hindrance to the flow of charge. When electrons flow through a substance, they collide with the ions and their kinetic energy is converted into heat or light. The unit of resistance is ohm. It measures the opposition offered by the conductor to flow of charges through it. If resistance is more, current would be less.

## OHM's Law

It states that the electrical current "I" flowing through a conductor is directly proportional to the potential difference V across its end, provided other physical conditions like temperature remains the same.

Mathematically  $V \propto I$  or

$$V = IR$$

Where R is constant of proportionality called resistance of the conductor, conductance is the reciprocal of resistance .

$R = \frac{1}{G}$  and the electrical conductivity is the reciprocal of electrical resistivity.

The unit of resistance is ohm and is defined as resistance offered to the conductor when one ampere of current passes between its two ends with potential difference of 1 volt.

## Conductors, Insulators and Semiconductors

Materials which can conduct electricity are called conductors, If we rub a metal rod held in hand with a fur, it will not develop charge because the metal rod, the human body and the earth are conductors of electricity so that the charge generated in the metal rod will pass to earth through the human body. On the other hand, when we rub a glass rod with silk it can retain the charge in itself because of its being insulator. In conductors electric charge can move freely whereas they cannot do so in insulators. There are no perfect insulators but in many practical purposes some materials behave as if they were perfect insulators.

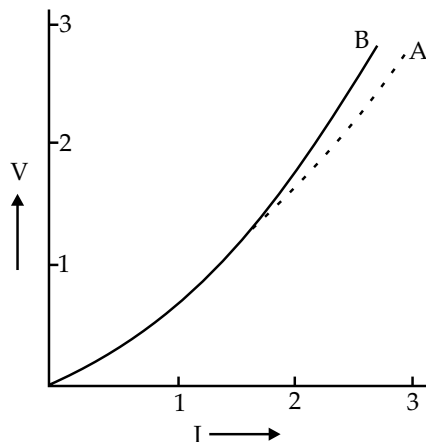


Fig. 2.3.2:





In metals, only negative charge is free to move i.e. electrons carry the actual charge. The outer electrons do not remain attached in their respective atom but are rather free to move throughout the volume of the metallic solids. For some conductors e.g. electrolytes, both positive and negative charges can move.

The semiconductors fall between conductors and insulators. Silicon and germanium are good examples of semi- conductors. The electrical conductivity of semi - conductors can be greatly increased by adding very small amount of other elements ( impurities). They have many practical applications including their use in transistors.

Electric power :- It is the rate of consumption of electric energy i.e. the rate at which electrical energy is being converted into some other form.

If potential difference of  $V$  volt is applied in an electric circuit and current of " $I$ " ampere flows for time  $t$  sec, the electrical energy

$$W = V I t \text{ joules}$$

$$\text{Electric Power } P = w/t = VI \text{ watts}$$

The bigger units of power is 1 kilowatt (1000 watts) and 1 mega watt ( $10^6$  watt)

## Electrical Energy

When a current  $I$  flows through a conductor for given time  $t$

$$\text{Electrical energy} = V I t = P.t$$

Unit is joule

$$1 \text{ Joule} = 1 \text{ watt } 1 \text{ second}$$

$$1\text{KWH (kilo watt hour)} = 1 \text{ Kw } 1\text{hr}$$

$$= 1000 \times 3600 \text{ sec}$$

$$= 3.6 \times 10^6 \text{ watt sec}$$

$$= 3.6 \times 10^6 \text{ Joule}$$

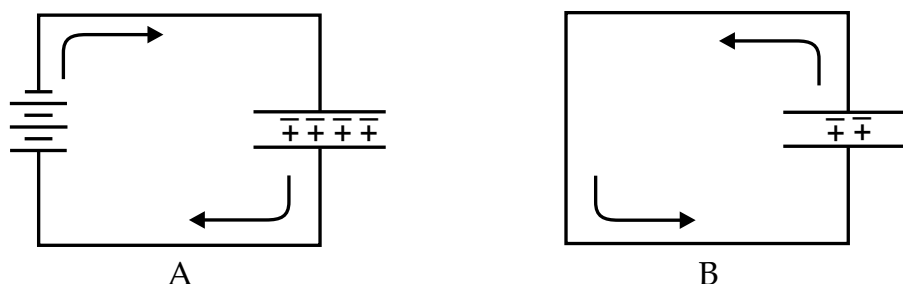
## Electrical Capacitor or Condenser

Capacitor is a device that stores electronic energy provided it is insulated so that the charge does not leak.

Parallel plate condenser is the simplest type of this device. This is made of two flat metallic plates parallel to each other and separated by a small space containing air or some special insulating material and when a capacitor is connected to a power of direct current such as battery, electrons move from negative terminal of the battery to the plate to which it is connected. An equal number of electrons pass from the other plate to the positive terminal of the battery as shown is Fig.2.3.3



## Capacitor



**Fig. 2.3.3: Parallel Plate capacitor.**

In A the capacitor is connected to a battery and is being charged. In B the capacitor has been disconnected and its plate connected by a wire, where upon it loses its charge. The arrows indicate the direction of electrons flow in the wire.

No electrons pass from one place to other across the space required between them. However, excessive voltage between the plates may break down the insulation. When the capacitor acquires full charge the potential difference across its plate will reach maximum value and the current stops flowing in the circuit.

If the capacitor is disconnected from the battery, it will retain the charge, when the capacitor discharges, by connecting with conducting wires, the flow of current is opposite to that of the charging current. The current will flow till the capacitor is fully discharged.

## Capacitance

It is the quantity of charge that a capacitor store per unit voltage. The capacitance is said to be one farad ( unit) if it stores 1 coulomb of charge per volt.

The larger the area of the plates and smaller the space between them, greater will be the capacitance. The insulating material between the plates (dielectric) also influences, the capacitance.

## What have you Learnt

- ◆ Electric Current
- ◆ Electromotive force & potential difference of a cell
- ◆ Conductors, Insulators and Semi- Conductors
- ◆ Electric energy
- ◆ Electric capacity



## Review Questions

- Q 1. What is unit of electric current?
- Q 2. What do you mean by a current of 1 ampere?
- Q 3. What is the unit of electric potential?
- Q 4. What is the amount of capacity of a capacitor?
- Q 5. What is resistance?
- Q 6. What is electric power?
- Q 7. What is meant by electrification, and electric field?
- Q 8. Describe electrification by contact and by induction
- Q 9. What is conductor?
- Q 10. What is insulator?
- Q 11.
  - a) What is electric current?
  - b) How does it flow along a wire and in salt solution?
  - c) Its unit?
- Q 12.
  - a) Define potential difference
  - b) What is the unit of measurement?
- Q 13. What is meant by the electrical resistance?
- Q 14. State ohm's law?
- Q 15.
  - a) What is the power formula?
  - b) What is the unit of power?
- Q 16.
  - a) What is an electric capacitor?
  - b) Describe its mode of operation.



## Chapter-4

# Magnetism

### Introduction

Magnetism is the ability of certain material to attract iron, cobalt or nickel and any material that attracts these materials is called a magnet. In the previous lesson you have learnt about electric potential difference in electric current, electromotive force, ohm's law, conductors, insulators and semiconductors. In this lesson you will learn about Magnets, its types, properties and electromagnets.

*Objective – After reading this lesson you will be able to :*

- ➡ List the types of magnet
- ➡ Describe the properties of magnet, magnetic field and lines of force
- ➡ Explain electromagnetism, electromagnetic induction

### Magnets

There are three types of magnets:

1. **Natural magnets** - like Earth, lodestone etc.
2. **Artificial magnets**- Hard steel in the form of a bar or horse shoe which are artificially magnetized.
3. **Electromagnets**- Produced by passing electric current and remain so as long as the current flows.

### Properties of Magnet

- 1) Every Magnets has two poles one at each end and one pole is called north and the other is south. If a bar magnet is suspended freely, the end that points towards the geographical north pole of the earth is called north pole and the points towards the south is called south pole.
- 2) Like poles repel and unlike pole attract each other.
- 3) The forces of attraction or repulsion between two magnetic poles is directly proportional to the product of pole strengths and as the square of distance between them.



## Magnetic Fields and Lines of Force

A magnet has space around it where it can attract small iron pieces. This zone of influence is called magnetic field. This can be shown by placing a card board piece over a magnet and then sprinkling iron filings on the card board. The fillings arrange themselves into a pattern as shown in fig.




Fig. 2.4.1 (a): Magnetic line of force about and in a magnet

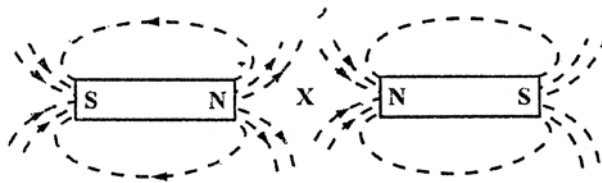

Fig. 2.4.1 (b): Line of Force between like poles

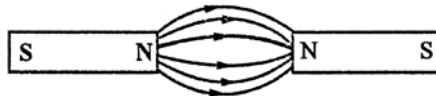


Fig. 2.4.1 (c): Line of force between unlike poles

The lines along which iron fillings align themselves are called lines of force of magnetic flux. The strength of a magnetic field is proportional to the number of lines of force per square centimetre. The direction of Lines of force are directed from north to south pole in the surrounding space and from south to north with the magnet. These lines of force can however, be distorted by magnetic material.

## Magnetic Permeability and Retentivity

The ability to get magnetised by some materials ( like soft Iron ) is called magnetic permeability. Some materials such as steel retain their magnetization even after they are removed from the magnetic field. The ability to retain magnetization by some materials is called magnetic retentivity. Some iron has high magnetic permeability but low magnetic retentivity.

## Magnetic Flux

The total number of lines of induction passing through a surface is called magnetic flux. It is denoted by ( $\Phi$ ) pie.



The unit of magnetic flux is weber in SI units and unit of magnetic field is weber/m<sup>2</sup> or Tesla.

### Types of Magnetic Material

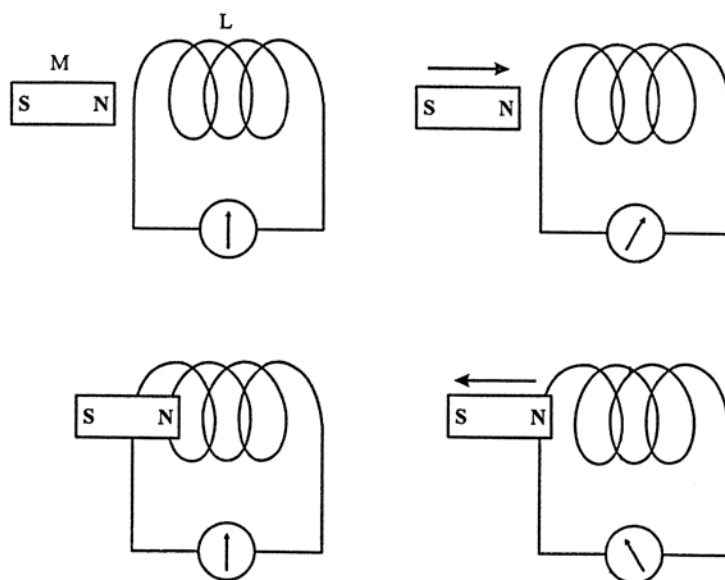
- 1) **Ferromagnetic materials** :- have high permeability or susceptibility to magnetic induction. Iron, Nickel and Cobalt are the examples.
- 2) **Paramagnetic materials** :- are freely attracted by magnet eg Platinum
- 3) **Diamagnetic materials** :- these are usually repelled by a magnet, although this action is feeble. Examples are Beryllium and bismuth.
- 4) **Non Magnetic materials** :- they are not at all influenced by the magnetic field. Examples are wood, glass and plastic.

### Electromagnetism

A magnetic field always surrounds a conductor in which a current is flowing . the direction of this field may be represented by left thumb rule.

If the wire is held in the left hand with thumb pointing in the direction of the current ( - to +), then the fingers encircling the wire will indicate the direction of the magnetic lines around the current carrying conductor.

The magnetic field exists around a wire only when the electric current flows through it. If a wire is in the form of a coil or helix ( solenoid) and if current passes through it, one end behaves as a south pole and other as a north pole. If an iron rod is placed inside the coil it will become magnetized by the magnetizing field of solenoid. Such solenoid with an Iron core is called electromagnet.



**Fig. 2.4.2: An example of electromagnetic induction. A current flows only when there is relative movement between the bar magnet and the solenoid.**





## Electromagnetic Induction

Wherever the magnetic lines of force passing through a coil or a conductor vary either by moving the coil or by changing the electric current in the coil, an emf is induced in the coil.

The magnitude of the induced emf depends the change in magnetic flux linked with the coil or conductor. The direction of induced emf is given by left hand rule.

If the thumb fore finger and the central fingers of left hand are stretched in such a way that they are at right angles to each other and if the central finger represents the direction of current, the thumb, the direction of motion then the fore finger will represent the direction of the induced emf.

## What have you Learnt

In this lesson you have learnt about

- ◆ Properties of Magnet
- ◆ Magnetic fields & line of force
- ◆ Electromagnetism
- ◆ Electromagnetic Induction

## Review Questions

- Q 1. If a bar magnet suspended freely, how will it align with earth's magnetic field?
- Q 2. What is SI unit of strength of magnetic field?
- Q 3. How many gauss make one Tesla?
- Q 4. What do you know by magnetism?
- Q 5. Name and discuss briefly the main types of magnets
- Q 6. Explain magnetic Induction
- Q 7. How does a magnet attract a piece of Iron?
- Q 8. What is magnetic field and magnetic flux?
- Q 9. In what direction do the magnetic lines of force travel in a magnet?
- Q 10. How is magnetism detected?
- Q 11. What do you know by permeability, Retentivity flux, field and poles?
- Q 12. What is thumb rule? How it is applied?
- Q 13. What is electromagnetic induction and electromagnet?
- Q 14. What type of current is usually employed to produce self induction?



## Chapter-5

# Transformer

### Introduction

A transformer is an electromagnetic device which changes an alternating current from low voltage to high voltage or from high voltage to low voltage, without loss of an appreciable amount of energy (less than 10 %). It transfers electrical energy from one circuit to another without the use of moving parts or any electrical contact between the two circuits, employing the principle of electromagnetic mutual induction. The high voltage transformer is often called the X-ray generator. In the previous lesson you have learnt about magnets, its properties and types of electromagnetism and electromagnetic induction. In this lesson, you will be learning about transformers, its types, autotransformers and power losses.

**Objectives – After reading this lesson you will be able to :**

- ➔ explain high voltage and low voltage transformer
- ➔ describe types of transformers
- ➔ explain autotransformers
- ➔ describe power losses and its significance in radiology

### Types of Transformers

1. **Open core :-** It is constructed like induction coil. Primary coil is wound about core of laminated Iron and the secondary coil on the other one as shown in Fig. 2.5.1

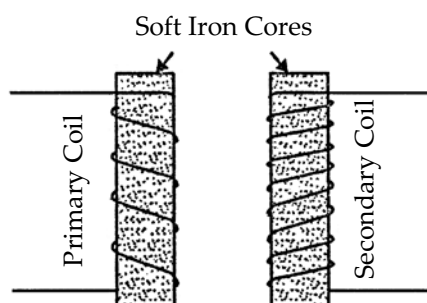


Fig. 2.5.1: Open Core Transformer

2. **Closed Core Transformer :-** In this primary & secondary coils are wound around a square or circular iron. The closed core provides a continuous path for the magnetic flux, so that only a small fraction of the magnetic energy is lost by leakage. Most transformers used in X-ray equipment are of this type.

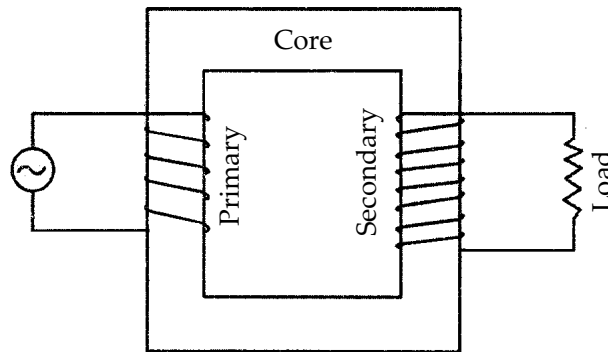


Fig. 2.5.2: Closed Core Transformer

3. **Shell type transformers** :- In this primary and secondary coils are both wound around the central section of the core. This is possible because in any type of transformer the coils must be highly insulated from each other which is achieved by coating the wires of both coils with special insulating and also immersing the transformer in a container filled with a special type of oil for maximum insulation & cooling. This is most advanced type of transformer used as a commercial or power transformer.

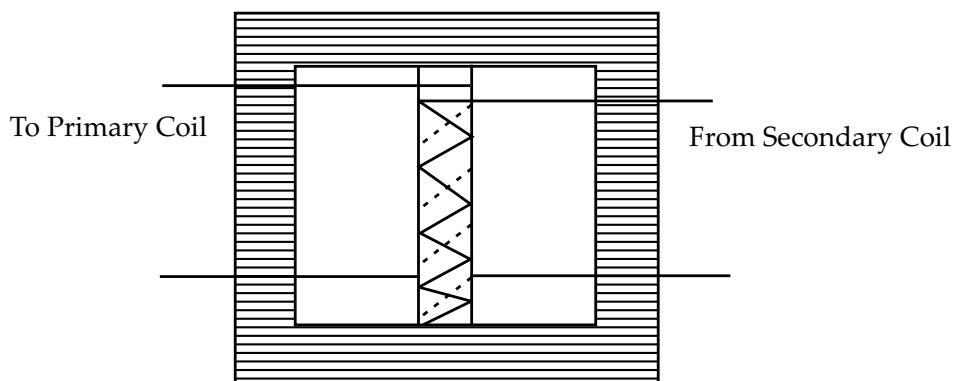


Fig. 2.5.3: Shell Type transformer

Note the winding of Primary & Secondary coils around same central section of the core very heavy insulation is required.

### Construction

Transformers are one of the most useful applications of electromagnetic induction. It consists of two coils each consisting of many turns of wire wound in an iron coil, one of these coils is known as primary which is connected to an AC source. The other coil is known as secondary is connected to the load which may have an electrical device is supplied.

The alternating current in the primary coil produces an alternating magnetic flux in the core which passes through the secondary coil. Later on when the primary coil is connected to AC



main the alternating current in the primary coil produces magnetic flux in the iron core. This flux is linked to the secondary coil and thus an alternating electromotive force is induced in it. The magnitude of the induced emf depends upon the number of turns in both the coils.

## Auto Transformer

Required range of kilo voltages can be obtained by varying input to the transformer primary. For radiography, various kv must be applied to X-ray tube to obtain X-ray beams with a variety of penetrating abilities. without flexible voltage control, modern radiographic procedures would be seriously hampered. The main device for high voltage control is the auto transformer.

**Construction :-** It is made up of coil of insulated wire wound around a large iron core. At regular intervals along the core, insulation is interrupted and the bare points connected or tapped to a metal buttons.

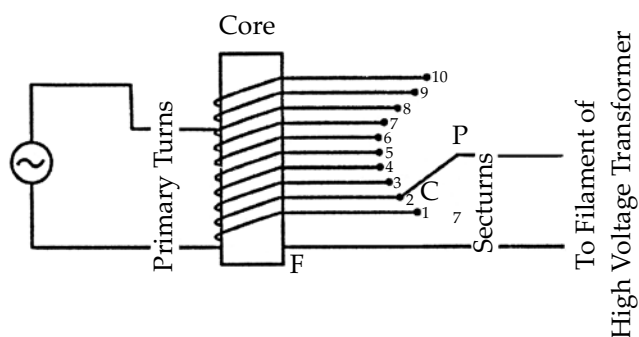


Fig. 2.5.4: Auto Transformer

A movable contactor C varies the number of turns included in the secondary circuit of the autotransformer. Thereby varying output voltage.

**Principle :-** It also acts on principle of self induction.

A single coil serves as both the primary and secondary coil, the number of turns being adjustable while in others types of transformers ( described earlier) no of turns cannot be changed.

$$\frac{V_s}{V_p} = \frac{N_s}{N_p}$$

Where VS - Output voltage i.e. voltage produced on secondary side

VP - Voltage appeared on primary side

NS - Number of turns on secondary coil

NP - Number of turns on primary Coil

The secondary voltage of the autotransformers is applied to the primary side of the main step-up transformer of X-ray equipment. Auto transformers can be used only where there is a



relatively small differences its input and output voltage. The position of the contactor should not be changed while exposure switch is closed because sparking may occur between the metal buttons, there by damaging them.

### Power Losses

- 1) **Copper Losses** :- These include mainly the loss of electrical power due to resistance of the coils. Such loss of power can be reduced by using copper wire of adequate diameter.
- 2) **Eddy Current Losses** :- The fluctuating magnetic field, set up in the transformer core by the AC in its coils, induces eddy current in the core itself by electromagnetic induction. The eddy currents, in turn produce heat in the core, thus waste of power. This can be minimized by the use of laminated ( layered ) silicon steel plates, highly insulated from each other.
- 3) **Hysteresis Losses** :- Since the transformer operates on and puts out AC the tiny magnetic domains in the core are repeatedly rearranging themselves as the core is magnetized first in one direction then the other by the AC in the coils.

This rearrangement of the domains produces heat in the core, thereby wasting electrical power. This loss of power is called hysteresis and is reduced by using the laminated silicon steel core.

### What you have Learnt

In this lesson you have learnt about

- ◆ Types of transformers
- ◆ Autotransformers
- ◆ Power Losses

### Review Questions

- Q 1. What is the function of high voltage transformer in X-ray circuit?
- Q 2. What is the function of low voltage transformer in X-ray circuit?
- Q 3. What is the function of autotransformer?
- Q 4. How does Autotransformer works on the principle of self induction or mutual induction?
- Q 5. How do power losses in transformers be reduced?
- Q 6. What is transformer?
- Q 7. What are the types of transformers?
- Q 8. Describe construction of transformer
- Q 9. Why is a core used in a transformer?
- Q 10. What are the purpose and principle of an auto transformer?
- Q 11. How does it operate?
- Q 12. Why is the auto transformer preferred in the control of high voltage in an X-Ray machine?
- Q 13. Discuss various power losses and it's significance in radiology?



## Chapter-6

# X-Ray Circuit Rectifier

### Introduction

Rectification is the process of changing alternating current to direct current. An X-ray tube can operate on any high voltage AC. But it operated most efficiently when supplied by high voltage direct current( DC). In the previous lesson you learnt about transformers, Autotransformers and power losses. In this you will learn about rectifiers and its different types used in X-ray generators.

**Objective – After reading this lesson you will be able to :**

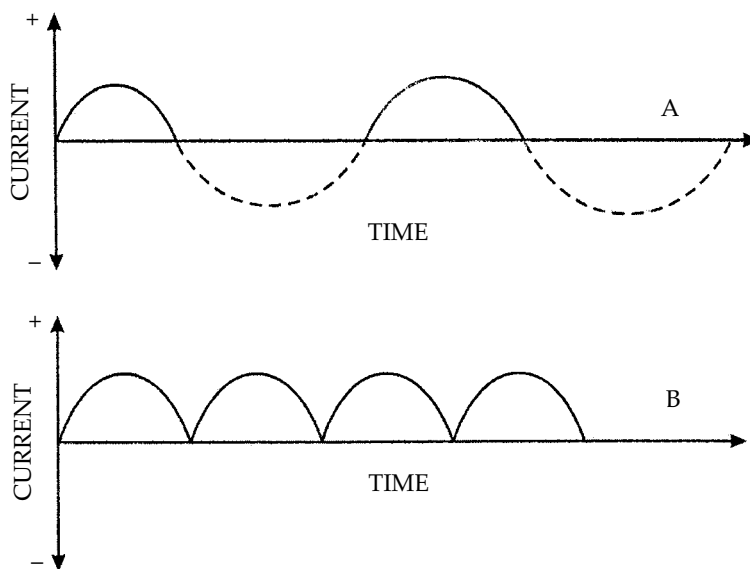
- ➡ Explain rectifier
- ➡ Describe methods of rectifying alternating current
- ➡ Recognize the importance of rectifiers

### Rectifier

Rectifier are essential components of X-ray generators and controls voltage ripple and also quality and quantity of X-rays.

This can be done by :-

- ◆ Suppressing that half of the AC cycle represented by the portion of curve that lies below the curve.
- ◆ Changing the negative half of cycle to positive one.



**Fig. 2.6.1: Methods of Rectification**





## Methods of rectifying an alternating current are :

### Self rectification

#### Solid State diode rectification

Rectifier are located between the secondary coil of the transformer and x-ray tube.

#### Self Rectification

In this high voltage is applied directly to the terminals of the X-ray tube. An X-ray tube allows passage of electrons only from cathode to the anode during the positive half cycle of the A.C. curve, when the anode is positively charged. This half of the voltage cycle is the useful voltage in forward bias. During negative half cycle the anode is negative and cathode is positive, but despite the presence of a high voltage across the tube, no current will normally flow because there is no space charge near the anode. In a self-rectified circuit the anode must never be heated to point of electron emission because then during the negative half cycle, the inverse voltage would drive the electrons in the wrong direction i.e. towards the filament – causing the filament to melt and ruin the tube. Self-Rectification is used in small, mobile x-ray apparatus but it is being gradually replaced by most sophisticated methods, described below.

#### Rectifiers

It is a device that allows an electric current to flow in one direction but does not allow current to flow in the other direction. Rectifiers are incorporated into X-ray circuit in series with X-ray tube. High voltage rectifier can be of vacuum tube type or they can be of solid state composition (Silicon Rectifier).

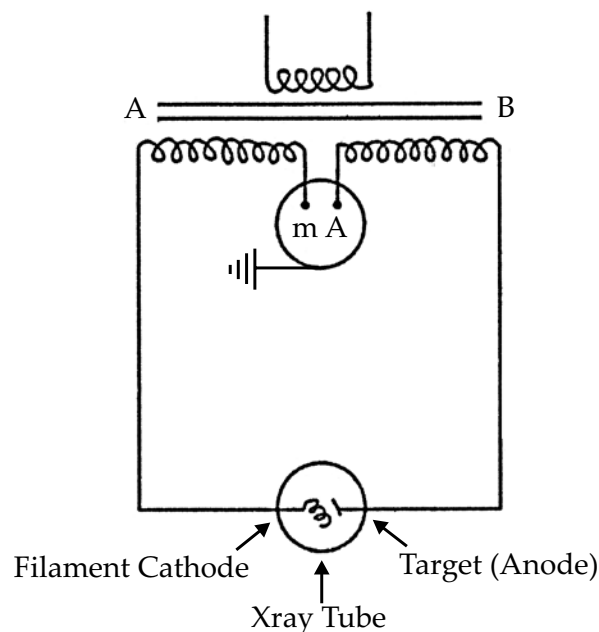
In modern X-ray equipment valve tubes are no longer used. Today most X-ray generator use silicon rectifier.

A silicon rectifier will resist a reverse voltage of about 1000V. A silicon rectifier is made up of no. of individual diode connected together to form a cylindrical rectifier that might have dimension of 20-30 cm long and 20 mm diameter.

#### Half Wave Rectification

When single solid state rectifier is used, it produces half wave rectification signals to X-ray tube.

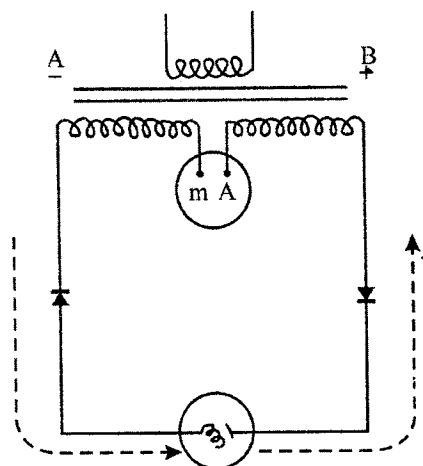
If two diode are used as shown in Fig.2.6.3 inverse voltage half cycle is no longer applied to the X-ray tube it is stopped by rectifier so thermionic emission target is no longer a problem. Main reason for production of this type of unit as opposed to full wave rectifier unit were that it was significantly cheaper.



**Fig. 2.6.2: The circuit for self –rectification.**

Half wave rectification has the disadvantage that only alternate half cycle are used to produce X- rays.

Modern X-ray generator use full wave rectification which utilizes the full potential electrical supply. Fig 2.6.4 shows production of full wave rectification.



**Fig. 2.6.3: Circuit for half wave Rectification**

When in ends of step up transformer is negative with respect to other end in two diode conduit and other two diode becomes non- conducting and vice versa.



This manner four rectifier produces a pulsating direct current through X- rays and even though the transformer supplied an alternating input current.

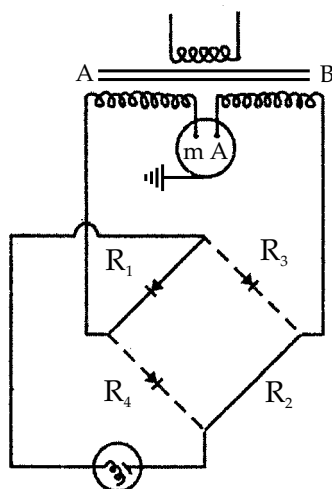


Fig. 2.6.4: Circuit for full wave rectification

### Advantage of Full Wave Rectification

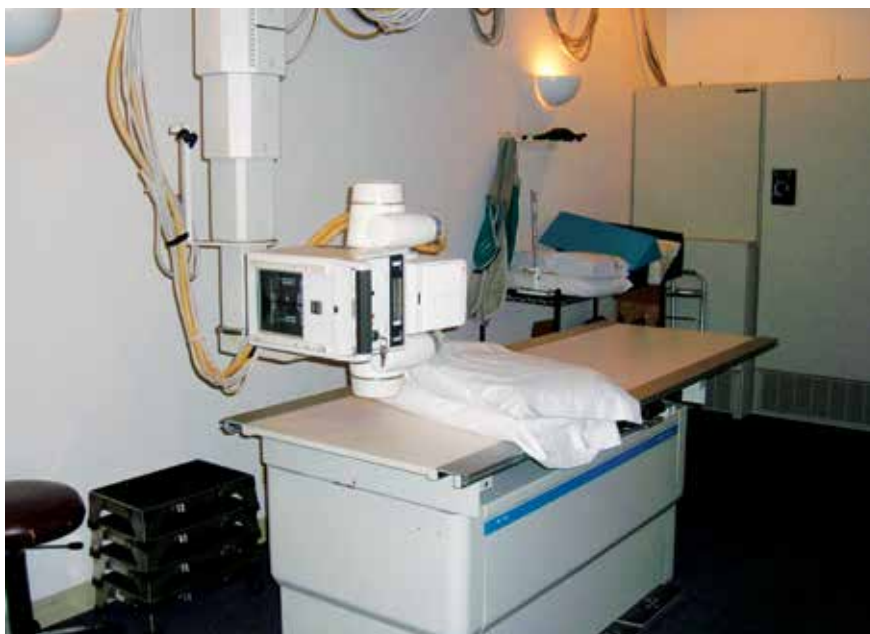
The full wave rectification increases considerably the tube rating or heat loading capacity i.e. larger exposures can be used without damaging the tube.

### Disadvantage

The utilization of entire AC wave results in the production of a high percentage of low energy x-ray at lower KV.

### Three Phase X-Ray Generator

The three phase X-ray generator uses a 3 phase AC line source ( three wires, each with a single phase AC sinusoidal wave one third of a cycle out of phase with the two. Three separate high voltage transformers are used together in a “Wye” or delta configuration to convert the low voltage AC wave forms to a high voltage. rectifiers in the circuit produce two pulses per cycle of each line, resulting in a total of six pulses per cycle. This is known as 3 phase 6 pulse generator. It is also possible, using a different configuration of transformer and rectifier, to produce 12 pulses per cycle in a 3 phase 12 pulse generator.



**Fig. 2.6.5: X-ray Generator**

### **Medium and High Frequency Inverter X-Ray Generator**

The inverter generator represents the state of the art in generator design technology. It has many advantage regarding kV control and exposure switching together with voltage ripple characteristics of 3 phase 12 pulse generator. Although a 3 phase, input voltage is commonly used, a single phase voltage input source can be used as well. Use of single –phase input power limits the intensity of X-ray beam, however simplified installations and reduced cost are key advantages. High Voltage transformers operating at high frequencies are much smaller than conventional transformers and allow inverter generator to be much more efficient generator design. Some manufactures have engineered the generator and the X-ray tube within the same enclosure.



**Fig. 2.6.6: Inverter**



The waveform produced by a medium/high frequency generator follows the following steps:-

- 1) Either a single phase or 3 phase line voltage is converted to constant potential by rectification and smoothing circuit.
- 2) An inverter converts the DC waveform into a medium to high frequency (5 to 100 KHz) AC square wave voltage.
- 3) A transformer converts the low AC square wave into high voltage AC and
- 4) Full wave rectification in high voltage circuit eliminates any possibility of polarity reversal on the anode or cathode. The kV is controlled by varying the frequency of the inverter – a high pulsating frequency produces high voltage. The medium/high frequency generator permits fast and accurate control of the tube voltage.

Voltage Ripple is defined as amount of variation in the applied X-Ray tube waveform minimum to the peak voltage during X-ray production.

A 0 % ripple is ideal, such that voltage would be applied consistently through the exposure, voltage ripple for :

Single Phase generator	100 %
Three Phase	13.4% to 3.4 %

### What have you Learnt

In this lesson you have learnt about

- ◆ Rectifiers
- ◆ Methods of rectifying alternating current

### Review Questions

- Q 1. What is the function of rectifier?
- Q 2. List one advantage of full wave rectifier over self wave rectifier.
- Q 3. What are the advantages of 3 phase rectifier?
- Q 4. List any two advantages of medium frequency generator?
- Q 5. What is rectification?
- Q 6. What is the use of rectification of current for X-ray generation?
- Q 7. What are the types of rectification?
- Q 8. Draw the diagram of half wave and full wave rectifier.





## Chapter-7

# X-Ray (Roentgen Rays) and X-Ray Tube

### Introduction

X-rays were discovered in 1895 by Sir Wilhelm Conrad Roentgen, a German physicist while studying the high voltage discharge phenomenon in a vacuum tube (Crooke's tube). In the previous lesson, you have learnt about the rectifiers and methods of rectifying alternating current. In this lesson you will learn about X-rays, X-ray tubes and its production.

**Objective – After reading this lesson you will be able to :**

- ➡ List the components of X-ray tube
- ➡ Describe how X-rays are produced
- ➡ Explain Bremsstrahlung radiation and characteristics X-rays
- ➡ Describe causes of heat dissipation and causes of tube failure
- ➡ Explain factors governing tube life and steps to extend tube life

### X-Rays

X-rays are electromagnetic waves which travel with the speed of light ( $3 \times 10^8$  meter/sec or 186,000 miles /sec.) These are produced whenever a stream of fast moving electrons suddenly undergoes a reduction in speed.

$$C = v\lambda$$

C = speed of X-rays in vacuum or air

v = frequency in hertz

$\lambda$  = wavelength

The speed of all electromagnetic waves is constant in a given material, an increase in frequency (v) must always be accompanied by a corresponding decrease in wavelength ( $\lambda$ ) and conversely, a decrease in Wavelength. Frequency is inversely proportional to the wavelength. The useful range of X-ray wavelengths in ordinary Radiography is about 0.1 - 0.5 Å ( $1 \text{ Å} = 10^{-8}$  or one hundred millionth).

### Properties of X-Rays

1. X-rays are electromagnetic rays which behave as waves as well as particles.
2. They have great penetrating power.
3. They are electromagnetic waves, having no charge





4. They cause ionization of gases by removing orbital electrons from atoms
5. Their wavelength ranges from 0.1 to 0.5 Å having energy levels of 25 to 125 keV
6. They travel at the speed of light ( $3 \times 10^8$  m/sec)
7. They travel in straight line, like light rays but they cannot be focused by a lens.
8. They liberate minute amounts of heat on passing through matter.
9. They cause fluorescence of certain crystals.
10. They cause photographic effect on silver halide crystals, which is a chemical change.
11. They can produce other chemical as well as biological changes mainly by ionization and excitation.

The X-radiation is heterogeneous with continuous spectrum. The penetrating power of these radiations increases with their energy. Based on their penetrating power, they can be classified as 'Hard' or 'Soft' X-rays. Hard X-rays are of relatively shorter wavelength with little absorption in the skin as compared with interior of the body and higher energy with higher penetrating power than soft X-rays. Higher the tube voltage higher would be energy and hardness of X-ray generated. Quality of X-rays and tube voltage relation is as follows:-

Radiation	Tube Voltage
Very Soft	< 20 KV
Soft	20-60 KV
Semi Soft	60-150 KV
Hard	150-400 KV
Very Hard	400-3000 KV
Ultra Hard	>3000 KV

Thus if tube KV is constant the intensity of X-rays generated is proportional to the Cathode current which is expressed in Milli-Ampere (mA) but if the cathode current remains constant an increase in tube voltage will bring an increase in intensity of emission.

### X-Ray Tube

Earliest X-ray tubes were cold Cathode gas tubes. It consists of glass having partial vacuum and small amount of gas. X-rays are produced by applying high voltage across terminals caused by ionization of gas in the tube and release of streams of electrons which strike to anode and x-rays are produced. It has following disadvantages.

- 1) No control by changing KV and mA so difficult to control quantity and quality.
- 2) No heating of cathode terminals
- 3) Presence of gas produced blackening of tube, thus shortening of its life.

A typical x-ray tube is a hot cathode diode tube consisting of a tungsten filament cathode, and



a tungsten target anode in a evacuated glass tube and two circuits to heat the filaments and to drive the space charge electrons from cathode to anode . This was invented by W.D. Coolidge 1913.

## Cathode

A tungsten filament measuring 0.2 cm in diameter and 1 cm in length is used as cathode, can give copious supply of electrons by thermionic emission at temperatures where there is very little evaporation of metal atoms into the vacuum.

Upto a certain limit increase in voltage, temperature of the filament increases resulting in liberations of more electrons.

The filament is supported by two stout wires which also connect it to the source of electricity. The filament is surrounded by metal cup of molybdenum which provides an electric field that exercises focussing action on the electron beam.

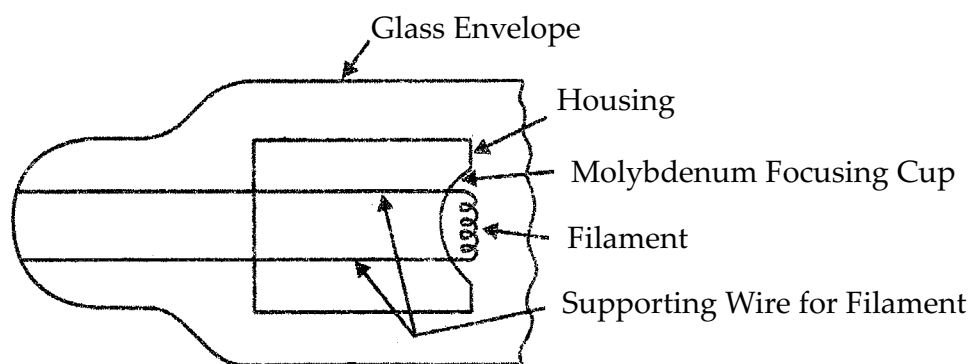


Fig. 2.7.1: Details of the cathode of X-ray Tube

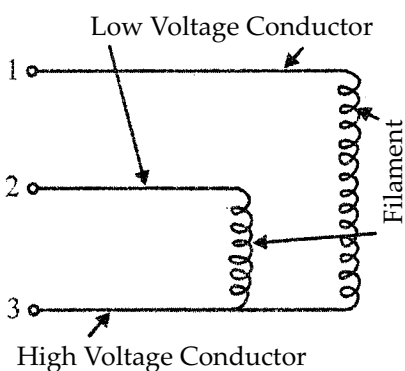


Fig. 2.7.2: Diagram showing two filaments of an X-ray Tube (Double Focus Spot Tube)



Most modern tubes have dual filament assembly with each having its own cup, thus providing two spots of different sizes. Usual filament current used 3-5 A° and it works at 10 volts.

## **Anode**

Electrons provided at cathode are stopped at Anode to produce X-rays. The material for anode should have :

1. High conversion efficiency for electrons into X-rays, so metal of high atomic number should be used.
2. High Melting Point.
3. High Specific heat and thermal conductivity.
4. Low vapour even at high temperature so that atoms are not built at its surface.
5. Suitable mechanical properties for construction purposes.
6. Tungsten with an atomic number of 74 and melting point 3370°C met most of these requirement. Thus tubes are of two types

a) **Stationary Anode Tubes** :- In this target is in the form of button of tungsten set in the block of copper, having very high heat storage capacity and conductivity for efficient dissipation of heat.

b) **Rotating Anode tubes**

Modern machines have anode Tungsten – Rhenium alloy (5% - 6% Rhenium) which prevent development of cracks in the anode. To decrease the cost, molybdenum is used as the basic material on which a layer of tungsten Rhenium is coated. The target in rotating anodes is a strip mounted on a disc (diameter of 7.5 - 12.5 cm) which is made to rotate at high speeds of 2700-3000 rpm so that larger space of target, is bombarded by electron beam.

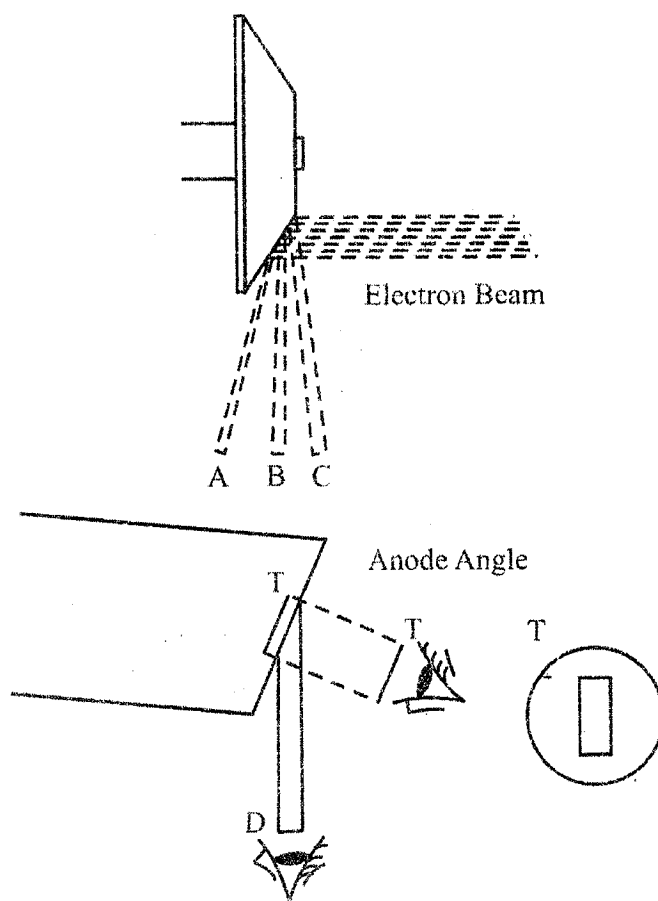


Fig. 2.7.3 (a) & (b) : Rotating Anode

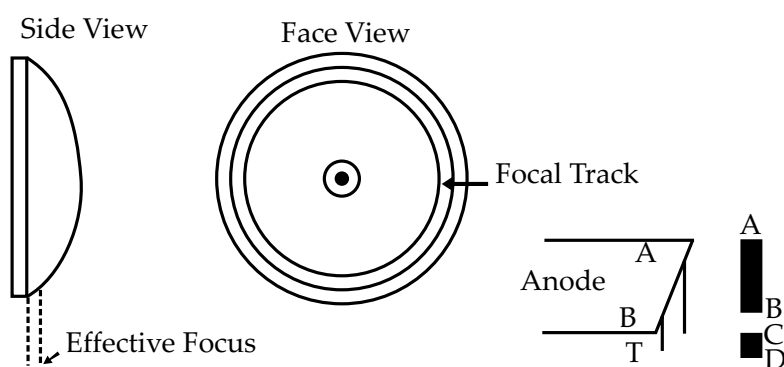
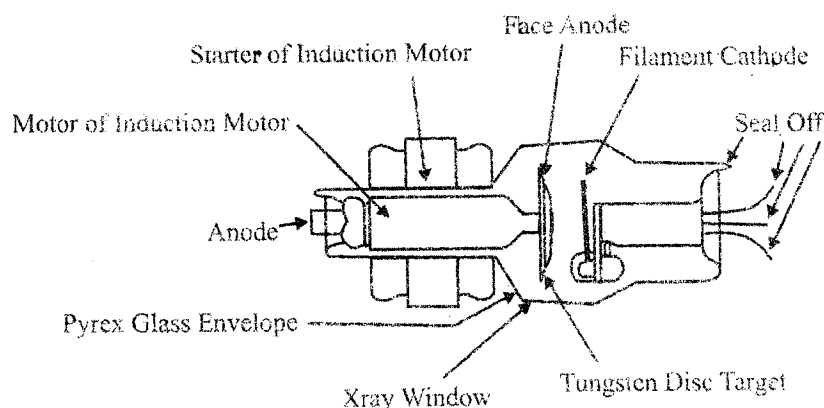


Fig. 2.7.4: (a) Line Focus (b) Line Focus Principle with a rotating anode .

The anodes of radiographic tubes are constructed on the “line focus principle” to provide a focus which when projected towards the film is smaller than it’s actual area on the target.



**Fig. 2.7.5: Rotating Anode X-Ray Tube**

Use of this principle provide large area of actual focus so that heat produced by bombardment of electrons produce less damage to anode and for sharper image it provide smaller focal spot (apparent focus)

The inclination of target face is usually  $10^\circ$ ,  $12^\circ$ ,  $17^\circ$  and is called as the anode angle.

Rapid rotation of anode is a matter of technical difficulty as anode rotates in vacuum and hence no lubrication. Lubricating grease introduced in a vacuum would produce gas, thus destroying vacuum. Now a days self- lubricating metal ball bearing are used which ensures smooth rotation. There is stator and rotator which makes anode steady and rotates it respectively.

### Glass Envelope and Housing

The anode and the cathode are enclosed in a borosilicate pyrex glass envelope containing a perfect vacuum as possible. Gas from the tube is removed by degassing. The envelope is cylindrical and has a window where the glass is thinner, permitting the x-rays to leave through them.

The x-ray is housed in a metal lined with lead except at window.

- 1) It shields against strong x-rays.
- 2) It contains anode rotation power resources.
- 3) Through it pass the terminals for filament and tube circuit.
- 4) It contains cooling oil for heat dissipation.
- 5) Oil also prevent high voltage spark between the terminals.
- 6) Provides an attaching surface for collimators.

### Production of X-Rays

X-rays are produced by sudden stoppage of fast moving electrons. So X-ray tube is a device



for obtaining free electrons (heating filament at cathode). Then spending them up (by applying potential difference across cathode and anode) and finally stopping them (at anode). In addition to these basic processes, the electrons must also be concentrated on a small area of the anode known as the focus (by placing a negatively charged collar surrounding the filament).

## Process of X-Ray Production

### Bremmstrahlung Radiation

As negatively charged electrons approaches the strongly positive nuclear fields of a target atom, they are deviated from its initial path because of the attraction between these opposite charges. As a result, the electron is slowed down or decelerated. In slowing down, the electrons loses some of its kinetic energy, the lost kinetic energy being radiated as an x-ray of an equivalent energy, called bremsstrahlung or braking radiation. Berms radiation is heterogeneous, that is non uniform in energy and wavelength because the amount of deceleration varies among electrons according to their speed and how closely they approach the nucleus. The deceleration of electrons also depend on atomic number of the target. Thus targets of higher atomic number are more efficient producers of brems radiation.

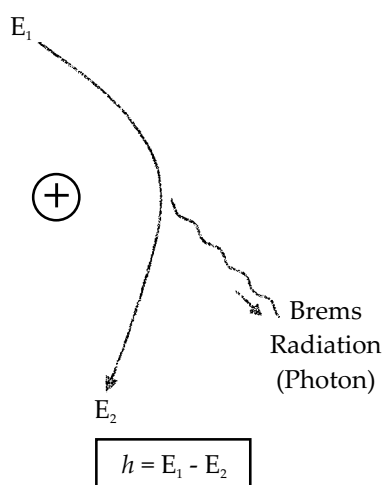


Fig. 2.7.6: Production of Bremsstrahlung (brems radiation).

An electron with energy  $E$ , on approaching an atomic nucleus experiences an attractive electrostatic force which causes it to change direction along curved path. In changing direction the electron radiates energy  $h$  which must come from the kinetic energy of the electron. Therefore the electron moves away from the nucleus with energy  $E_2$  the radiated brems photon energy  $h = E_1 - E_2$

### Characteristic Radiation

An electron with a sufficient minimum kinetic energy may interact with an innermost orbital electron ( for example in K or L shell ) of a target atom, ejecting it from it's orbit. The atom is now





unstable, being ionized and in an excited state. Immediately the space or hole vacated by the electron is filled by an electron dropping into it from one of the outer shell. A particular amount of energy difference between two orbits is released as a characteristic x-ray.

In diagnostic range 70 % emitted x-rays are bremsstrahlung radiation and about 30 % are characteristic radiation.

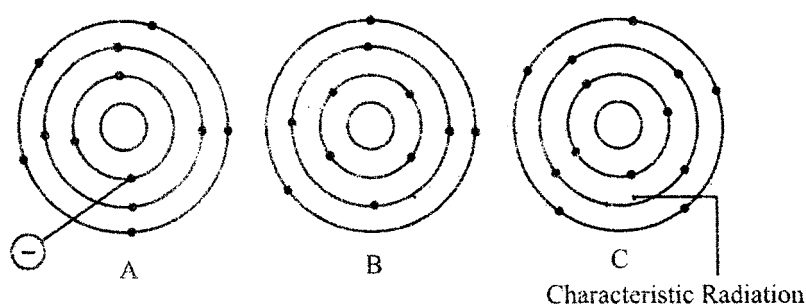


Fig. 2.7.7: Production of Characteristics radiation

- The incoming electrons collides with inner Shell electron
- The atom is in excited state. Electron A now being displaced from it's shell.
- Electron jump from outer most shell to replace electrons. This is accompanied by characteristic radiation

### Method of Heat Dissipation

Only a part of kinetic energy of the electrons ( 0.1 % at 200 KV and 4 % at 30-40 Mev ) is converted to x-rays and rest is transformed to heat, which would raise the temperature of anode from where heat dissipates. Various methods of heat dissipation are:-

- Fenestration** : Anode is connected to a large metal of considerable heat capacity. It is used in fluoroscopy tube which conducts heat outside and is cooled by outside air.
- Fan** : is used in low and medium therapy tubes to cool the anode,
- Water Cooling** : used in therapy tubes.
- Oil Cooling** : used in both diagnostic and therapy tubes.

### Tube Failure

#### Common Causes :-

- Extremely high voltage
- Burnt out filament
- Anode melting
- Puncturing of glass tube, gas enters the tube, obstructing flow of electrons
- Scarring of glass tube by electrons



Factor governing tube life and steps to extend useful tube life :-

1. Application of large filament current (resulting into high temperature) shortens filament life by evaporation and its thinning. Evaporated tungsten deposited on the glass envelope. To prevent this, boot preparation time should be kept as short as possible.
2. Instantaneous ratings as derived from tube rating charts should never be exceeded.
3. Anode should be warmed up before being subjected to a large load. Heat produced on a cold anode caused uneven expansion producing cracks on the anode disc.
4. The life of the bearings in a rotating anode tube has shortened so anode should not be run unnecessarily.
5. Excessive temperature of oil in the tube housing may shorten tube life . therefore, adequate cooling of the tube housing must be provided.

### What have you Learnt

In this lesson you have learnt about

- ◆ Properties of X-rays
- ◆ X-ray tubes
- ◆ Glass envelope and housing
- ◆ Production of X-rays
- ◆ Method of heat dissipation
- ◆ Tube failure

### Review Questions

- Q 1. Who discovered X-ray and when?
- Q 2. What is the wave length of X-ray used in diagnostics radiography?
- Q 3. What is the percentage of characteristics X-rays over total X-ray produce at about 100 KVP?
- Q 4. Write one advantage of a rotating X-ray tube over stationary tube?
- Q 5. What is range of target angle used in X-ray tube?
- Q 6. Which material is used for lubricating ball bearings in X-ray tube?
- Q 7. Who and how X-ray were discovered?
- Q 8. What are roentgen rays?
- Q 9. What is relation between frequency and wavelength of X-ray?
- Q 10. How do soft X-ray differ from hard X-ray?
- Q 11. What are properties of X-ray?
- Q 12. Discuss the construction of modern X-ray tube



- Q 13. Discuss the production of X-ray
- Q 14. What is the principle of line focus? How it is useful in maintaining the good quality of radiographs.
- Q 15. Write about brems and characteristics radiation.
- Q 16. Discuss method of heat dissipation?
- Q 17. Write causes of the tube failure.
- Q 18. Why Tungsten material is used in Anode
- Q 19. Filament of an X-ray is made up of tungsten why?
- Q 20. What is ranges of Filament current and voltage used in the X-rays tube?



## Chapter-8

# Interaction of X-Rays with Matter

### Introduction

When a beam of X-rays incident on a patient, some of X-rays pass through patient while rest of them may interact with the patient. Those X-rays that pass through the patient are said to be primary transmitted x-rays photons. In the previous lesson you have learnt about components of X-ray tube, X-ray production, dissipation and tube failure. In this lesson you will learn about various interaction processes of X-rays and their application in diagnostic radiography.

**Objective – After reading this lesson you will be able to :**

- ➡ Describe various interactive processes of X-rays with matter.
- ➡ Recognize the parameters that increase /decrease dose of X-rays.
- ➡ Develop skills in applying interactive process in diagnostic radiography.

### Interaction of X-Ray

The transmission of X-rays results from two factors:-

- 1) X-rays are electrically neutral and so there is no electric force between them and orbital electron.
- 2) Atom consisting empty space.

Those X-rays that interact with patient may have number of post interactions. So, X-ray beam undergoes attenuation i.e. reduction of number of primary photon in a beam of radiation. This reduction is caused by absorption and scattering of primary photon. Photon that interacts with an atom of the medium and loses all its energy to atom. This process is known as absorption. The absorption of X-ray photon results in secondary radiation comprised of characteristics X-rays emitted after having absorbed X-ray photon.

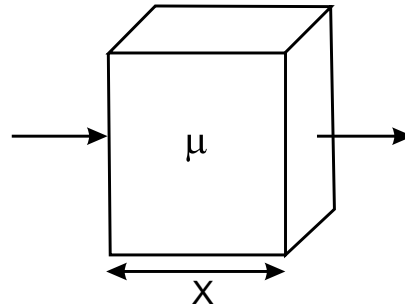
Photon that interacts with an atom of medium and is deflected from its path. This deflection may or may not be associated with loss of X-ray energy. This process is known as scattering. So scattered radiation refers to those X-ray photons that have undergone change in direction after interaction with atom.

Transmitted radiations are important in diagnostic radiology. Suppose a mono energetic beam of X-ray passes through a material of thickness  $x$ . Then :  $I_x = I_0 e^{-\mu x}$

Where  $I_0$  is initial intensity of X-ray beam and  $I_x$  is transmitted intensity of X-ray beam and  $\mu$  is linear attenuation coefficient.



Unit of linear attenuation coefficient is  $\text{cm}^{-1}$ . The linear attenuation coefficient is the fraction of X-ray removed from a beam per unit thickness of attenuating medium, if  $\mu = 0.01/\text{cm}$  then 1 % X-ray in the beam will interact in each 1 cm layer of absorber. Its value lies between 0 and 1. In Fig. (2.8) it is seen that X-rays are attenuated exponentially.



**Fig. 2.8.1: Radiation Attenuation.**

As a beam of radiation of intensity  $I_0$  passes through an object of thickness  $x$ , it is reduced in intensity according to the law of exponential attenuating, governed by the equation.

The following are main points :-

- 1) More value of  $\mu$  means more X-rays will be attenuated or more X-rays will be removed from beam.
- 2) In diagnostic range, linear attenuation coefficient decreases with increasing energy of X-rays.
- 3) Linear attenuation coefficient increases with increase in density of material.
- 4) Variation of  $\mu$  with atomic number is complex but it clearly increases quite sharply with atomic number at low energy.

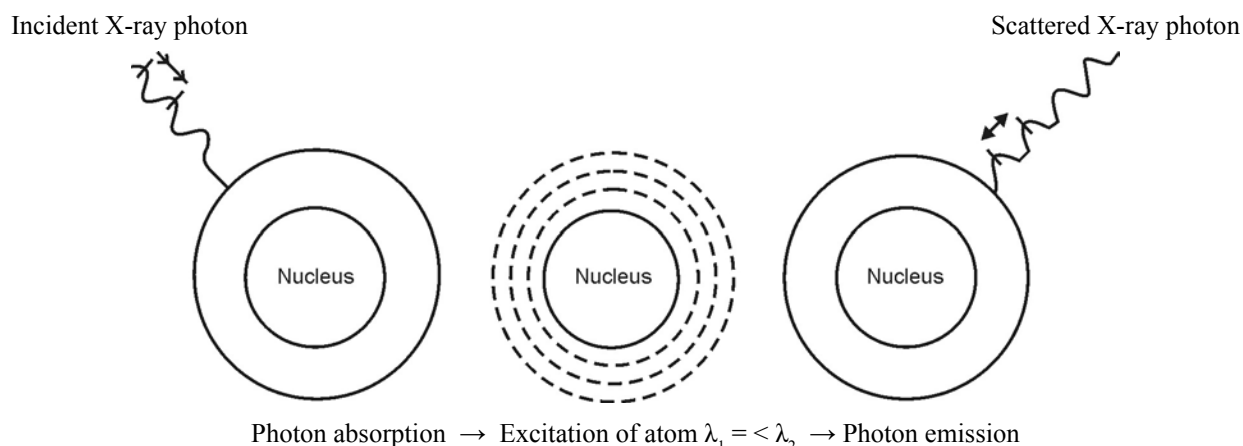
### Interaction Process

There are five types of interaction that may occur between X-rays and atoms of absorbing material:

- a) Coherent Scattering
- b) Photoelectric Absorption
- c) Compton Scattering
- d) Pair Production
- e) Photo Disintegration

### Coherent Scattering

In this type of interaction when X-ray photon having energy less than about 10 keV, may undergo change in direction without any change in their wavelength.



**Fig. 2.8.2: Coherent Scattering**

A low energy photon is absorbed by the atom resulting in excitation. The excited atom quickly releases a photon with energy equal to that of the incident photon.

As shown in Fig. 2.8.2 when low energy X-ray interact with relatively bound electrons and they may set electrons into vibrations. The process is one of resonance such that electrons vibrate at a frequency, corresponding to that of an X-ray photon. This unstable state and electrons radiates this energy (vibrating electron, since charged particle, emit radiation in all directions and at exactly the same frequency as incoming photon).

Therefore process may be thought of as absorption of radiation by electron, vibration of atom as whole and atom return to its original state by scattering the radiation in all direction without any absorption. This is the only process that does not cause ionization.

Its only effect is to change the direction of incident radiation. Linear attenuation efficient of coherent scattering :  $\mu_{coh} \propto \frac{Z^2}{E}$

Where Z is atomic number and E is energy of X-rays

In medical radiography, the effect of scattering can be largely ignored. Since effective atomic number of tissue is low and photon energy is too high to allow significant interaction. Its contribution in diagnostic radiology is about 5 % at 70 kV of total interaction.

### Disadvantage

- 1) It produces scattered radiation which can contribute to film fog but that contribution. is too low.

**Photoelectric Absorption :** At lower energy of diagnostic range of photon energies, photoelectric effect is dominant process. The type of interaction is most likely to occur when energy of incident photon is slightly greater than the binding energy of inner most shell like K or L shell. So when the incident X-ray photon with little more energy than binding energy of K shell electron, photon encounters with one electron of K shell and transfers all its energy of the electron in a single





event. In others words incident photon is completely absorbed by the atom and therefore that electron is ejected out from its orbit leaving a hole in the K – shell. Now atom is ionized with an electron vacancy on the K shell. The ejected electron is called photoelectron.

**Now that energy of incident photon ultimately was to :**

- 1) Free the electron from its shell.
- 2) Set this free electron in motion which moves in free space as photo electron Most of the photon's energy is used to overcome the binding energy of K shell electron and rest energy is transferred to the electron in the form of its kinetic energy and therefore photoelectron moves in space with this kinetic energy.

The following is the equation which describe the energy exchange:

$h\nu =$	$w +$	$\frac{1}{2} m_e v_e^2$
Energy	Binding energy	Kinetic energy
incident	of K shell electron	of photon electron
rays	photon	

These photo electron while moving in absorbing material may ionize other atom in their path but they carry low energy, so they are immediately absorbed in the material because charge particle have little penetration. For example at 100KV photon release, in soft tissue a 99.5 KeV photoelectron which is absorbed in only 1 mm of tissue.

Now the ionized atom with a vacancy in k shell is in completely unstable state so atoms immediately comes to ground state because an electron jump from higher energy state to fill up the vacancy in K shell. This electron usually comes from adjacent level e.g. L shell, occasionally from M shell and rarely from outer shell of the same atom or other atom.

Now since an electron jump higher energy state into vacant hole, the transition takes place and difference of energy between two shell is radiated in the form of X-ray called characteristic X-rays because amount of energy is characteristic of each element Now when an outer shell electron of same atom fills K shell vacancy, then outer atom becomes a positive ion.

Thus photoelectric effect yields:

1. photoelectron,
2. Positive ion (ionization), and
3. characteristic X-rays or secondary radiation

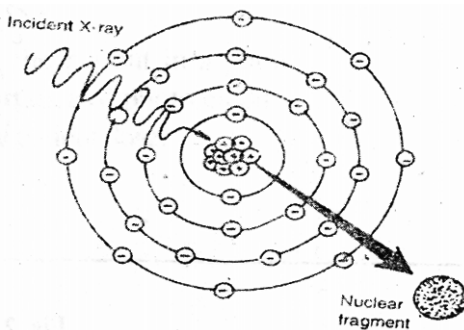


Fig. 2.8.3: Photoelectric  $\lambda_1 < \lambda_2 < \lambda_3 < \lambda_4$

### Probability of occurrence

1. The Photoelectric interaction can not occur unless incident X-ray has energy equal or greater than the binding energy of electron e.g. a barium K shell electron bound to the nucleus by 37.4 keV cannot be removed by 25 keV X-ray.
2. The photoelectric reaction most likely to occur when photoenergy is just equal or slightly greater than binding energy of K shell electron. For example 34 keV X-ray photons are much more likely to react with K shell electron of iodine than 100 keV. If the incident X-ray has sufficient energy, the probability that it will undergo a photoelectric effect decreases with the third power of photon energy.
3. The probability of photoelectric interaction is directly proportional to the third power of atomic number of absorbing material. If means tighter an electron is bound, in orbit, the more likely it is to be involved in a photoelectric reaction.

### Application to diagnostic radiology

#### Advantages

Photoelectric type of interaction results in radiographic image of excellent quality because of two reasons:

1. PE absorption does not produce scatter radiation.
2. It enhances natural tissue contrast.

Since the probability of interaction is proportional to the third power of atomic number, so PE magnifies difference in tissue composed of different atomic number such as bone and soft tissue. For example soft tissue and barium have different atomic numbers. So relative probability of photoelectric interaction with Barium would be

So probability of an X-ray will undergo P.E. absorption is approximately  $\left(\frac{56}{7.4}\right)^3 = 433$ , times greater in Barium than in soft tissue. Hence photoelectric enhances the tissue contrast.



### Disadvantages

Since all energy of incident photon is absorbed by the patient in a photo electric reaction. So patient dose is higher. The importance of photo electric can be minimized by using high KV technique to reduce patient dose.

### Features of photo electric effect

Most likely to occur:

- ◆ when interaction with inner most shell electron
- ◆ when interaction with tightly bound electron
- ◆ when X-ray energy is just higher than the binding energy of K shell electron.

As energy of X-ray increases:

- ◆ less probability of P.E. effect.
- ◆ increased probability of penetration through tissue without interaction

As atomic number of absorber increases:

- ◆ probability increases with cube of atomic number.

As density of absorber increases:

- ◆ proportional increase in X-ray absorption.
- ◆ more photoelectric effect

### Compton Scattering

in 1929, A.H. Compton was first to predict this type of interaction. In this type of interaction, an incident photon having moderate energy strikes with an outer shell electron of an atom and eject an electron from its orbit. The photon is deflected by an electron so that it travels in a new direction as scattered photon. Thus compton reaction produces an ion pair, a positive atom and a negative electron known as recoil electron.

The energy of scattered photon is equal to difference between energy of incident X-rays and energy of ejected electron because no energy is required to remove an electron from its outer shell as binding energy of these electron is almost nil.

Usually scattered X-ray retain most of its energy, but the scattered X-ray and secondary electron may have sufficient energy to undergo more ionizing interaction before losing all their energy.

Ultimately, the scattered X-ray is absorbed. The secondary electron loses all its kinetic energy by ionization and excitation. It then drops into a vacancy in an electron shell previously created by some ionizing event.



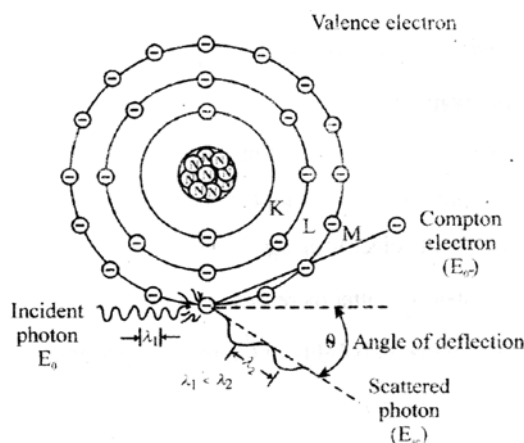
## Direction of scatter

Compton scattered X-rays can be deflected in any direction and photon angle may as great as 180 (back scattering) however, electron angle is constrained to be in range of 0 to 90°. However in diagnostic range distribution is more symmetric.

As the photon energy increases, scattered photon travel increasingly in the forward direction but this is quite small in the diagnostic range where a significant proportion of X-ray may be scattered back.

Thus at deflection angle of 0 degree, no energy is transferred to electron and scattered photon retains almost all energy of incident X-ray photon.

When  $\theta=180^\circ$  more energy is transferred to recoil electrons. Even at 180-degree deflection photon retains about 2/3rd. of its original energy. The back scattered X-rays from tissue or object immediately behind the cassette can cause artifacts such as cassette-strap image. As scattered photon retain over 2/3rd of initial energy they create serious problem in diagnostic radiology because these photon have excellent chance to reach upto X-ray film and produce film fog. These scattered photon are extremely difficult to be removed from beam even after use of grid and other technique so an image of degraded quality has to be accepted.



**Fig. 2.8.4: Compton Scattering**

Secondly these photon poses major radiation hazard problem especially in fluoroscopic examination as these photon are as energetic as primary photon so they can pass through the patient and can reach up to personnel working near the patient.

## Probability of Occurrence

Probability of Compton interaction decreases as the quantum energy of photon increase. But since, when an electron are subjected to force of other atom low energy interaction frequently do not give the electron sufficient energy to break away from these other forces. Thus in practice Compton attenuation is approximately constant in diagnostic range and being to decrease for photon energy above about 100 Ke V.



Compton reaction does not depend upon the atomic number of absorbing material.

The Compton effect is proportional to number of electrons in the stopping material which in turn depends on the density of absorber.

### Features of Compton scattering

Most likely to occur:

- ◆ with outer shell electron
- ◆ with loosely bound electron

An X-ray energy increased:

- ◆ reduced probability of Compton effect
- ◆ increased probability of Compton scattering
- ◆ relative to photo electric effect

As atomic number of matter increases:

- ◆ No effect on the probability of Compton scattering

As Mass density of matter increases:

- ◆ more Compton scattering

### Pair Production

If an incident X-ray has sufficient energy, it may escape interaction with the electron shells and come close enough to the nucleus of the atom to be influenced by the strong electrostatic field of nucleus. In its place appear two electrons, one positively charged, called positron and one negatively charged electron (Fig. 2.8.5). The energy equivalence of the mass of an electron is calculated to equal 0.51 MeV. Since two electrons are formed in a pair production interaction, the incident photon must have at least 1.02 MeV is distributed equally between two electron as kinetic energy. With this kinetic energy positron and electron moves inside the tissue, before positron comes to rest position it combines with an electron emit two gamma photon emitted in opposite direction with equal energy of 0.51 MeV.

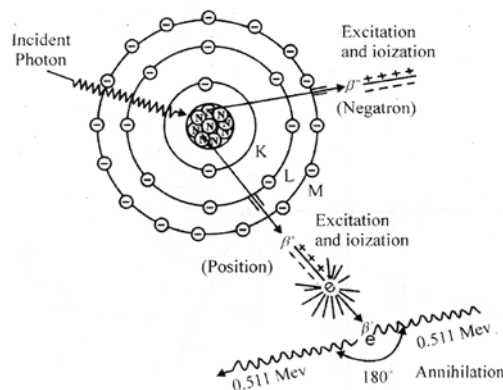


Fig. 2.8.5: Pair Production





Because pair production involves only X-ray with energies greater than 1.02 MeV, it rarely occurs in the diagnostic X-ray range.

### Photo Disintegration

Very high energy X-ray, those with energy above 10 MeV, can escape interaction with electrons and the nuclear electrostatic field and be absorbed directly by the nucleus. When this happens, the nucleus is raised to an excited state and instantaneously emits a nucleon or other nuclear fragment. This process is called photo disintegration. Because it involves only X-rays with energies greater than approximately 10 MeV, photo disintegration, like pair production do not occur in the diagnostic X-ray range.

### Combining effect and their relative importance

Each of the process occurs independently of the others. Hence effect can be combined simply multiplying the exponentials to give:

Leading to simple relationship

Relative frequently of basic interaction

**Table 8.1: Per cent of different type of interaction**

Radition Energy (KeV)	Water			Compact bone		
	Coh.	p.E.	Compton	Coh.	p.E.	Compton
20	8	62	30	4	80	16
60	6	8	86	7	32	60
100	3	5	92	3	23	74

### Application to diagnostic radiology

Differential attenuation: Of the five way an X-ray can interact with tissue, only following two occur in diagnostic radiology: (1) Compton effect (2) the photoelectric effect. The Compton effect results in no diagnostic information reading the film. The photo electric effect result in X-rays that are completely absorbed.

These X-ray photon that pass through the body without interacting produce the X-ray image.

Now when photon enters a patient with uniform distribution and emerge in a specific pattern of distribution.

The transmitted photon carry the X-ray image, but their pattern also carries the memory of the attenuated photons. The transmitted and attenuated photons are equally important. If all photons were attenuate, the film would be uniformly white. In neither case would thereby an X-ray image.





Image formation depends upon different absorption between tissue. Some tissues absorb more X-ray than other tissues and size of this differential determines the amount of contrast in the X-ray image.

Production of a high quality radiograph requires the proper selection of KVP so that the effective X-ray energy results in maximum differential absorption. Because when absorption increases the KVP is reduced, KVP results in increased patient dose. An optimum KVP is used to provide a compromise between absorption and penetration based on atomic number of the tissue.

In radiograph of an extremity, an image of bone is produced because many more X-rays are absorbed photoelectrically in bone than in soft tissue since probability that an X-ray will undergo a photoelectric interaction is approximately seven times greater in bone than in soft tissue.

The relative probability of interaction between bone and soft tissue may remain constant. Whereas absolute probability of each decreases with increasing energy. With higher X-ray energy, fewer interactions occur, and then more X-rays are transmitted without interaction.

Compton scattering of X-ray is independent of atomic number of different tissue. The probability of Compton scattering for bone atoms and soft tissue atoms is about equal and decreases with increasing X-ray energy. This decrease in probability of Compton, however, is not as rapid as that occurring with photoelectric absorption.

At low energies the majority of X-ray interactions are photoelectric. At high energies, Compton scattering predominates. As KV is increased, chances of any interaction at all decrease more X-rays are transmitted so lower mAs is required.

### **Image Produced by Contrast Media**

Contrast Media used to produce image contrast to the surrounding tissues. Most commonly they are used intravenously but for many diagnostic studies they can also be used intra-arterially, orally and intra – abdominally

Basically Contrast Media are of two types

1. Negative contrast Media
2. Positive contrast media

#### **1. Negative Contrast Media**

The only negative contrast materials are gases such as Air or Oxygen or carbon-di-oxide. Air filled parts are shown in the radiographic image of an ordinary X-ray film as black areas because more amount of Radiation can pass through the gases hence black images are produced and on fluorescent screens as light areas.



## 2. Positive Contrast Media

Positive contrast Media/Agents are all substances of light atomic numbers which absorb X-ray Radiation therefore in the Radiographic images of X-ray film, they make structures in which they are present appear light in contrast to the surrounding tissue because less radiation is reaching the film to blacken it.

Elements of high Atomic number which are used to make these preparations are

- Barium
- Iodine

### K-edge effect in contrast media image

The absorption characteristic of Iodine and Barium for the reason it is used to produce positive contrast is the high efficiency of X-ray absorption. The positive contrast is obtained when the photon energy of the X-ray beam is close to but slightly above the K-absorption Edge of the absorber.

For Iodine the K-Absorption edge is at 33.45 keV ( $Z=53$ ). The K-Absorption edge of Barium is at 37.4 keV ( $Z=56$ ).

The attenuation of X-ray decreases below and above the K-edges and has relative Maximum immediately above the K-Absorption edge.

### Barium as Contrast Media

Barium has a high Atomic Number 56 with a k-EDGE AS 37.4 Kev. It is insoluble and stable and will pass through the intestinal tract without dissolving or changing to harm any to the patient. Salt of Barium other than Sulphate are Highly poisonous.

Barium Sulphate is supplied commercially as white powder and maybe prepared for use in X-ray department by mixing with water until desired consistency as per the part required is achieved.

It is available both in powders as well as in suspension form.





Iodine is the basic component of all currently used Intravascular Contrast Media. Atomic No is 52 and K=Edge binding energy is 33.7 which is close to the mean energy used in Diagnostic Radiography thereby maximizing the photoelectric interactions.

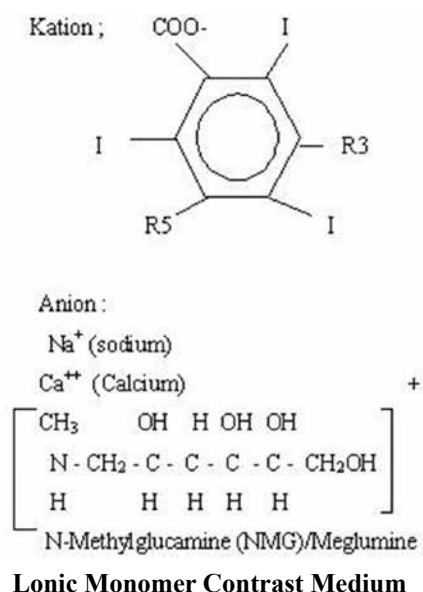
All intravascular iodinated contrast agents are based on a tri-iodinated Benzene ring. They are of the following types-

1. Ionic Monomers (**HO**CM-High Osmolar Contrast Media)
2. Ionic Dimers(**LO**CM-Low osmolar Contrast Media)
3. Non-ionic Monomers(**LO**CM Low osmolar Contrast Media)

Nonionic dimer (Iso-osmolar Contrast Media)

The toxicity of the contrast agents decreases as osmolality approaches that of serum (290 mosmol/kg H<sub>2</sub>O)

### Ionic Monomers



Also called HO

CM (High Contrast Media) are the oldest agent. They are relatively inexpensive, but their utility is limited. Also benzene ring that ionizes in solution with valence of -1. Their Cation is either Sodium or Meglumine.

It has particle ratio 3-2 in which 3 represents the number of iodine molecules and 2 represents the number of solute particles generate in the solution.

Eg, Urograffin-375, Urograffin-290,

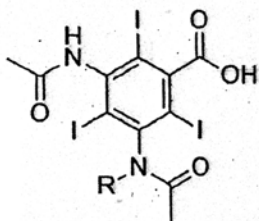
Contrastin, 76,60

Conray-280,325,420



## Nonionic Monomers

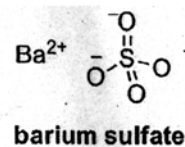
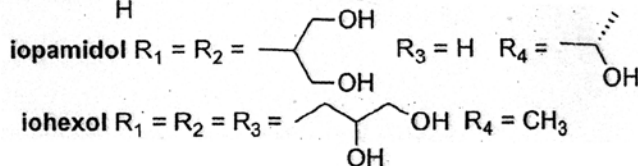
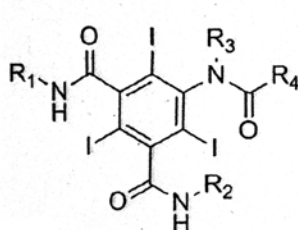
### ionic contrast media



**diatrizoic acid** ( $R = H$ )

**metrizoic acid** ( $R = CH_3$ )

### non-ionic contrast media



In nonionic monomers solubility is replacement of the carboxyl group with an organic molecule passing sufficient hydrophilic group to keep the agent in solution.

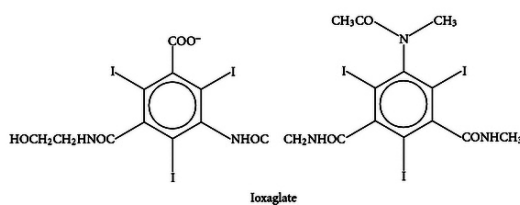
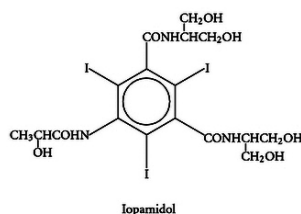
This is achieved by replacing Carboxyl group by a D-glucose group which provides many Hydrophilic Groups.

There are 4 main non contrast agents

1. Iohexol (Omnipaque)
2. Iopamidol (Niopam/Iopamidol)
3. Iopromide(Ultravist)
4. Iversol (Optiray)

Particle ration is 3:1 contain 3 atoms of iodine and a single solute partied represents in the solution per molecule of the contrast. These agents possesses lover toxicity in a number of application such as carotid and conray angiography

## Ionic Dimers





These agents were developed to improve the radio density of the contrast agents while the osmolality remain the same.

Two tri-iodinated benzoic acid group are joined in a linkage bridge resulting dimeric acid. Each of these molecules contain 6 iodine atoms while the low solute particles are generated in the solution. Thus these agents can also be – doubled – 6:2 agent or a ratio 3:1. An improvement over the ionic monomers ioxaglic acid, which is a mixture of sodium and meglumine salts in one such agents and marked as Hexabrix.

It reduces the osmolality.

### Nonionic Dimers

The most recent class of agents is non-ionic dimers that consists of a molecule with two benzene rings. Particle ratio 6:1 that does not dissociate in water (Nonionic). These compounds are designated iso-osmolar contrast media.

e.g. – Iotrolon (isovist)

Iodixanol (Vispaque)

### Rare Earth Materials

Rare earth materials are alkaline earths transition elements and not metals. The term “RARE EARTH” developed because these elements are difficult and expensive to separate from the earth and each other not because the elements are scarce.

The rare earth groups consist of the elements of Atomic Numbers.

Lanthanum (Z=57) through (Lutetium (71+71) and included Thulium (Z=69) Terbium (Z=65)

**Gadolinium(64), Europium(63)**, because Lanthanum is the first element, the rare earth group is also known as the Lanthanum Series.

Lanthanum (La) and Gadolinium (Gd) are used in the rare earth phosphors. The rare earth Phosphors are produced as crystalline powders of Terbium – activated gadolinium Oxy-Sulfide ( $Gd_2O_3:Tb$ ) and Thulium-activated Lanthanum Oxybromide ( $LaOBr:Th$ )

### The advantages are

1. Rare earth Screens/materials are more efficient at absorbing X-ray photon (Higher absorption efficiency) or quantum detection efficiency.
2. They are more efficient at converting X-ray photons to light photon (conversion efficiency)

### Use of Activators

Rare earth materials/ Phosphorus are invariably used in conjunction with activator which is small quantities of some foreign elements added to the phosphor during manufacture. The choice of





phosphor-activator combination not only determines the intensity of luminance obtainable from the screen but also the color of the light emitted.

### Common Rare Earth Phosphors and Activators

	Phosphorus	Activator	Emission
1.	Gadolinium Oxysulphide	Terbium	Green
2.	Lanthanum Oxysulphide	Terbium	Green
3.	Yttrium Oxysulphide	Terbium	Blue
4.	Yttrium Tantalate	Niobium	Blue
5.	Lanthanum Oxybromide	Thulium	Blue

### Shielding Material used in Radiology

The radiation like X-Ray have the property of ionized the matter which means create positive and negative ions.

After the discovery of x-rays (1895) the injurious effects of ionizing radiation were recognized this radiation along with beneficial effects also create radiation hazards to the patient's staff and surrounding environment.

The degree of harness of radiation depends upon the degree and length of the radiation exposure that also create the biological hazards.

Lead:- Lead having atomic number 82 and k-edge average is 88. O kev. Because lead having bigger alternations coefficient and secondary radiation but also now a day Tin also to be used as radiation absorber. But for low energy radiation its gives to lighter weight to the accessories for radiation protection.

Its protection from the scattered radiation but commonly lead is suitable shielding option for energies encountered in diagnostic x-rays.

Also AERB would like to promote use of these materials on demonstration of shielding adequacy.

Following explanation and reference data on shielding of Radiology department.

### Radiology and Fluoroscopy

Shielding Material	Distance from Center patient table	
Brick (cm)	(1.5)	(2.0 m)
	23	20
Lead (cm)	0.17	0.15





## Computed Tomography

Shielding Material	Distance from ISO center			
	1.5m	2.0m	2.5m	3.0m
Brick (cm)	27	25	23	20
Concrete (cm)	18	15	13	12
Lead (cm)	0.21	0.18	0.15	0.14

Shielding Material	Distance from Center patient table	
Gypsum Wallboard (cm)	(1.0 m)	(1.5 m)
	1.5	1.0
Concrete	1.0	1.0
Brick	1.5	1.0

### Use of protective device

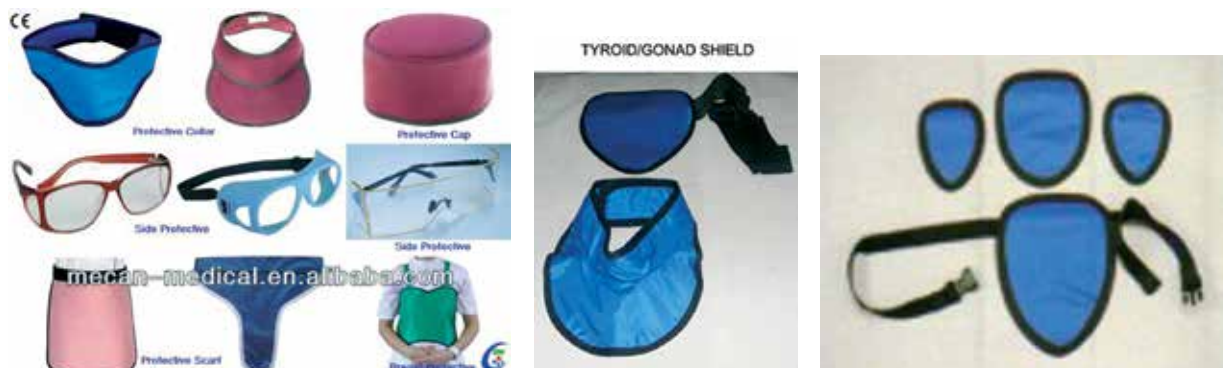**Protection Barriers:-** 150 KV and above control panel locate in a separate room the lead thickness should be 1.5 mm equivalent of lead.

**Viewing Window of lead glass 1.5 mm of lead equivalent.**

**In Fluoroscopy:-** The screen should be backed by lead glass having lead equivalence of 1.5 mm of lead up to 70 KV and 2mm and should be increased by 0.01 mm for each KV. The protective flaps of 0.50 mm lead equivalence the thickness of lead approve should be in range. 0.25 to 3 mm of lead equivalent the thickness of radio protective device accessories is to be 0.25-0.2mm lead equivalent.

Eg. Gonad shield, thyroid, lead gloves 0.25 mm of lead equivalent.

### Radiation protective accessories:





## Chapter-9

# Scattered Radiation and Methods to Reduce it and Grids

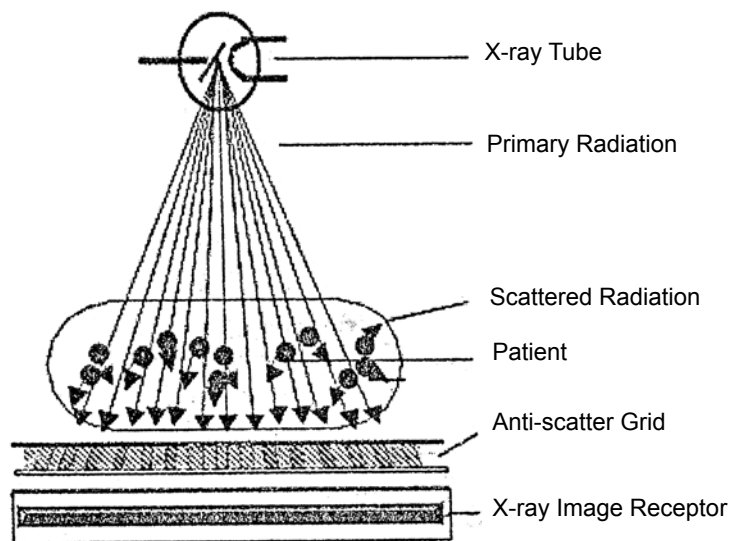
### Introduction

In earlier chapter were discussed Compton process and associated scattered x-rays which have enough energy to pose a radiation hazard problem to the staff handling X-ray machine especially in fluoroscopy. Also, these scattered radiation when reach to the film produce unwanted fog and therefore reduces contrast of the image. One of the efficient method of reducing scattered x-rays is Grid. In the previous lesson you have learnt about interactive process. X-rays, parameters that increase/decrease dose of x-rays. In this lesson, you will learn about scattered radiation, various parameters used in grid and its design.

**Objective – After reading this lesson you will be able to :**

- ➡ discuss the construction of grids
- ➡ describe the parameters related to the grid.

Grid was invented by Dr. Gustave Buckley in 1913 and is still the most effective method of removing scattered radiation from radiographic field. It consists of series of lead foil strips separated by X-ray transparent spaces. The whole is enclosed in an aluminum outer covering (Fig. 29.1 a and b)



**Fig. 2.9.1 (a): Grid having on parallel lead strips separated by wider inter space material whole is enclosed in metal outer covering.**

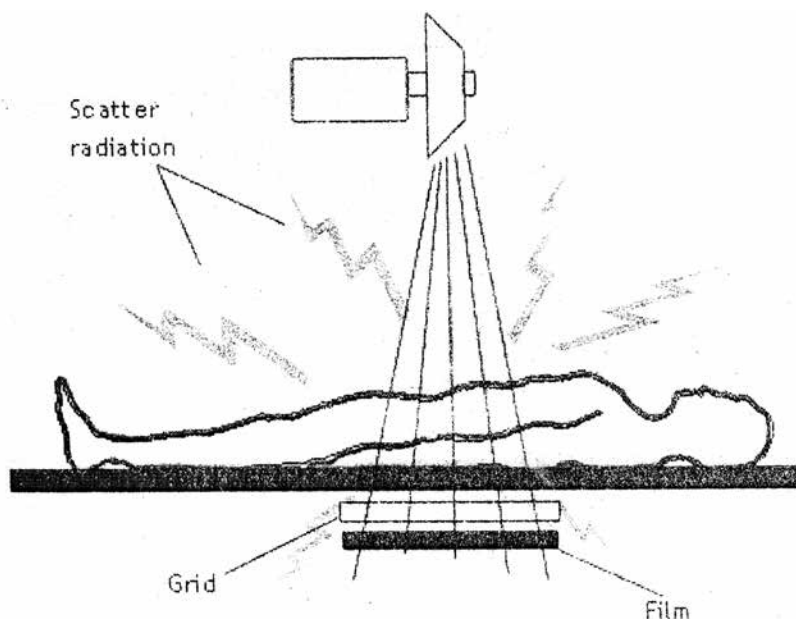


Fig. 2.9.1 (b): Primary photons pass through grid while scattered radiation is stopped by the grid.

Scattered radiation arises from many points within the patient and is multi directional and so most of its (about 80-90%) is absorbed by lead strips and thus the contrast.

### Grid Parameter

Grid Ratio is the ratio of the height of lead strip and distance between them (interspace). Grid ratio is a parameter widely used to express the grid's ability to remove scattered radiation.

Grid ratio =  $h/d$  (from Fig. 2.9.2)

Grid ratios from 4:1 to 16:1 are available and most units have the facility of interchangeability of grids. A low ratio grid is used for low KV work and high grid ratio is used for high KV or production of large amount of scatter. Result of higher grid ratio is higher patient dose.

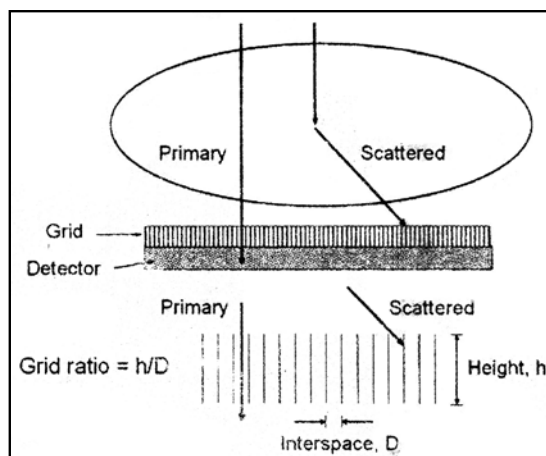


Fig. 2.9.2: Showing lead strip and interspacers



Grid lattice is the number of lead strip per centimeter or inches measured across the grid. Grid with higher grid lattice or grid frequency show less distinct grid lines on a radiograph than grid with low frequencies. Most grids have frequencies in the range of 60 to 110 lines/inches or 25-45 lines/cm.

Grid frequency in lines/inch =

Where  $d$  = thickness of lead strip (in mm)

$D$  = thickness of interspace ( in mm)

Grids designed for mammography have Grid ratio of 2:1 to 4:1. These low grid ratio have grid frequencies of approximately 200 lines/inch or 80 lines/cm.

### Grid types

1. Stationary grid
2. Moving grid

### Stationary Grid

These are three main type of grids; parallel grid, focused grid and cross grid.

#### Parallel Grid

In this type of grid, fig. 2.9.3 lead strip separated by radiolucent space are positioned parallel to one another. The parallel grid is frequently used in conjunction with rebile unit for radiography in the ward or theatre. The focus-grid distance is not critical but is should not be too short as peripheral cut off increases as the focus grid distance decrease. Centering is also not critical provided grid is positioned under area of interest.

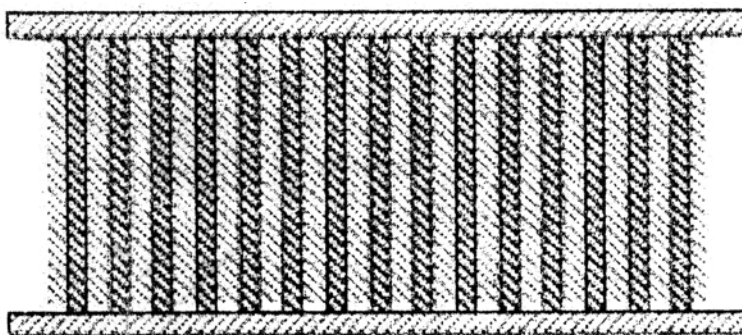


Fig. 2.9.3: Parallel Grid

The grid should not be tilted transversely otherwise there will be marked cutoff on oneside. Following points should be noted when using a stationary parallel grid.

1. Use a relatively long focus – grid distance particularly when using a large field of radiation.





2. Limit the field size as far as possible.
3. Do not angle beam of radiation into strip.

### Focused Grid

The focused grid is composed to strips of lead angled towards the edge as shown by 2.9.4 Focused grids designed in this manner are used to minimize problem of grid cut off. Every focused grid is marked with its intended focal distance and side of grid that should face the X-ray tube.

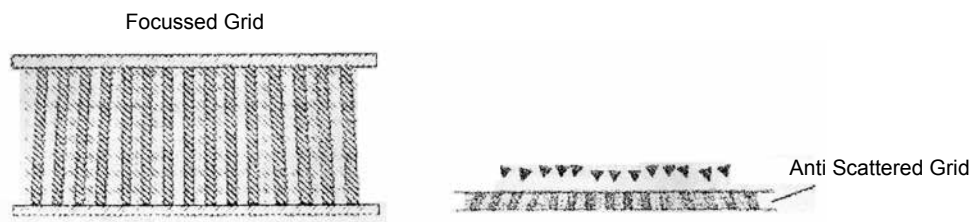


Fig. 2.9.4: Showing focused grid and convergent line

### Cross Grid

Linear grid cleans up scattered radiation in only one direction, which is along the axis of grid. Cross grids are made to overcome this problem. These grids consist of two parallel or focused grids placed at right angle to one another. In fact a cross grid has higher contrast improvement factor than a linear grid. A 6:1 cross grid will clear up more scattered radiation than 12:1 linear grid.

There are two disadvantages to using cross grid:

1. Positioning of grid is critical (central ray of X-ray beam must coincide with the centre of grid).
2. Tilt table technique is possible if tube and table are properly aligned.

### Moving Grid

While stationary grid absorbs scattered they also record a pattern of thin grid lines on the radiograph. Grid lines appear on radiograph when primary X-rays are absorbed in the grid strips. Even though the grid strips are very small, their images are still observable.

A major improvement in grid development occurred in 1930. Hollis S. Potter on a very simple idea to move the grid when X-ray exposure is being made.

A device that moves grid during exposure is called Potter bucky grid.

Moving grids are usually focused grids.

### The Grid Cassette

While the stationary grid may be used by simply placing it on the cassette, it is possible to obtain



cassette in which the grid is fitted as an integral part. While the grid cassettes are very convenient in use, if a number of exposure houses have made. E.g. in ward or theater. Since fewer scattered X-ray interact with the film contrast is enhanced.

## Scattered Radiation

The scattered Radiation travels in various direction contrary to primary radiation which travels in straight line. As primary beam passes through the patient, some of it is absorbed while the rest it scattered in various directions. In the diagnostic range, most of it is produced by Compton interactions while some are characteristic radiation resulting from photo electric interaction.

As scattered radiation does not travel in a straight line, it causes degradation of the image. In a good quality radio graph, less than one fourth density should result from scattered radiation. It increases with an increase in the area of radiation field, thickness and density of the part and with an increase in tube potential (KV).

Methods to reduce scattered radiation:

1. Careful Choice of beam parameters
2. Compression of the part.
3. Air gap techniques
4. Use of grids
5. Use of proper intensifying screen and film combination.

## What have you Learnt

In this lesson you have learnt about

- ◆ Grid & its parameters
- ◆ Grid types
- ◆ Scattered radiation

## Review Questions

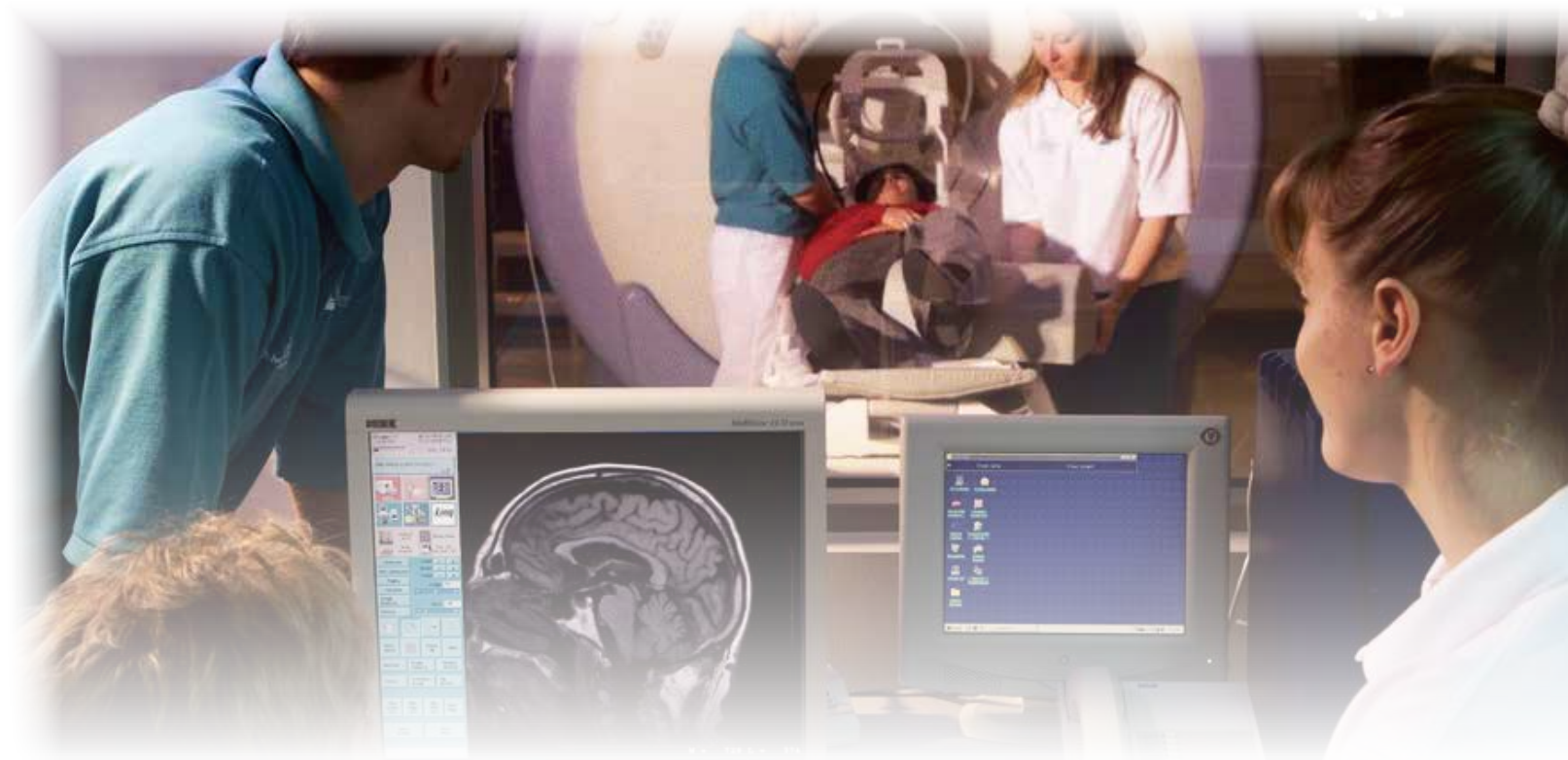- Q 1. Who invented grid?
- Q 2. How a grid is designed?
- Q 3. Write the range of grid ratios used in radiology
- Q 4. Define grid frequency in lines/inch?
- Q 5. What are the advantages of focused grid?
- Q 6. Compton effect predominates at low voltage or high voltage?
- Q 7. Does the patient get more radiation after Compton effect?
- Q 8. What is the impact on the quality of image due to Compton process?





## MODULE - V

# *Regional Radiography, Special Procedures and Contrast Media*





## Chapter-1

# General Principles of Radiography and Positioning and Terminology in Radiography

**Objectives – After studying the chapter the student will be able to :**

- ➔ Understand the positioning terminology
- ➔ Understand the projection terminology
- ➔ Practice radiography of different body parts
- ➔ Apply principles of positioning in emergency radiography
- ➔ Apply principles of positioning and handling the paediatric population.
- ➔ Discuss about mammography

## General Principles of Radiography and Positioning and Terminology in Radiography

### General Principles of Radiography

#### According to positioning

- ◆ Remove any artifacts (extraneous jewelry) from the area of interest;
- ◆ Explain the procedure to patient;
- ◆ Use immobilization techniques if required (mainly in children);
- ◆ Give instructions to hold breathing & withhold motion to avoid repeat exposures;
- ◆ Advice fasting & purgatives in patients for LS spine & KUB.
- ◆ Use appropriate Film size : 8x10", 10x12", 11x14"
- ◆ Use Grids (if required)
- ◆ Proper use of markers is essential
- ◆ Film Focus Distance (FFD) should be 100 cm except in a chest X-Ray PA view where FFD is 180 cm
- ◆ Try a gentle approach towards children to make them cooperative. With respects to radiation protection
- ◆ Use of gonadal & breast shield (if they do not interrupt the area of interest)
- ◆ Ask about last menstrual period (LMP) or any missed period, if female of reproductive age group is the patient.



- ◆ Use of PA projection instead of AP in skull radiography to protect eyes.
- ◆ Radiation should be “As Low As Reasonably Achievable” - use of ALARA principles.

### Positioning and Projection Terminology

Radiography involves acquiring a plain radiograph of a specific region for diagnosis of various pathologies causing anatomical and morphological changes detected on radiographs. For obtaining good quality radiographs proper positioning, exposure factors, proper placement of identification number and side is essential.

X-ray technician should be well versed with regional radiography of the various parts and be aware of the important anatomical planes, sites & lines. They should also be aware of the general principles of radiography, proper positioning techniques and projection radiography.

### Positioning Terminology

This deals with the position of patient related to film/cassette.

1. Supine (Dorsal decubitus) – lying on the back.
2. Prone (ventral decubitus) – lying face down.
3. Lateral decubitus – lying on the side (right or left).
4. Erect – Standing.

Positions related to patients are described in the following order

1. Antero Posterior – supine or standing with posterior aspect in contact with cassette or film.
2. Direction of rotation – e.g. right or left side raised or moved away from table.
3. Degree of rotation with respect to the median sagittal or coronal plane.

### Projection Terminology

Projection is described by the direction of central ray relative to surface and planes of the body.

Direction and centering of x-ray beam are given by an imaginary central ray of x-ray beam.

Antero posterior (AP) – Central ray is incident on anterior aspect, passes along transverse plane and along or parallel to median sagittal plane and emerges from the posterior aspect.

Postero-anterior (PA) – Central ray is incident of posterior aspect, passes along a transverse plane and along or parallel to the median sagittal plane and emerges from anterior aspect.

Lateral – Central ray passes from one side of the body to the other along a coronal and a transverse plane. The projection is called left lateral if central ray passes from right to left side. For limbs the term medio-lateral or latero-medial is used.



Anterior oblique – The central ray enters the posterior aspects-passes along a transverse plane at some angle to median sagittal plane and emerges from the anterior aspect.

## 1) Skull Radiography

The skull is a complex bony structure in the head which supports the structures of the face and forms a cavity for the brain. The skull is composed of two parts: the cranium and the mandible. The skull is a part of the skeleton.

## Anatomical Terminology

### Lines

**Interorbital (interpupillary) line** – joins the centre of two orbits or the centre of two pupils with eyes looking straight.

**Anthropological base line (Anatomical baseline or Reid baseline or Frankfurt line)** – From the lowest point of inferior orbital margin to upper border of external auditory meatus.

**Auricular line** – Perpendicular to anthropological base line in coronal plane and passing through external auditory meatus.

**Orbitomeatal baseline (Radiographic baseline)** – From outer canthus of eye to centre of external auditory meatus lying at about  $10^\circ$  to anthropological base line.

### Planes

**Orbitomeatal plane** – contains the two-orbitomeatal baseline and is inclined at 10 degree to anthropological base line.

**Anthropological plane** – Horizontal plane containing both anthropological base lines and infra orbital line.

**Auricular plane** – Perpendicular to anthropological plane passing through centre of external auditory meatus. The median sagittal, anthropological and coronal planes are mutually at right angles.

### Points

- ◆ Nasion – Frontonasal articulation, bony prominence above it is glabella.
- ◆ External occipital prominence – Prominence on occipital bone inferiorly.

### General principles for Skull Projection

- ◆ X-ray of the skull are done on a specialized skull unit, however a bucky table can also be used.



- ◆ If a general bucky or erect bucky is used, the central ray cannot be angled across the grid plate. It is therefore necessary to rotate the patient's head to obtain various projection.
- ◆ Before examination all extraneous objects (like ornaments), hair pins should be removed from head and neck, Hearing aids are removed only after necessary instructions have been given to the patient.
- ◆ Whenever possible postero – anterior projections are used over Antero-posterior projection to avoid excessive radiation dose to the lens.
- ◆ To bring median sagittal plane at right angles to film check that external auditory (or outer canthus) are equidistant from film. To bring median sagittal plane parallel to film check that inter orbital line is at right angle to film.

### X-ray Skull - Lateral View

**Positioning** – Patient on table in semiprone position with side of head under examination in contact with table with median sagittal plane parallel to table. The inter orbital line should be angle at right angle to table with the nasion and inion in the same place and equidistant from the table.

Cassette is placed transversely in the bucky tray with its upper edge 5cm above the vertex.

**Centering** – Vertically midway between glabella and external auditory meatus.

#### Lateral (Supine)

**Positioning** – It is taken with x-ray beam horizontal while using skull table. Even with general x-ray table it is recommended to take supine cross table lateral view using a stationary grid with cassette vertical against the side of head. It is essential to take radiograph in his manner is cases of head injury.

The grid cassette is placed longitudinally supported vertically against the lateral aspect of the head parallel-to median sagittal plane with its long edge 5cm above vertex of skull.

**Centering** – Directed parallel to inter orbital line centered midway between the glabella and external occipital protuberance.

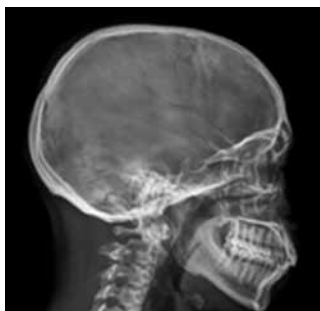

Fig. 1: X ray skull lateral view





## Occipito-Frontal

**Positioning** – Prone patient is centered to midline of table with nose and forehead in contact with table, neck is flexed bringing the orbitomeatal line at right angles to table and head are adjusted to bring both the external auditory meati equidistant from the cassette.

**Centering** – To the glabella, the tube angled 5° towards feet to show petrous bone in orbits or 20° towards feet to project petrous bone below the level of orbits.

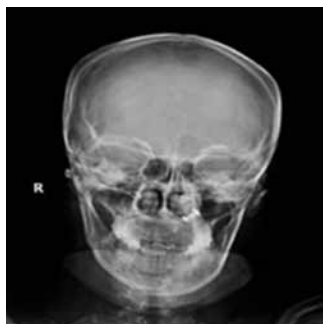

Fig. 2 (a)

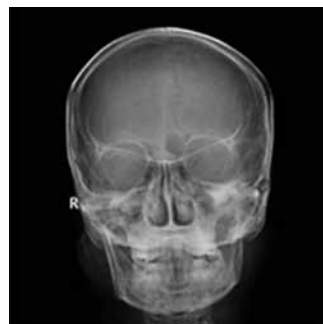

Fig. 2 (b)

Fig. 2: Skull PA (occipito frontal view) with a) 5 deg and b) 20 deg caudal angulation

## Fronto-occipital 30° Caudal (Townes')

**Positioning** – Supine with chin depressed so that orbitomeatal line is at right angles to table. Cassette is placed longitudinally in a bucky tray with its upper edge at level of the skull vertex.

**Centering** – Central ray makes an angle of 30° to the orbitomeatal plane and is directed to pass midway between external auditory meatus.

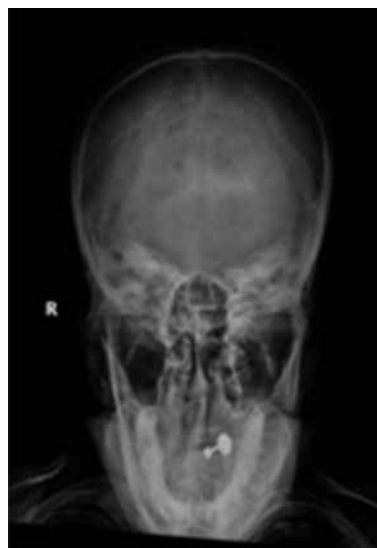

Fig. 3: X ray Skull Townes view





### Submento-Vertical (Base of Skull)

**Positioning** – With the patient supine on the table, shoulders and raised on the pillows and neck hyper extended to bring vertex touching the table and baseline parallel to table.

External auditory meati should be equidistant from table. Orbitomeatal plane should be as near as possible to film.

**Centering** – Midline between angles of jaw/ external auditory meatus, with the central ray at angle of  $90^\circ$  to the base line or orbito meatal line.

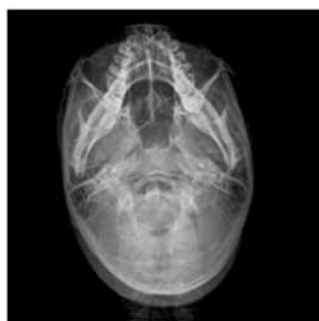


Fig. 4: X ray skull- basal view

### Sella Turcica

**Positioning** – of the patient and film is same as for skull lateral view.

**Centering** – 2.5cm above and 2.5cm in front of external auditory meatus.

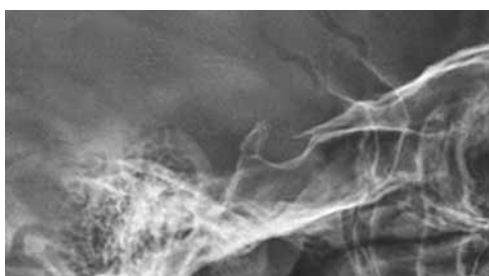
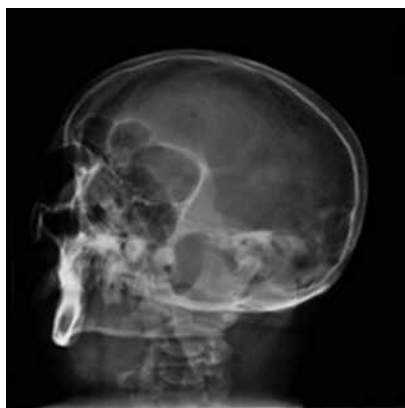

Fig. 5: X-ray skull lateral view for sella turcica

### Optic Foramina

**Positioning** – Patient prone with nose, cheek and chin of side being examined in contact with table. Orbit's is centered over central line of the Bucky. This can be obtained by rotating the head about  $35^\circ$  so as to bring the mid-sagittal plane and orbito-meatal line at  $35^\circ$  to the vertical or both lines  $55^\circ$  to the table.

**Centering** – 7.5cm above and 7.5cm behind external auditory meatus remote from film so that the central ray emerges from the center of the orbit in contact with table.

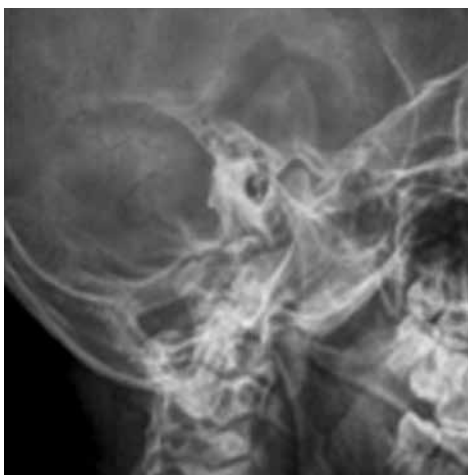

**Fig. 6: X ray – optic foramen**

### **Mastoid - Lateral 25° Caudal (Schuller's View)**

**Positioning** – patient lies prone or faces vertical bucky. Head is turned sufficiently to one side. Auricle adjacent to table is folded forward. Head is adjusted so that median sagittal plane is parallel to table and anthropological base transverse to it. External auditory meati vertically superimposed are in midline of table.

**Centering** – 25° caudally from anthropological plane, centered to a point along the auricular line, 5cm above external auditory meatus remote from the film.



**Fig. 7: Schullers view for mastoid**

### **Petrous bone - Occipito frontal 10° (per orbital view)**

**Positioning** – Patient prone or sitting. Nose and forehead are in contact with table. Neck is flexed and chin depressed to bring orbito meatal line at right angles to table.

**Centering** – midline of the head at the level of external auditory meatus and outer canthus so that ray passes along orbitomeatal plane.

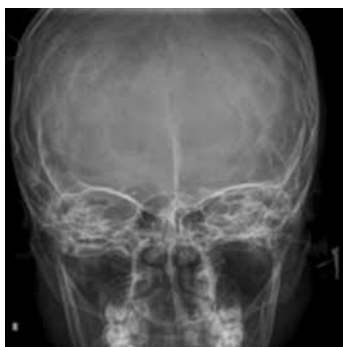

Fig. 8: Per-orbital view

### Anterior oblique (Stenver's view)

**Positioning** – Prone in position' with middle of supra-orbital margin on the side being examined centered to table. Nose and forehead touch the table and orbitomeatal line is perpendicular to film.

Neck is now extended so that orbitomeatal line an angle of  $5^{\circ}$  to vertical and head is rotated  $45^{\circ}$  to the side examined.

**Centering** – midway between occipital protuberance and external auditory meatus remote from with central ray angled  $12^{\circ}$  cephalad i.e. 7 degree to orbitomeatal plane.

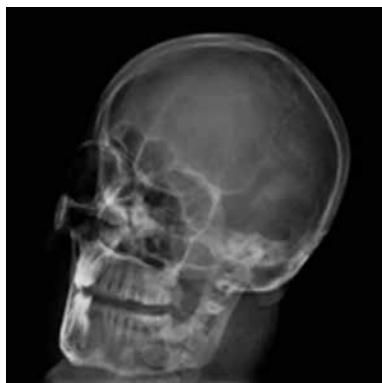

Fig. 9: X-ray skull- Stenvers view

## Para Nasal Sinuses

### Lateral

**Positioning** – Patient sitting with side of head against vertical bucky, which is held by the arm of opposite side. The median sagittal plane is brought parallel to film and interorbital line is at right angles to bucky.

**Centering** – Horizontal ray is at 2.5cm posterior to outer canthus of eye along the orbitomeatal line.

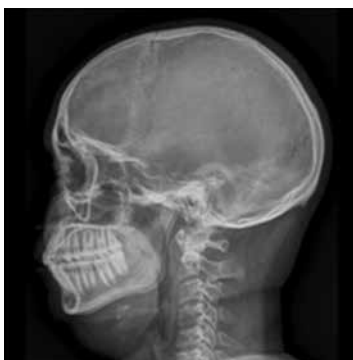

Fig. 10: PNS – lateral view

### Postero-anterior

**Positioning** – Patient faces the table in nose chin position. The orbitomeatal lines made  $45^\circ$  to horizontal and centre of bucky at the level of lower orbital margin. Open mouth view allows good display of sphenoid sinus as well.

**Centering** – midline above external occipital protuberance to emerge at the level of lower border of orbits

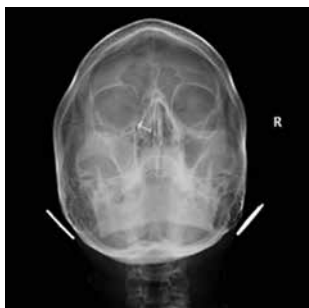

Fig. 11 (a): X Ray PNS

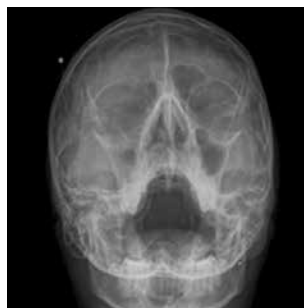

Fig. 11 (b): X-Ray PNS- Open mouth

## Occipitomenal-Facial Bones

### Occipitomenal $30^\circ$ Caudal

**Positioning** – Patient faces erect bucky table with the chin and nose in contact with the midline of the bucky. Then head adjusted to bring orbitomeatal line at  $45^\circ$  to the horizontal, which is the direction of central ray. Centre of the bucky is at the level of lower orbital margin.

**Centering** – Towards midline at level of lower orbital margin with central ray caudally  $30^\circ$  towards feet.

### Lateral view- Face

**Positioning** – Patient sits or lies supine with erect bucky lying against the side of head. Median sagittal plane is parallel to film and inter orbital line is at right angles to it.



**Centering** – Horizontal central ray is directed to a point 2.5 cm inferior to outer canthus of eye.

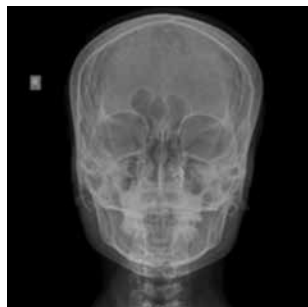

Fig. 12: X-Ray Face- PA view

## Orbits

### Occipitomenal (modified)

**Positioning** – Patient faces bucky table with nose and chin in contact with it. Head is adjusted to bring orbitomeatal line at 35° to horizontal, which is the direction of central ray.

**Centering** – X-ray directed perpendicular midline at the level of lower orbital margins.

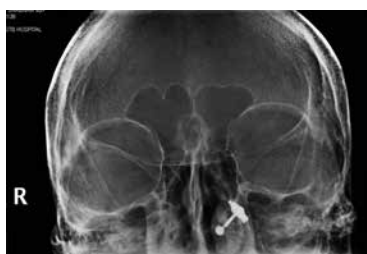

Fig. 13: X-Ray Orbits- PA view

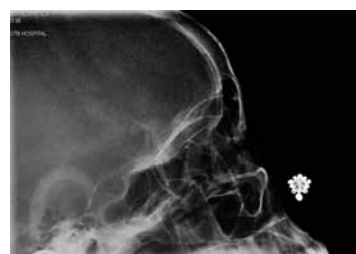


Fig. 14: X-Ray orbit-Lateral view

### Nasal Bone

**Positioning** – Side of patient's head lies against the cassette with median sagittal line parallel to it. Either a high-resolution screen film system or a non-screen film at the top of bucky is placed. The film is centered to nasal bone.

**Centering** – Through the centre of nasal bone with beam perpendicular to film. Beam is collimated to include the nose

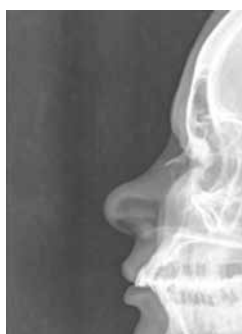

Fig. 15: X-Ray-Nasal bone



### Nasal Bones – Supero-Inferior Occlusal

**Positioning** – Patient lies supine with occlusal film lying one third of its length in the mouth and two thirds out side it. The long axis of the film lies along median sagittal plane of head. The tube side of film faces cranially.

**Centering** – In midline directed along a line joining glabella and upper central incisors.

### Mandible

#### Postero-Anterior (Basic)

**Positioning** – Patient sits or lies prone facing bucky table with nose and forehead touching bucky, Neck is flexed to bring orbitomeatal line 'at right angles to table. Cassette placed longitudinally centered at the angle of the mandible.

**Centering** – Midline perpendicular to film, at the level of angles of mandible. A central ray angled 10 degree cranially is used to demonstrate the mandibular condyle.

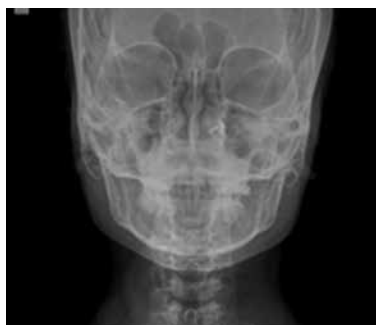

Fig. 16: X-Ray mandible- PA view

#### Mandible - Anterior oblique

**Positioning** – Patient faces bucky table with median sagittal plane and orbitomeatal line at right angles to film. Patient's head is then rotated through '20° to either side.

**Centering** – 5cm lateral to midline away from the side being examined at the level of angle of mandible.

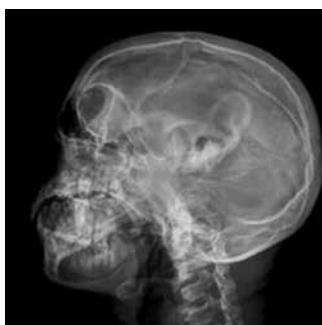

Fig. 17: X-Ray mandible- Anterior Oblique view





## Temporo-Mandibular Joint

If patient has dentures, they should not be removed before examination.

### Basic Views

#### Lateral oblique 25° Caudal

**Positioning** – Patient prone or sitting against the bucky head is turned to make median sagittal plane of head parallel to bucky and inter orbital line at right angles to it.

**Centering** – Central ray is angled 25° caudally to a point 5cm superior to joint remote from film.

Exposures are made with

1. Teeth clenched with molars in opposition
2. Mouth open fully
3. Mouth closed but teeth not clenched.

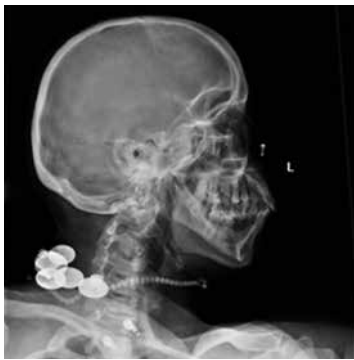

Fig. 18(a)

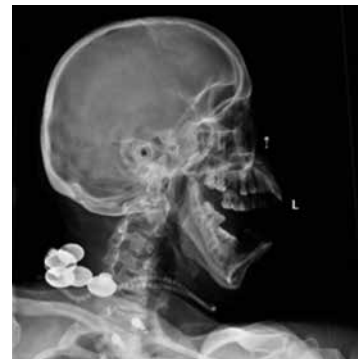

Fig. 18(b)

Fig. 18: X-Ray Temporo-mandibular Joint

a) closed mouth and

b) open mouth view

## 2) Radiography of Spine

### A) Cervical Spine

Cervical vertebrae are vertebrae immediately inferior to the skull in the neck region. Cervical vertebrae are the smallest of the true vertebrae, and peculiar from other vertebrae due to the presence of a foramen transversarium in its transverse process, through which passes the vertebral artery .

#### Radiographic Views – Basic views

1. Antero-posterior (open mouth view for odontoid process)
2. AP view



3. Lateral view
4. Right & left posterior oblique view
5. Cervico thoracic – Lateral view

### 1. Anterio-posterior view for Odontoid- Open mouth method

Positioning the patient lies supine. Chin is lowered down touching the sternum. Mouth must be opened wide.

Centering – middle of open mouth

Anatomic structure

Atlas, Axis, Odontoid process, C1 – C2 articulation

**Image criteria** – Atlas, axis & odontoid process should be seen projected through open mouth and well visualized

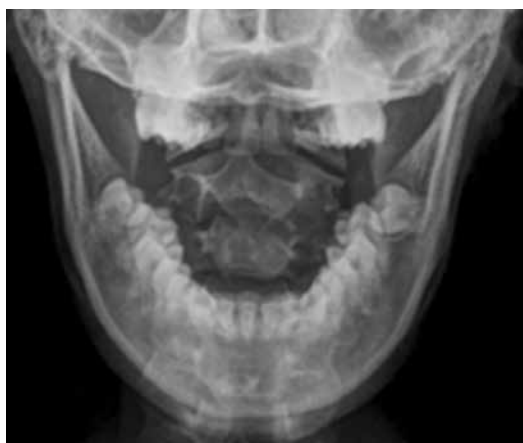


Fig. 19: X-Ray Odontoid AP view- open mouth

### 2. Cervical AP View

**Positioning** – Patient lies supine with chin raised

**Centering** – midline at the level of angle of mandible with the tube angle 15° towards head

**Anatomic structures**

1. C<sub>3</sub> – C<sub>7</sub> Vertebral bodies & Intervertebral disc spaces
2. Spinous processes

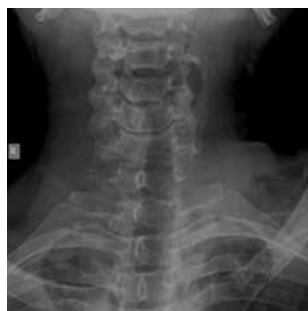

Fig. 20. X- Ray Cervical Spine- AP view

#### Image criteria

1. Base of skull to T<sub>1</sub> should be included
2. C<sub>3</sub> – C<sub>7</sub> vertebral bodies should be seen clearly without rotation with open intervertebral disc spaces.

### 3. Cervical Lateral View

**Positioning**—Patient sits in lateral position with one shoulder against the cassette. The other should be lowered as much as possible so as to avoid overlapping. Chin is raised. The cassette is so placed that its lower border is at the level of the shoulder and the upper border at the level of pinna.

**Centering** – Behind the angle of mandible

#### Anatomic structures

1. Cervical vertebral bodies and Intervertebral disc spaces
2. Posterior elements (Pillars, spinous process)

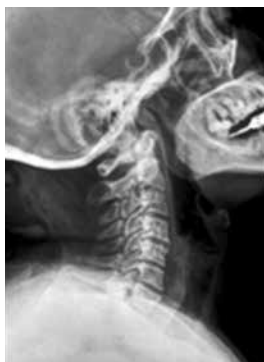

Fig. 21: Radiograph of cervical spine lateral view

#### Image criteria

1. Cervical vertebral bodies & posterior elements should be seen in lateral position without rotation.



2. Mandibular rami should be nearly superimposed & not overlie any of cervical vertebrae.

#### 4. Right and left posterior oblique – erect

**Positioning** – patient standing or sitting with posterior aspect of head and shoulder touching vertical bucky. The median sagittal plane of trunk is then rotated through  $45^\circ$  for right and left side in turn. The head is rotated so that its median sagittal plane is parallel to film.

**Centering** – Beam is angled  $15^\circ$  from horizontal and on the side nearer the tube at the level of thyroid cartilage.

#### Anatomic structure

Intervertebral foramina, pedicles all well seen with vertebral bodies and intervening intervertebral disc spaces.

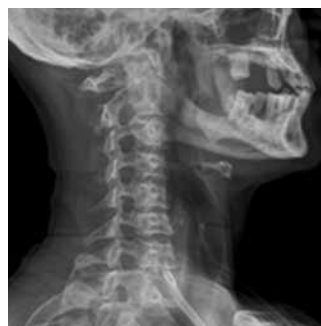
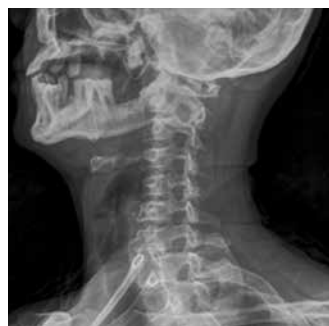
Fig. 22: Radiograph of cervical spine

a) Right posterior oblique

b) left posterior oblique views

**Image criteria** – Area from base of skull to  $T_2$  should be included with the foramina appearing circular of similar size and pedicles clearly seen. Mandibles and skull base should not overlie  $C_1$  &  $C_2$ .

#### Cervico Thoracic Vertebra

- Antero Posterior projection
- Lateral projection

#### Antero Posterior Anatomic structure

Lower cervical & upper thoracic vertebral bodies, intervertebral disk spaces and posterior elements.

#### Centering - Just above Sternal notch

A good Radio graph will show lateral projection of vertebral bodies, intervertebral disk spaces and posterior elements from  $C_5$  to  $T_6$  should be well seen with no superimposition of shoulders.



### Cervico Thoracic vertebra –Lateral view- Swimmers view

**Positioning** – patient stands with either shoulders against vertical bucky and median sagittal plane of trunk and head parallel to film. The arm are placed in the swimmers position ie, the arm near the film is raised above the head and fully extended forward while the other arm is out stretched backwards as far as possible. A point approximately 5 cm anterior to dorsal surface of upper thoracic region should coincide with midline of bucky.

**Centering** – At a level just above shoulder remote from film.

#### Anatomic structure

1. Lower cervical vertebral bodies intervertebral disc spaces.
2. Upper thoracic vertebral bodies, intervertebral disc spaces, posterior elements

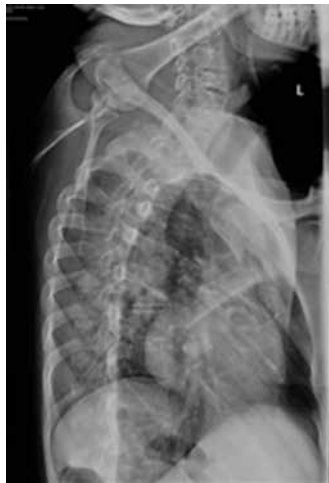

Fig. 23: Radiograph of Cervico-thoracic vertebrae Lateral view

A good image shows lateral projection of the vertebral bodies, intervertebral disc spaces, & posterior element from C<sub>5</sub> through T<sub>6</sub> with no superimposition of the shoulder region.

### B) Thoracic Spine

Thoracic vertebrae compose the middle segment of the vertebral column, between the cervical vertebrae and the lumbar vertebrae. They are intermediate in size between those of the cervical and lumbar regions; they increase in size as one proceeds down the spine, the upper vertebrae being much smaller than those in the lower part of the region

1. Antero posterior (AP View)
2. Lateral view

#### Thoracic Spine –AP view

Patient may be positioned either supine or erect, upper edge of the cassette, should be at a level just below the prominence of thyroid cartilage.



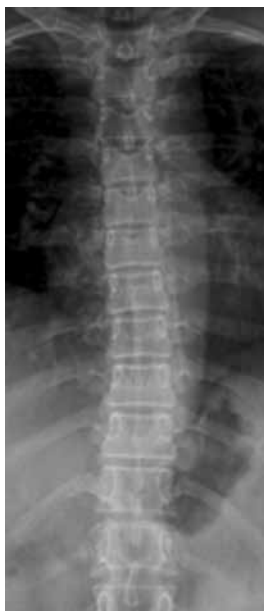**Centering** – 2.5cm below sternal angle.

### Anatomic Structure

1. Vertebral bodies
2. Posterior element (pedicles, spinous process)
3. Intervertebral disk spaces

### Image Criteria

1. All thoracic vertebral bodies & posterior elements should be seen without rotation.



**Fig. 24: Thoracic spine- Antero Posterior view**

### Thoracic spine- Lateral view

**Positioning** – median sagittal plane should be parallel to film and middle of axilla coincide with midline of table or Bucky. Arms should be raised and folded over the head. Vertebral column should be parallel to film. The upper edge of cassette should be 3-4cm above the spinous process of 7<sup>th</sup> cervical vertebra.

**Centering** – 2.5cm below sternal angle.

### Anatomic Structure

1. Vertebral bodies
2. Spinous process
3. Intervertebral disk spaces
4. Intervertebral foramina

### Image Criteria

1. Intervertebral foramina should be seen open & superimposed
2. Vertebral bodies should be seen in lateral position without rotation.



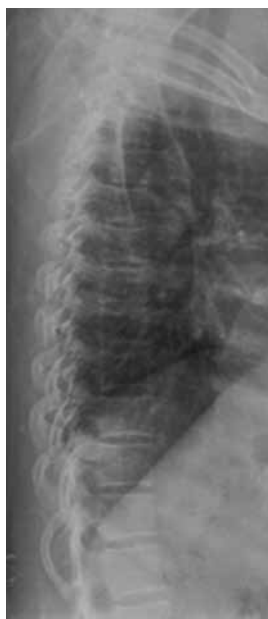

Fig. 25: Thoracic spine –lateral view

### C) Lumbar Spine

The lumbar vertebrae are the largest segments of the movable part of the vertebral column, and are characterized by the absence of the foramen transversarium within the transverse process, and by the absence of facets on the sides of the body.

#### Radiographic Views of Lumbar Spine

1. Antero-posterior view (AP)
2. Lateral view
3. Posterior Oblique
4. Lumbo-sacral junction

#### Anteroposterior

**Positioning** – With patient supine, hips and knee flexed and feet placed with planter aspect on tabletop to reduce lumbar arch. If patient is unable to do this, shoulder and head should be raised on pillow. Film should include lower thoracic vertebrae and sacroiliac joints.

**Centering** – Towards midline at the level of lower costal margin

#### Anatomic Structure

1. Vertebral bodies
2. Intervertebral disk spaces
3. Posterior elements (pedicles, spinous process, transverse process)

#### Image Criteria

1. Lumbar vertebral bodies & posterior elements should be seen without rotation.
2. Psoas muscle shadows should be visible if appropriate exposure factors are used



### Lateral view

**Positioning** – Patient lies on either side of bucky table with arms raised and folded overhead and vertebral column made parallel to film with the help of non-opaque pads.

**Centering** – To point 7.5cm anterior to third lumbar spinous process at the level of lower costal margin.

### Anatomic Structure

- |                               |                            |
|-------------------------------|----------------------------|
| 1. Spinous process            | 2. Vertebral bodies        |
| 3. Intervertebral disc spaces | 4. Intervertebral foramina |

### Image Criteria

1. Intervertebral disc spaces should be equal from  $T_{12}$  through  $S_2$ .
2. Vertebral bodies & spinous process should be seen in lateral position without rotation.

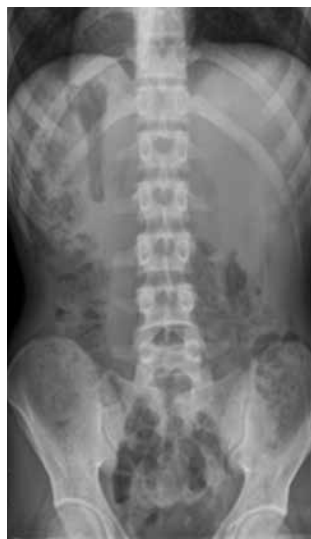
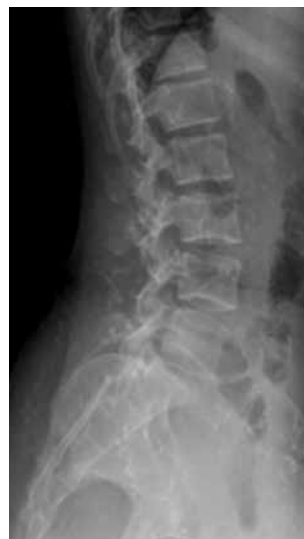
Fig. 26: Lumbar Spine- a) AP



and b) Lateral View

### Posterior Oblique View

**Positioning** – Patient supine and then rotated  $45^\circ$  to each side to turn. Hips and knees are flexed slightly.

**Centering** – mid-clavicular line on the raised side at the level of costal margin.

### Anatomic Structure

- |                      |                     |                               |
|----------------------|---------------------|-------------------------------|
| 1. Apophyseal joints | 2. Vertebral bodies | 3. Intervertebral disc spaces |
|----------------------|---------------------|-------------------------------|

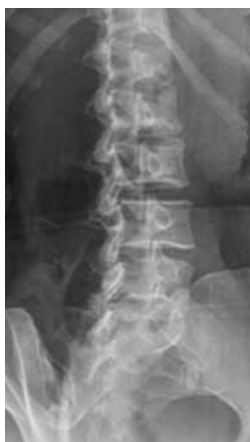

Fig. 27: Posterior Oblique View - Lumbar Spine

### Image Criteria

1. Intervertebral disc spaces should be equal from T<sub>12</sub> through S<sub>2</sub>.
2. If too much obliquity Apophyseal joints are poorly seen & pedicles appear too far posterior.

## Lumbo Sacral Junction (LS Junction)

### Antero-posterior

**Positioning** – supine with knees flexed.

**Centering** – Direct central ray 10°-25° cranially towards midline at the level of anterior superior iliac spine.

### Anatomic Structure

1. L<sub>5</sub>-S<sub>1</sub> junction
2. Sacroiliac joints

### Image Criteria

1. L<sub>5</sub>-S<sub>1</sub> junction should appear open without rotation
2. SI joint should be well demonstrated

### Lateral view

**Positioning** – patient lies on either side on the table with arms raised and folded over patients head. Hips and knees are flexed slightly.

**Centering** – points 7.5 cm anterior to L5 spinous process which is present at the level of tubercle of iliac crest and anterior superior iliac spine.



## Anatomic Structure

L<sub>5</sub>-S<sub>1</sub> junction

Image Criteria

L<sub>5</sub>-S<sub>1</sub> junction should appear open without rotation.

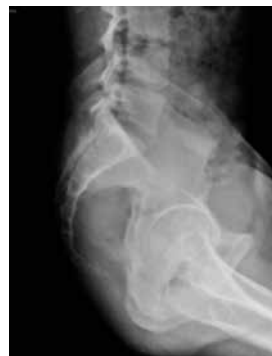
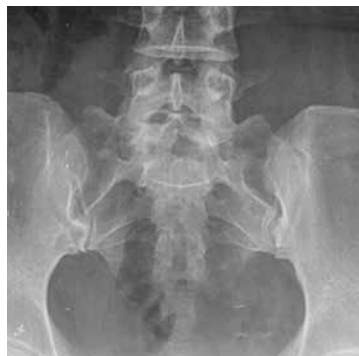
Fig. 28: Lumbo-sacral junction a) AP view and b) Lateral View

## D) Sacrum

### Sacrum-Antero-posterior (basic view)

**Positioning** – The patient lies supine on the bucky table with the mid sagittal plane at right angles and anterior superior iliac spines equidistant from the table top.

**Centering** – Central ray is directed 10-25 deg cranially at a midline point midway between the anterior superior iliac spine and the superior border of pubic symphysis.

### Anatomic structure Sacrum

#### Image Criteria

1. Sacrum should be seen without rotation.
2. Sacrum should not appear foreshortened.

### Sacrum Lateral View

**Positioning** – patient lies on, the side with knees flexed, cassette side should be appropriate to include sacrum, and coccyx and upper border should be at the level of anterior superior iliac spine.

**Centering** – point 5cm anterior to and level post iliac spine.

### Anatomic Structure Sacrum

#### Image Criteria

1. Sacrum should be in lateral projection without rotation.

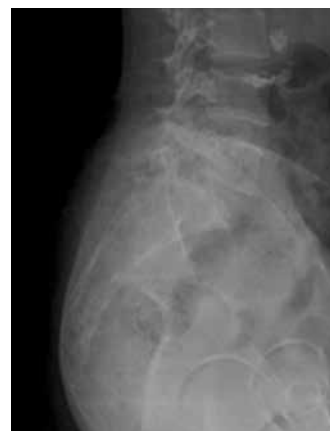
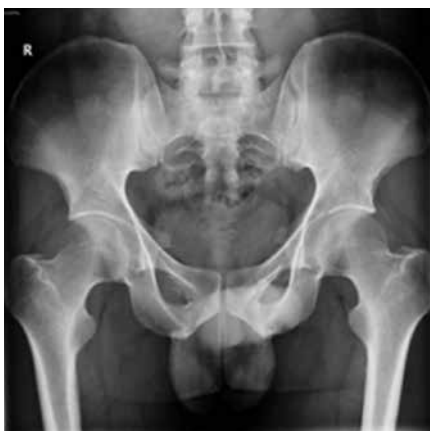
Fig. 29: X Ray Sacrum a) AP view and b) Lateral view

## E) Coccyx

### Antero-posterior view

#### Lateral view

#### Anatomic Structure

#### Coccyx - Antero posterior

**Positioning** – supine with knees flexed

**Centering** – midline 2 inches below anterior superior iliac spine with tube angled 150 towards feet.

#### Image Criteria

1. Entire coccyx should be projected above pubic bones.
2. Coccygeal segments should be seen without overlap.

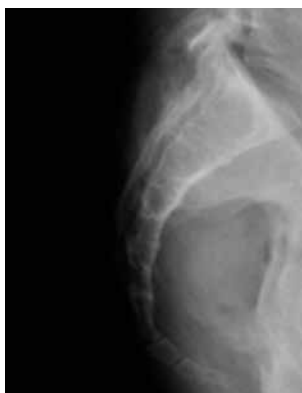#### Coccyx -Lateral View

**Positioning** – patient on the side with knees flexed Centering-on coccyx

#### Image Criteria

1. Coccyx should be seen with clearly visualized segments.
2. Spaces between Coccygeal segments should be open.

**Centering** – Direct central ray perpendicular to coccyx or to midportion of cassette.



**Fig. 30: Radiograph of Coccyx -lateral views**

#### **4) Radiography of Upper Limb**

##### **Introduction**

The upper limb or upper extremity extends from the deltoid region to the hand, including the arm, axilla and shoulder.

##### **Hand**

Basic views – AP, oblique, lateral

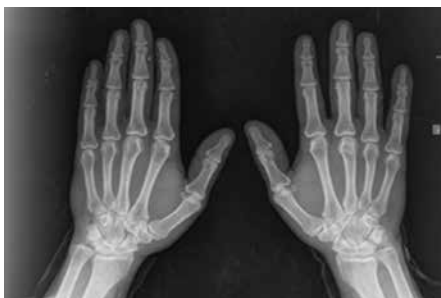##### **Anatomic structures**

1. Distal radius & ulna
2. Carpals and metacarpals
3. Phalanges and all articulations of the hand
4. Thumb (oblique projection)

##### **Hand-Postero – anterior**

**Positioning** – Fore arm is placed on table in pronation with palm of hand resting on the film. The fingers are separated and extended. The film should include area up to radial and ulnar styloid processes, which should be equidistant from the film.

**Centering** – The vertical central ray is directed to the head of third metacarpal



**Fig. 31: Radiograph of Hand PA view**





### Image criteria

- ◆ Carpals, metacarpals & phalanges should be seen
- ◆ Evidence of proper collimation should be seen

### Hand – Oblique View

**Positioning** – From the position for PA projection: the hand is laterally rotated through 45° and supported in this position on a foam pad.

**Centering** – Central ray is directed to the head of the fifth metacarpal bone

### Anatomic structures

1. Distal radius & ulna
2. Carpals
3. Metacarpals
4. Phalanges

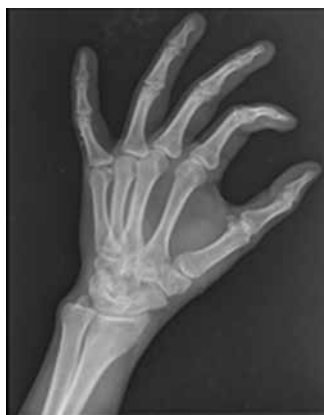

Fig. 32: Radiograph of Hand Oblique view

### Image criteria

1. Entire hand should be seen with fingers well separated & interphalangeal joint spaces open.
2. Metacarpals should be seen with minimal overlapping of shafts, bases & heads
3. Metacarpo phalangeal joint spaces should be open

### Hand-Lateral- View

**Positioning** – medial aspect of forearm rests on the table with medial aspect of hand and little finger in contact with the film with palm of hand at right angle to the film. The fingers are extended and the thumb is abducted.

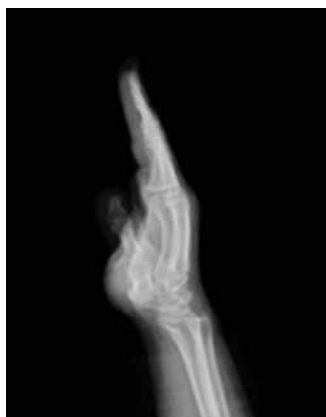**Centering** – to the head of 2<sup>nd</sup> metacarpal bone



It is a good projection for showing a suspected foreign body

### Image criteria

1. Hand & wrist should be seen in lateral projection with phalanges, metacarpals, carpals & distal radius & ulna superimposed
2. Thumb should be seen without superimposition



**Fig. 33: Radiograph of Hand -Lateral view**

## Scaphoid

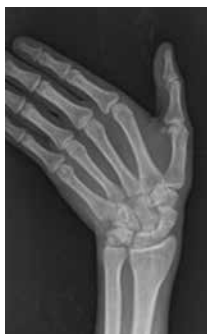### PA view in ulnar flexion

**Positioning** – Forearm is pronated. Keeping radial and ulnar styloid processes equidistant from the film. Hand is adducted i.e. in ulnar flexion

**Centering** – midway between radial and ulnar styloid processes

### Anatomic structures

1. Distal radius & ulna
2. Carpals (especially scaphoid)
3. Carpals interspaces adjacent to scaphoid
4. Proximal metacarpals



**Fig. 34: Radiograph of Hand - Postero anterior view with hand adducted**



It is a good projection to show fractures of the scaphoid

#### Image criteria

1. Scaphoid should be seen without distortion.
2. Distal radius & Ulna, carpals & proximal metacarpals should be demonstrated.

#### Anterior oblique (basic view)

**Positioning** – from PA position hand and wrist are laterally rotated by 45°

**Centering** – To ulnar styloid process

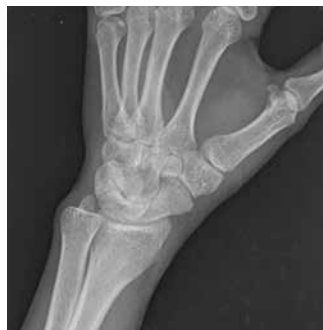

Fig. 35: Radiograph of Scaphoid- Anterior-oblique view

### Wrist

#### Basic views – PA, Lateral & Oblique

The forearm remains pronated and the change in position from posteroanterior position to that of lateral is achieved by rotation of hand. It provides two projections at right angles to each other for radius and ulna.

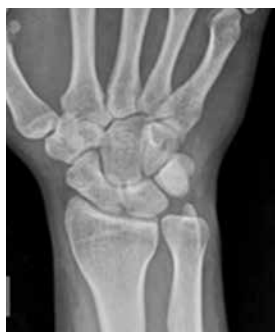#### Anatomic structure

1. Distal radius & ulna
2. Carpals and proximal metacarpals
3. If the distal ulna is of particular interest, an AP projection should be obtained.

#### Postero anterior (PA view)

**Positioning** – Patient is seated at table with arm abducted, elbows flexed at right angle and forearm pronated. Preferably shoulder, elbow and wrist should be at the same horizontal level. Center of the film is to be 2.5cm proximal to the styloid processes

**Centering** – Point midway between radial and ulnar styloid processes



**Fig. 36: Radiograph of Wrist- PA view**

#### **Image criteria (PA projection)**

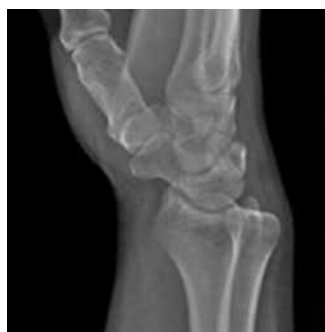1. Distal ulna should appear slightly oblique and the distal radius & proximal metacarpals should be seen without rotation.
2. Carpals should be demonstrated without the carpal interspaces.

#### **Lateral view**

(It is a good projection to show the relationship of the capitate, lunate & distal radius (normally seen as a straight line).

For first method the hand is laterally rotated on  $90^\circ$  to bring the palm of hand at right angle to the table. For the second method, humerus is laterally rotated by  $90^\circ$  and elbow is extended to bring medial aspect of forearm, wrist and hand in contact with table. Radial and ulnar styloid processes are made to super impose by slight backward rotation of hand.

**Centering** – Radial styloid process



**Fig. 37: Radiograph of Wrist- Lateral view**

#### **Image criteria**

1. Distal radius & ulna should be superimposed
2. Carpals & proximal metacarpals should be superimposed

#### **Wrist Oblique View**

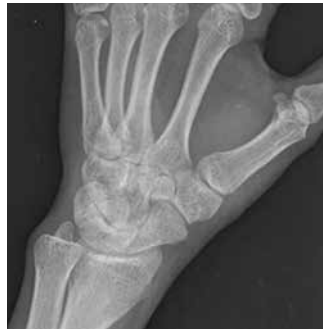**Positioning** – Patient is seated with arm partially abducted, elbow flexed at right angle and forearm pronated.



**Centering** – Midway between the radial and ulnar styloid

**Anatomic structure**

1. Distal radius & ulna
2. Carpals (especially scaphoid) with the adjacent joint space



**Fig. 38: Radiograph of Wrist oblique view**

**Forearm**

Basic view – AP & Lateral projection

**Anatomic structures**

1. Entire radius and ulna
2. Proximal row of carpal bones
3. Elbow joint (including distal humerus)

**Forearm-Antero Posterior View**

**Positioning** – patient is seated facing the side or end of table with elbow flexed at right angle. The palm of hand is at right angle to table.

**Centering** – midway between wrist and elbow

**Image criteria** – Proximal row of carpal bones and distal humerus should be included

**Forearm- Lateral view**

**Positioning** – Patient is seated at the side of table with arm abducted, elbow flexed at 90° to table.

**Centering** – Lateral epicondyle of humerus or direct central ray (perpendicular) to mid portion of forearm

**Image criteria**

1. Proximal row of carpal bones & distal humerus should be included.



2. Distal ends of radius & ulna and the epicondyles of humerus should be superimposed

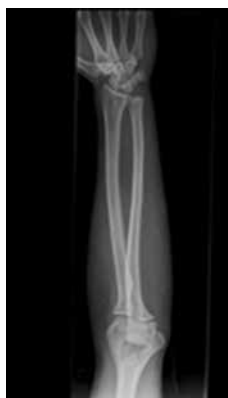

Fig. 39 (a): Radiograph of Forearm AP View

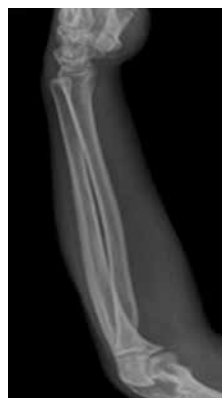

Fig. 39 (b): Radiograph of Forearm Lateral view

## Elbow

Basic view - AP & lateral projection

### Anatomic structure

1. Elbow joint
2. Distal humerus
3. Proximal radius & ulna

### Elbow AP

**Positioning** – Patient be seated at end of table to place entire upper extremity in same horizontal plane as film. Elbow should be fully extended, supinate hand (palm up), & place support under hand for comfort. Align long axis of the cassette with long axis of arm & forearm. Elbow joint should be in the centre of the cassette. Have patient lean laterally to place humeral epicondyles parallel to film.

**Centering** – Direct central ray perpendicular to midpoint of elbow joint

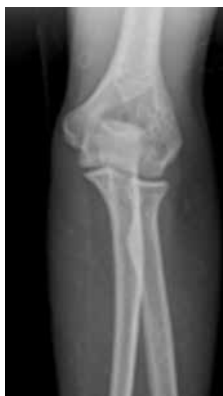

Fig. 40 (a): Radiograph of Elbow AP view





### Image criteria

1. Humeral epicondyles should appear parallel & not rotated
2. Elbow joint space should be well opened

### Elbow Lateral view

**Positioning** – Seat patient at end of table to place entire upper extremity in same horizontal plan as film.

Flex elbow to 90°. Align long axis of cassette with long axis of arm. Elbow joint should be on the centre of the cassette. Place humeral epicondyles perpendicular to plane of film. Place hand in lateral position (thumb up)

**Centering** – Direct central ray is directed to mid portion of elbow joint

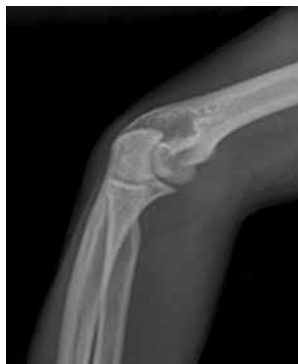

Fig. 40 (b): Radiograph of Elbow Lateral view

**Anatomic structure** – besides the structures seen on AP view the olecranon is also seen

### Image criteria

1. Elbow should be flexed 90° with joint space open.
2. Epicondyles of humerus should be superimposed and radial head should be superimposed on coronoid process of ulna.

### Shaft of Humerus

Basic views -AP & Lateral Projections

### Anatomic structure

1. Humerus
2. Shoulder joint
3. Elbow joint

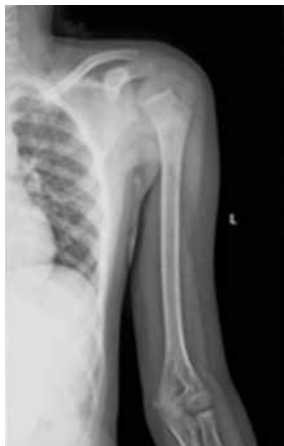### Humerus - Antero Posterior

**Positioning** – Patient lies supine with the unaffected shoulder raised. The arm is slightly abducted but fully extended at the elbow and supinated.



Medial and lateral condyle of humerus is equidistant from film. To reduce movement during exposure the sand bag is kept over palm while making exposure during arrested respiration.

**Centering** – midway between shoulder and elbow joints.



**Fig. 41 (a): Radiograph of Shaft of Humerus AP view**

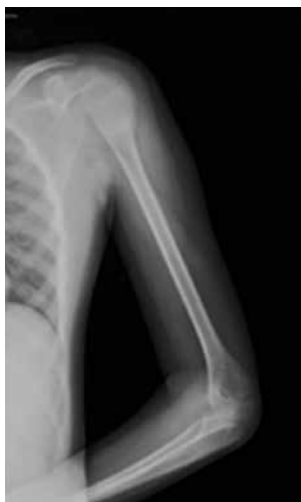#### **Image criteria**

1. Entire humerus (including shoulder & elbow joints) should be seen
2. Lateral & medial epicondyles should be seen in same plane without rotation

#### **Humerus- Lateral projection**

**Positioning** – From the AP position the elbow is flexed to 90°. The arm is abducted and then medially rotated through 90° to bring the medial aspect of arm, elbow and forearm in contact with table.

**Centering** – midway between shoulder and elbow joints.



**Fig. 41 (b): Radiograph of Shaft of Humerus Lateral view**



### Image criteria

1. Entire humerus should be seen
2. Humerus should be in lateral projection
3. Lateral & medial epicondyles should be superimposed

## Shoulder

Basic views – AP, Axillary projection & Stryker's view

### Anatomic structure

1. Shoulder (Glenohumeral) joint
2. Proximal humerus

### Shoulder - Antero Posterior

**Positioning** – Patient is supine with the shoulder of the affected side over the midline of table.

**Centering** – Coracoid process of scapula

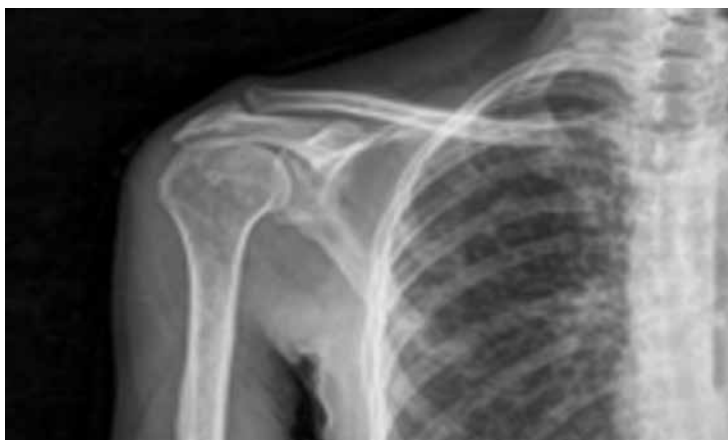

Fig. 42: Radiograph of Shoulder AP view

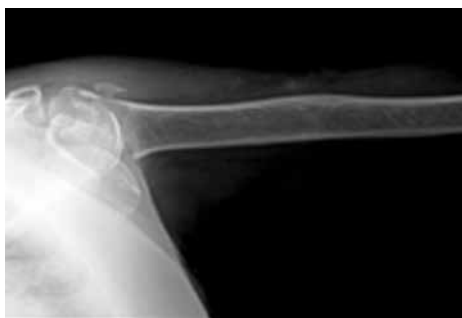### Image criteria

1. Proximal humerus & glenoid fossa of scapula should be seen
2. Humeral head slightly superimposes glenoid fossa

### Shoulder- Infero-superior (Axillary projection)

**Positioning** – Arm of affected side abducted right angle with the palm facing upwards. A cassette supported vertically against the shoulders is processed against the neck.

**Centering** – Towards axilla with minimal angulation towards trunk



**Fig. 43: Shoulder- Infero-superior (Axillary projection)**

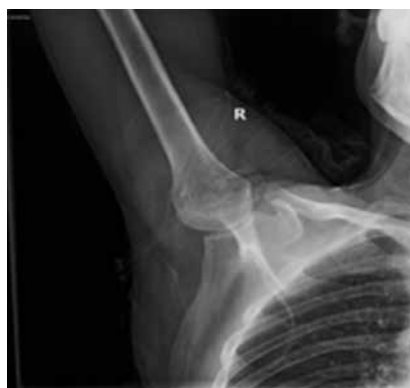#### **Image criteria**

1. Glenohumerus joint, coracoid process, humeral head & neck should be seen.
2. Acromioclavicular joint superimposes head of humerus

#### **Stryker's view**

**Positioning** – Preferably done in supine position with flexed elbow directed forwards and palm on top of head.

**Centering** – Coracoid process with angulation of tube 10° cephalad



**Fig. 44: Strykers view**

### **Sternoclavicular Joints**

#### **Basic view – Anterio oblique view**

**Positioning** – Patient stands facing bucky and then rotated through 45° with the relevant sternoclavicular joint nearer the film and central to it. Patients holds a vertical stand and keeps on breathing during exposures to blur out lung details.

**Centering** – At the level of the T4 vertebrae to a point 10 cm from midline on the side away from film.

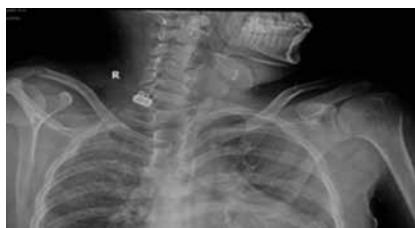

Fig. 45: Radiograph of sternoclavicular joint Anterior oblique view

## Clavicle

Basic view – PA projection

### Basic PA View

Patient faces the vertical bucky and midpoint clavicle in the center of the cassette. With the head turned away the shoulder of the side being examined is brought closer to the bucky

**Centering** – Horizontal beam centered to the center of the film

### Image criteria

1. Entire clavicle should be seen
2. Acromio clavicular & sterno clavicular joint should be seen

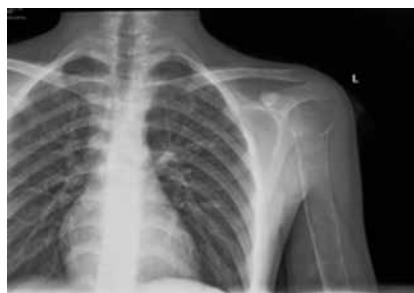

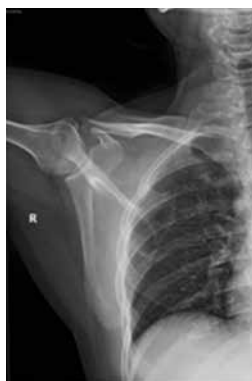Fig. 46: Radiograph of left clavicle PA view

## Scapula

Basic views – Antero posterior positioning  
Lateral Projection

### Scapula AP view

The patient lies supine on the x-ray table or stands / sits against the erect bucky. The middle of the clavicle lies in the middle of the table and the unaffected side is raised. The arm of the side being examined in partially abducted and medially rotated and elbow flexed.



**Fig. 47: Radiograph of Scapula AP View**

**Centering** – Direct central ray perpendicular to mid portion of scapula

**Image criteria** – Entire scapula should be seen without rotation and superimposition.

## 5) Radiography of Lower Limb

### Introduction

The lower limb includes the pelvic girdle, buttocks, hip, and thigh, as well as the structures distal to the knee i.e. leg, ankle, joint and foot.

### Foot

Basic views – AP projection (Dorsi-plantar view)

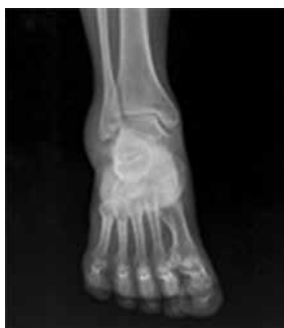- Lateral
- Oblique

**Anatomic structures** – Tarsals, metatarsals and phalanges

### Dorsi- Planter or Antero-posterior View

**Positioning** – Foot under examination is placed with plantar aspect in contact with cassette.

**Centering** – Perpendicular to cuboido-navicular joint which is midway between palpable tuberosity of navicular and 5th metatarsal



**Fig. 48 (a): Radiograph of Foot AP view**





**Image criteria** – Entire foot from distal phalanges of toes to the tarsals should be seen without rotation and Cuneiform, cuboid, and navicular should be well visualize

### Lateral view

Lateral medial projection (to demonstrate a true lateral of foot than medio lateral projection)

**Anatomic structures** – Distal tibia & fibula, tarsals, metatarsals and phalanges.

**Positioning** – With hips and knees flexed, pads placed under knee to rotate the limb so that planter aspect of foot is perpendicular to cassette

**Centering** – Navicular, cuneiform joint with central ray parallel to plantar aspect of foot and perpendicular to plane of cassette.

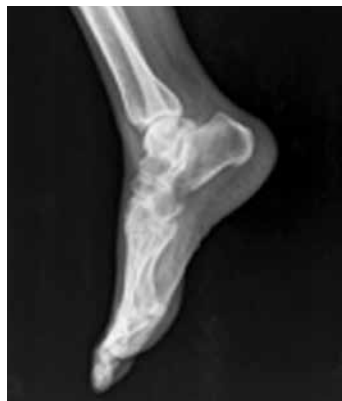

Fig. 48 (b): Radiograph of Foot Lateral view

### Image criteria

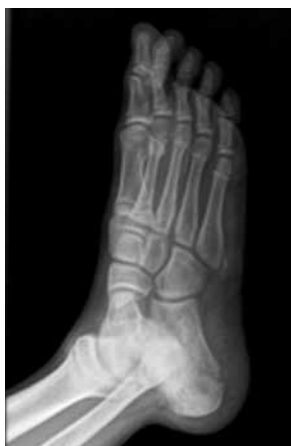1. Entire foot and distal leg should be seen
2. Tibia should be seen superimposed over fibula
3. Metatarsals and phalanges should be seen superimposed respectively.

### Oblique View (Médial oblique projection)

**Anatomic structure** – Tarsals, Metatarsals, Phalanges, Tarso-metatarsal and Intertarsal joints

**Positioning** – Patient sits with hips and knees flexed. The limb is then allowed to lean medially sufficiently to rotate the foot 45°.

**Centering** – Direct central ray perpendicular to third metatarso-phalangeal joint.



**Fig. 48 (c): Radiograph of Foot Oblique View**

#### Image criteria

1. Entire foot should be seen
2. The distances between shaft of 2nd to 5th metatarsals should be equidistant

#### Calcaneum

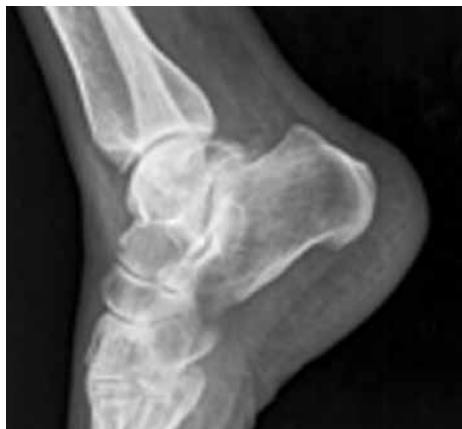- Basic view – Lateral projection
- Axial projection

#### Lateral View

Anatomic structure: Calcaneum, adjacent tarsals & ankle joint.

**Positioning** – Patient turns on the side under examination. Limb is rotated so to as superimpose medial and lateral malleoli vertically. The cassette is positioned with its lower edge just distal to plantar aspect of foot.

**Central projection** – Perpendicular to mid portion of calcaneus



**Fig. 49 (a): Radiograph of Calcaneum Lateral view**



**Image Criteria** – Calcaneus should be seen without rotation with clearly seen joint spaces between calcaneus and adjacent tarsals.

### Calcaneum - Axial projection

**Positioning** – Patient lies supine with limb extended and with great toes touching each other. Heels are separated by a small non-opaque pad. Ankles are dorsiflexed with aid of bandage placed round the forefeet and held by the patient.

**Centering** – The central ray is directed cranially at an angle of 40° to plantar aspect of foot to enter at base of 3rd metatarsal.

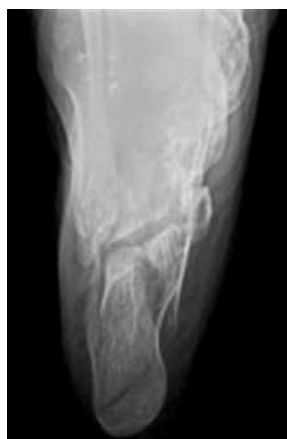

Fig. 49 (b): Radiograph of Calcaneum Axial View

**Image criteria** – Calcaneum should be seen in its entirety without rotation.

### Ankle Point

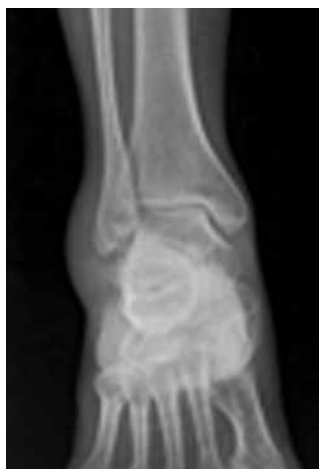- Basic view :
- Antero-posterior view
  - Lateral View
  - Oblique View

### Anterio posterior View

**Positioning** – patient should be supine or seated with support. The ankle is dorsiflexed with medial and lateral malleolus equidistant from, film.

**Centering** – midway between malleoli with central ray at right angles to imaginary line joining the malleoli.

**Anatomic structures** – Distal tibia & fibula, Ankle joint and Talus



**Fig. 50 (a): Radiograph of Ankle joint – AP view**

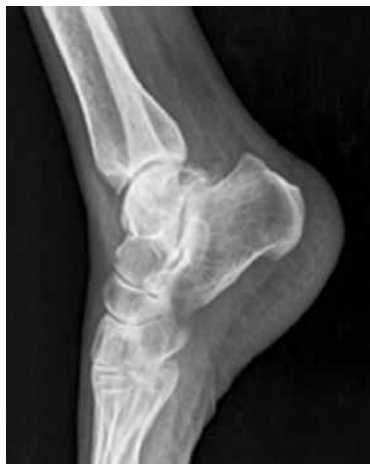**Image criteria** – Ankle joint should be centered & tibiotalar joint space well demonstrated.

#### **Ankle-Lateral view**

**Positioning** – Patient turns on to the side under examination. Ankle is supported in dorsiflexion and the limb is rotated until the medial and lateral malleoli are superimposed vertically.

**Centering** – perpendicular to level of malleoli.

**Anatomic structure** – Before positioning Distal tibia & fibula, ankle joint, talus, calcaneum



**Fig. 50 (b): Radiograph of Ankle joint Lateral (medio-lateral) view**

#### **Image criteria**

1. Posterior portion of distal tibia should superimpose distal fibula and Talus and adjacent tarsal bones should be demonstrated well
2. Ankle Joint should be in center of radiograph



## Leg

- Basic view:
- AP projection
  - Lateral projection

### Anatomic structure

1. Tibia and fibula
2. Knee joint and ankle joint

### Antero-posterior (AP) view

**Positioning** – Patient lies supine with limb extended. Ankle is dorsi flexed and limb rotated medially. Film must include both the ankle and knee joints.

**Centering** – perpendicular to both axis of tibia and imaginary line joining malleoli

**Image criteria** – Entire leg including the knee and ankle joint should be seen

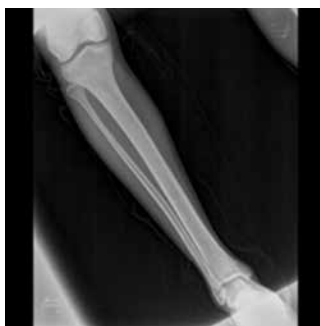

Fig. 51 (a): Radiograph of right leg- AP view

### Lateral projection

**Positioning** – Patient turns on the side being examined. Ankle is supported in dorsiflexion and the limb rotated until the medial and lateral malleoli superimpose vertically.

**Centering** – Middle of film at right angles of the tibia and parallel to an imaginary line joining malleoli.

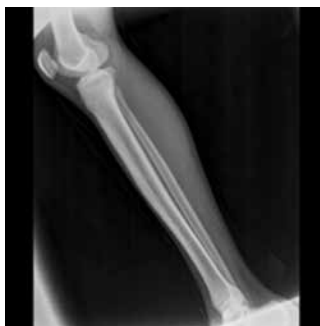

Fig. 51 (b): Radiograph of Leg Lateral view



**Image criteria** – Entire leg, including both the knee and ankle joints should be seen in lateral projection

## Knee Joint

Basic view – AP projection  
– Lateral projection

### Antero-posterior (AP) view

**Positioning** – Patient lies supine or seated with support and the limb under examination extended. Rotate the limb to central patella between femoral condyle.

**Centering** – 1 cm distal to apex of patella – direct central ray

**Anatomic structure** – Knee joint, Distal femur, Proximal tibia & fibula

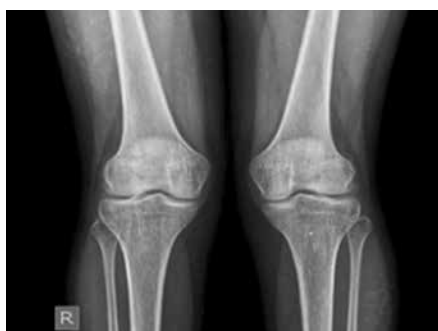

Fig. 52 (a): Radiograph of Knee AP view

### Lateral view

**Positioning** – patient lies on the side under examination with knee flexed approximately 30°. The ankle on the side under examination is raised on small sand bag to bring the axis of tibia parallel to the film. The anterior borders of femoral condyles are palpated distal and posterior to patella and limb rotated top superimpose them vertically.

**Centering** – central ray at right ankle to axis of tibia.

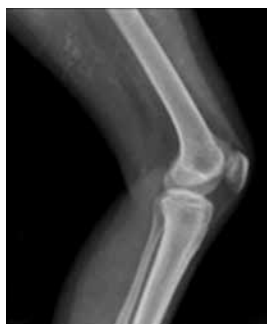

Fig. 52 (b): Radiograph of Kne- Lateral view





### Image criteria

1. Knee joint should be seen in lateral position
2. Proximal tibia should slightly superimpose head of fibula

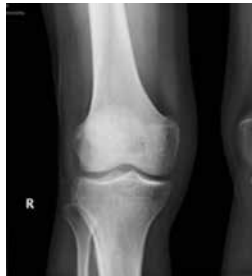### Patella

Basic view – Postero-anterior  
– Lateral projection

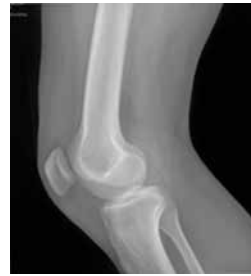Special view – Skyline view

The PA projection is obtained with the patient prone while the lateral view is obtained as the lateral view of the knee joint in lying position.

**Anatomic structure** – Patella, Femoro-patellar space



AP View



Lateral View

**Radiograph of the knee joint showing the patella**

Fig. 53 (a): AP View & 53 (b): Lateral View

### Skyline view

**Positioning** – Place patient prone on table. Align long axis of affected knee to midline of table/cassette.

Gently assist patient with flexion of affected knee until patellar surface is perpendicular to face of table, as far as patient can tolerate.

**Centering** – Direct central ray to pass through femoro-patellar space. (Inferior to superior)

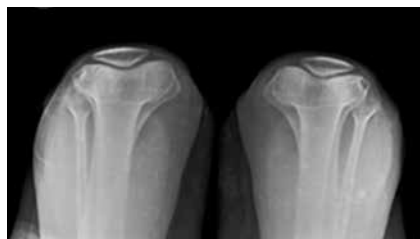

Fig. 53 (c): Skyline view



### Image criteria –

1. Patella should be seen in tangent (inferio-superior projection)
2. Femoropatellar space should be open with condyles well seen (tangential projection)

### Shaft of Femur

Basic views – AP

– Lateral

**Anatomic structures –** Femur, Hip joint & knee joint

### Antero-posterior (AP) view

**Positioning –** Patient lies supine without any rotation of the pelvis, and the leg rotated 15 degrees internally.

**Centering –** Direct central ray to the mid femur (thigh) perpendicular to the cassette.

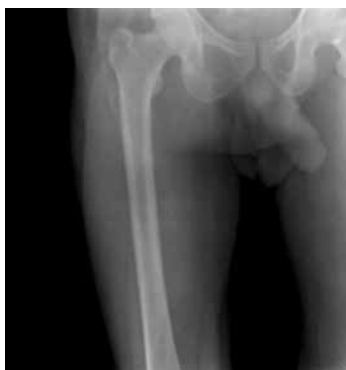

Fig. 54: Shaft of Femur- AP view

**Image criteria –** The entire length of the femur should be visible including the hip and the knee joint.

### Lateral view

**Positioning –** Patient lies supine, then turned on to the side of interest on the table with the hips and knees slightly flexed. The pelvis is rolled backwards to separate the two thigh. Distally the femoral condyles should be placed such that they superimpose on each other.

**Centering –** Direct central ray to the mid femur (thigh) perpendicular to the cassette.

**Image criteria –** The entire length of the shaft should be seen, the patella in profile and view should include the upper end of the fibula. The anterior and posterior margins of the femoral condyles should be superimposed.



## Hip Joint

- Basic views – AP (both or single hip)
- Lateral (single hip)

**Anatomic structures** – Hip joint ( both or single)

### Antero-posterior (AP) view

**Positioning** – Patient lies supine without any rotation of the pelvis, and the leg rotated 15 degrees internally.

**Centering** – Direct central ray to the mid point between the pubic symphysis and the anterior superior iliac spine if single hip to be taken. In case of both hips centering is done at a point 1 inch above the pubic symphysis.

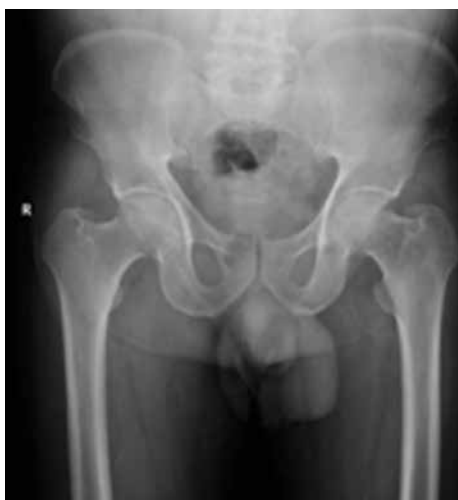

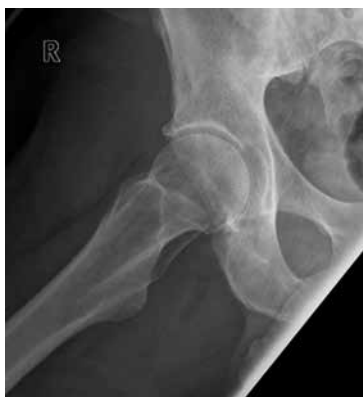Fig. 55 (a): Bilateral hip joints AP view

**Image criteria** – The pelvis with both the hip joints and the upper third of the femur should be included in the radiograph.

### Lateral View- Single hip joint

#### Positioning

1. Patient lies supine on the table with the knee and hip flexed on affected side. The femur is abducted 45° from vertical to place femoral neck parallel to the cassette
2. Centering – Direct central ray to mid femoral neck



**Fig. 55 (b): Hip- lateral view**

**Image criteria** – The hip joint should be well visualized in the radiograph.

## **Pelvis**

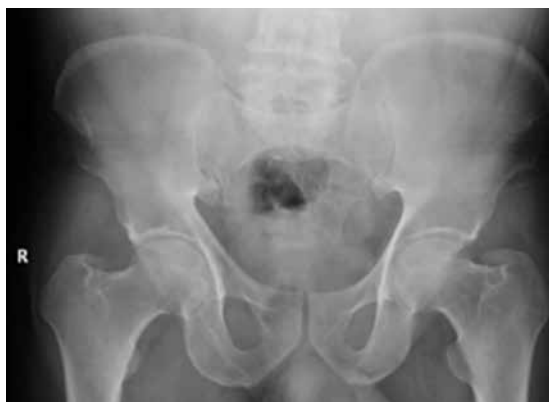Basic views – AP

**Anatomic structures** – Pelvis, LS junction and both hip joint joints

### **Antero-posterior (AP) view**

**Positioning** – Patient lies supine with the knees flexed, heels separated and the feet rotated internally by 5-10 degree to the vertical.

**Centering** – Direct central ray to the mid line at a point midway between the level of the anterior superior iliac spine and the superior border of the pubic symphysis, perpendicular to the film.



**Fig. 56: Pelvis AP view**

**Image criteria** – The pelvis should be visible without any rotation judged by the greater trochanters which should appear symmetrical in shape.



## Sacroiliac (SI) Joints

- Basic views
- AP (Both SI joints)
  - Posterior oblique view (single joint)

**Anatomic structures** – Both SI joints and sacrum

### Antero-posterior (AP) view

**Positioning** – Patient lies supine without rotation of the pelvis (both the anterior superior iliac spine should be equidistant from the table top). The knees flexed and the legs extended.

**Centering** – Direct central ray to the mid line at a point 5 cm below the level of anterior superior iliac spine with a cranial angulation of 30-45 degrees.

**Image criteria** – Both the SI joints, the sacrum and the LS junction should be seen.

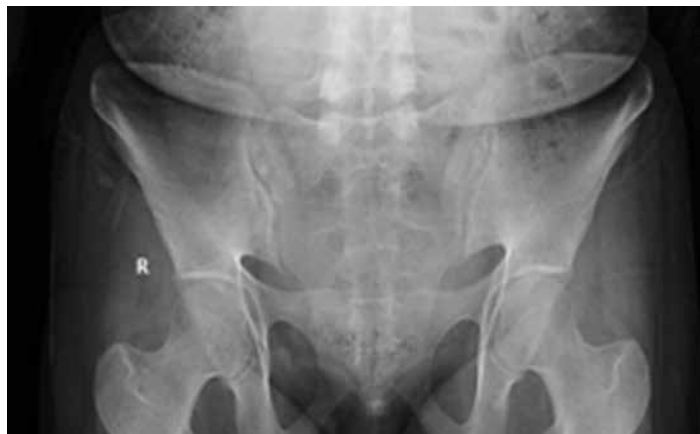

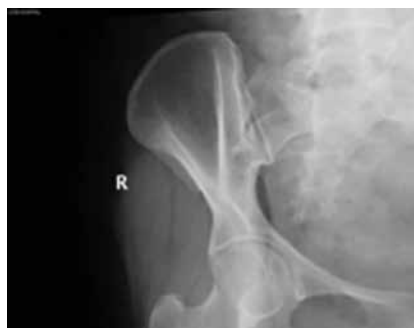Fig. 57: Sacroiliac joints- AP view

### Posterior-oblique view

**Positioning** – Patient lies supine and is rotated 25-30 degrees onto the side opposite to the joint to be examined.

**Centering** – Direct central ray perpendicular to the cassette 2.5 cm medial to the upside ASIS.

**Image criteria** – The entire SI joint should be seen and projected in the mid of the film.



**Fig. 58: Right SI joint- posterior- oblique view.**

## 6) Radiology of Chest

The thorax is the part between the root of the neck and the diaphragms. It contains the right and left lungs on the two sides with the mediastinum in the centre. The mediastinum contains the trachea, main bronchi, oesophagus, the heart and the vessels related to it. The thoracic cavity is bounded by the thoracic cage made of ribs, the chest wall muscles and is lined by the pleura internally. For chest radiography the patient is instructed to change into a cotton gown.

Care should be taken that there is no radio-opaque objects left on or under the gown. Long hairs must be pinned up so that they should not come in the way of lung field.

### Radiographs for chest

- |                         |                         |                              |
|-------------------------|-------------------------|------------------------------|
| (1) Chest X-ray PA view | (2) Chest X-ray AP view | (3) Chest X-ray lateral view |
| (4) Apicogram           | (5) Lordotic view       | (6) Lateral decubitus view   |

### Postero Anterior View

**Positioning** – The patient stands with face towards the cassette with chin extended and resting on the middle of top of cassette without any rotation. Upper borders of cassette should be placed 2” above the level of shoulder to ensure that apices are included. The shoulders are rotated forward and pressed downward in contact with cassette. This is accomplished by placing the dorsal aspects of hand over the Iliac crest (Hips.)

**Centering** – with horizontal beam centered first at the level of T5 vertebra and then angled 50 caudally to bring central ray coincident with the middle of film. A long FFD of 150-180 cm is used to minimize cardiac magnification.

**Image evaluation criteria** – The clavicle should be symmetrically placed, the scapula rotated away from the lung fields and apices and bilateral costophrenic angles included in the film.



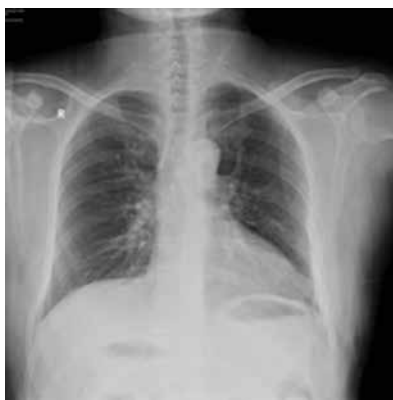

Fig. 59: Chest X-ray PA View

### Antero Posterior View

**Positioning** – Patient standing or lying down with back against the cassette. Shoulders are brought downward and forward with back of hands below hips and elbow well forwards. It is preferable to have the arms laterally rotated with palms facing forwards.

**Centering** – The beam is first centered at sternal angle and then angled until it is coincident with film.

This projection is not used for measurement of heart size as it leads to cardiac magnification.

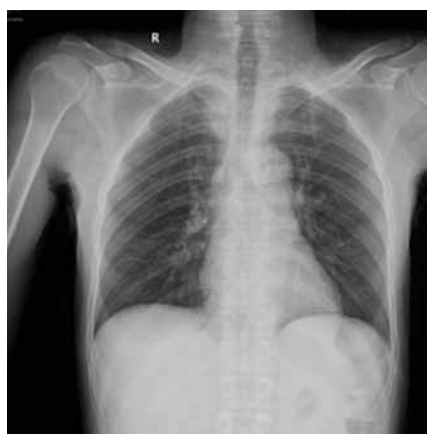
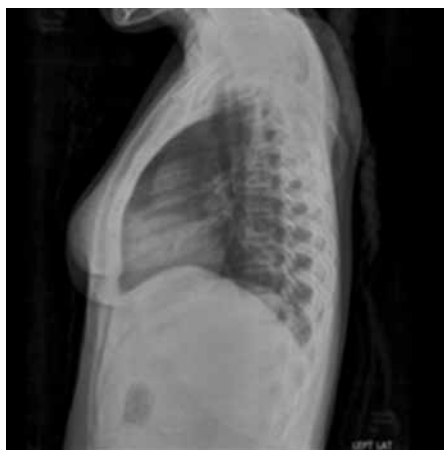
Fig. 60: AP view of the chest

### Lateral View

From radiography for PA projection, patient is rotated 90° to bring the side under examination in contact with cassette. Hands are folded above the head and median sagittal plane of body is parallel to cassette. Cassette is adjusted to include apices and lower border level to the level of L1 vertebra.

**Centering** – At right angle to film in midaxillary line and at the T5 vertebra.

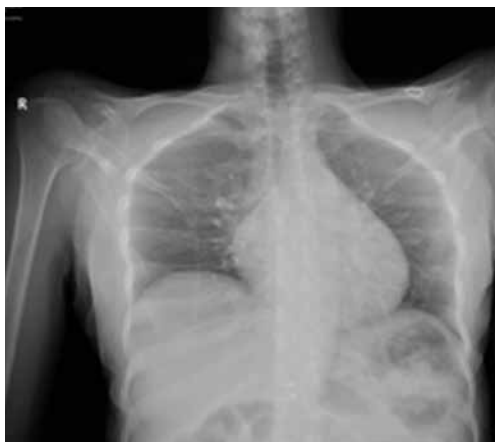

**Fig. 61: Chest X ray – Lateral view**

### Apicogram

A special view for demonstration of the lung apices. It is achieved by modifying AP projection in following ways.

Patient in AP position as for chest x ray and projection of central ray 30° cranially centered at sternal angle.



**Fig. 62: Apicogram**

### Lateral Decubitus

**Positioning** - This is a special view for demonstration of fluid or air in the pleural cavity. Lies on the affected sides to demonstrate fluid in pleural cavity or on the non affected side to demonstrate the air in pleural cavity.

Cassette is placed vertically behind or in front of him.

**Centering** –To the middle of the cassette using a horizontal beam.

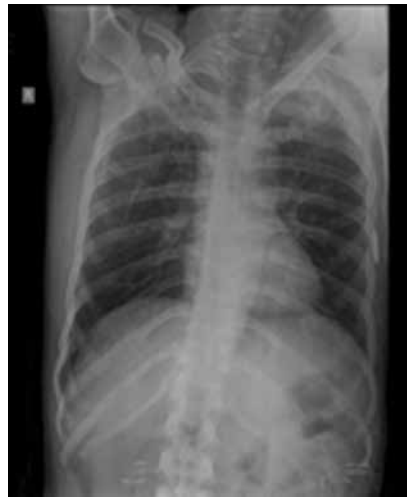

Fig. 63: lateral decubitus view of chest

## Sternum

It is a flat bone in the centre of the chest anchoring the anterior ends of the ribs on the two sides.

### Anterior Oblique view

**Positioning** – patient standing or sitting facing the bucky. Patient is then rotated 20°-30° to either side.

**Centering** – central ray perpendicular to the film and towards a point 7.5m lateral to T5 vertebra or 2 inches below sternal notch on the side nearest the x-ray tube.

Patient is allowed to breathe gently during on exposure to cause blurring of the lungs for better demonstration of the sternum.

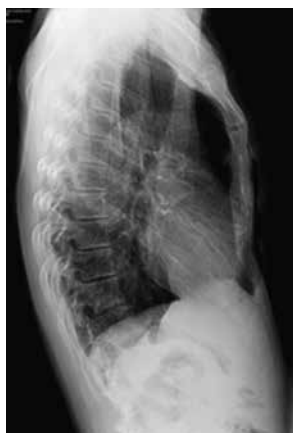**Image criteria** – The Sternum should be seen totally clean of the mediastinum and soft tissue shadow.

### Lateral View

**Positioning** – The Patient stand erect with either shoulder against a vertical bucky and feet separated to ensure stability. Hands are clasped behind the back and shoulder pulled well back. A long 60 inches focus film distance is used.

**Centering** – Horizontal ray towards a point 2.5 cm below the sternal angle.

Sternum should be in profile as a linear flat bone.



**Fig. 64: Radiograph of the sternum- Lateral view**

## Heart and Aorta

Besides the PA chest X-ray and the lateral chest X-ray oblique views are used for studying the heart.

### Right Anterior Oblique

**Positioning** – From the position patient is rotated. The right posteroanterior side of patient thorax is kept in contact with cassettes and trunk is rotated to bring the coronal plane at 75° to film

**Centering** – To vertebra T6 vertebra.

### Left Anterior Oblique

**Positioning** – From posterior anterior position patient is rotated such that left side of thorax is in contact with the cassette and coronal plane at 75° to film.

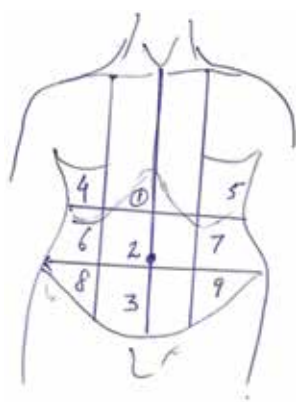
**Centering** – T6 vertebra.

## 7) Radiography of Abdomen

Abdomen is the body cavity below the diaphragm, which separates it from the thoracic cavity. The lower part of the abdominal cavity is called pelvis.

### Structures of Abdomen

The abdominal cavity is lined by the peritoneum, limiting the peritoneal cavity which contains the liver and gall bladder, spleen, stomach and small intestines. The kidney and ureters, pancreas and large bowel except the transverse colon lie behind the posterior peritoneum is the retroperitoneum space. The rectum, urinary bladder and parts of the reproductive system are located in the pelvic cavity. The abdomen is arbitrarily divided by four imaginary planes into nine regions as follows:



- 1- Epigastrium
- 2- Umbilical
- 3- Hypogastrium
- 4- Rt hypochondrium
- 5- Lt hypochondrium
- 6- Rt lumbar
- 7- Lt lumbar
- 8- Rt iliac fossa
- 9- Lt iliac fossa

Radiographic evaluation of abdominal contents begins with plain film examination. When abdominal x-ray is pre-planned intestinal tract must be evacuated of gas and faecal matter for which patient is asked to take a laxative eg., Castor Oil etc. as well as a gas absorbent eg. Charcoal tablets, the night before the examination. The patient should come fasting the next day in the morning.

A cleansing enema may be required in chronically constipated patients. However, this preliminary preparation is omitted in cases of 'acute abdomen', intestinal obstruction or perforation; and in infants and small children.

Routine x-ray films are taken either in supine or prone position including whole of the abdomen from the level of the diaphragm to pubic symphysis.

Patient asked to hold breath during exposure. Sometimes compression band may be used for immobilization in cases of children.

#### Radiographs: -

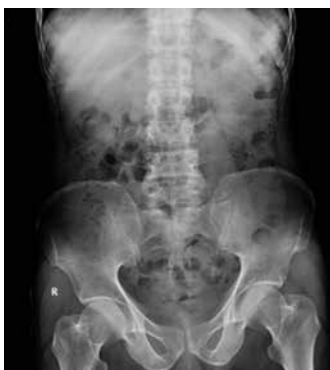- (1) X-ray abdomen AP view- Erect and Supine
- (2) Lateral view- Cross table lateral view
- (3) Invertogram

#### Abdomen AP View

The patient lies supine or stands or stands erect facing away from the cassette. The mid-sagittal plane is made to fall perpendicular to the middle of the cassette, which is centered at the level of iliac crest or just above the umbilicus. In erect x-rays, centering is done a little higher, so as to include both domes of the diaphragm. Exposure is delayed for few minutes, if the free air is suspected in the peritoneal cavity to allow the gas to rise.

Exposure is made with use of grid in either case. The central ray is perpendicularly directed to the center of the film.

For radiation protection of the gonads, a gonads shield is applied in male patients and also in female patients, if pelvis does not need to be included.



**Fig. 65: X-Ray Abdomen- supine AP view**

### **Abdomen Lateral View**

The patient is turned side ways with the mid-sagittal plane parallel to the table and made is lie still with hips and knees flexed and elbow and arm flexed above the head.

The cassette is centered just above the level of iliac crests. X-ray beam is kept perpendicular centering to the middle of the film.

### **Cross Table Lateral View of the Abdomen**

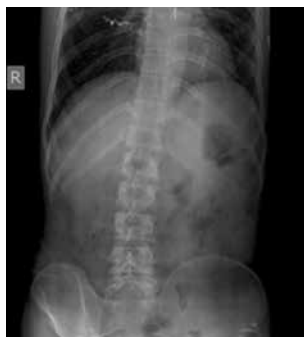This view is taken in cases of very ill patients who cannot sit or even lie on their sides to detect air-fluid level or for air under the diaphragm.

The patient lies supine with the arms raised above the head. A cassette with a vertical grid is supported on one side of the patient and placed such to include the thorax to mid sternal level and the x-ray is taken with a horizontal beam.

### **Lateral Decubitus View of the Abdomen**

This projection is used when patient cannot stand erect.

The patient is made to lie on his left side with the cassette vertical against the patient's abdomen. The upper part of the cassette should be at the level of the lower ribs so that the film includes the lower parts of the lung field. The film is taken by horizontal beam directed posteriorly, and centered to the centre of the cassette.



**Fig. 66: lateral decubitus view of the abdomen**





## Invertogram

This is inverted abdominal radiography taken in neonates of suspected anal atresia to look for the upper level of the gas which corresponds to the level of obstruction in the large bowel (Rectum). This x-ray is taken not less than 18 hours after the birth which is the time taken by the air to reach the rectum in normal newborns. The neonate is held upside down with the feet for about 5-10 minutes, and the A.P. and lateral radiograph is taken with the vertical Bucky.

Alternatively a prone translateral view can be taken with a horizontal beam

## Radiographs in Acute Abdomen

Series of x-rays in acute abdomen needed are

1. Abdomen AP Supine
2. Abdomen AP erects or left lateral decubitus
3. Chest PA view including abdomen

The x-rays apart from detecting radio opaque stones, calcifications and foreign bodies will also demonstrate the distributions of air and fluid level in the GIT as well as detect free peritoneal gas. For erect film 5-10 minutes time has to be given in a particular patient before exposure.

## Biliary Tract

### Left anterior oblique (prone)

**Positioning** – Prone with right hand resting and head and left arm lying along the side and behind the trunk. Right side of patient is rotated to bring coronal plane at 20° to film.

### Right posterior oblique

**Positioning** – With patient lying supine, left side is raised rotating median sagittal plane through 20°. Both shoulder and elbows are fixed to place both hands above patient's head.

**Centering** – Midway between midline and raised side of abdominal wall 2.5 cm above lower costal margin and to the centre of cassette.

**K.U.B. (Kidney, Ureter, Bladder)** the most common abdominal radiograph is for the KUB (Kidney, Ureters, Bladder) region for detection of radiopaque calculi.

## Preparation of the Patient

A bowel preparation to clear the bowel gas and fecal matter is necessary prior of the Radiograph. Removal of all artifacts for the region of the interest is also mandatory.

### 1. Abdomen-Antero-posterior, Supine View

Patient is supine with hands over the chest and mid sagittal plane in the middle and at right angle to the table. Cassette is placed in the bucky tray (grid) so that upper level is at the xiphisternum



and lower below the pubic symphysis. Centre of the cassette should be at the lower costal margin. The perpendicular X-ray beam is directed towards the centre of the cassette and exposure made in full inspiration.

## 2. Lateral View

Position-Lying on the side under examination with hips and knees flexed. Median sagittal plane is parallel to film and vertebral column is along the midline of table. Cassette with bucky tray is centered to L1-L2 vertebra about 5cm above to lower costal margin to study the renal areas.

Centering-middle to film in suspended respiration.

## 3. Postero-oblique Radiograph

The patient is raised from a supine position until the coronal plane is 20-30 degree from the table. For the kidneys, a smaller cassette is placed transversely in the bucky table and X-ray beam is centered between umbilicus and Xiphisternum. Whenever the ureters are to be included a larger 15x12 size film to be used. And centre is done at lower costal margin. The central ray is directed to be centre of the cassette.

## Urinary Bladder

1. **Anteroposterior** with 15 degree caudal angulations-with the patient supine and mid sagittal plane at right angles to the middle of the table. The cassette is placed with the lower edge 5cm below the pubic symphysis. Central beam is centered to the centre of the cassette with 15 degree caudal angulations. Grid is used.

## 2. Posterior oblique

Positioning-patient is rotated through 35°. With the point midway between pubic symphysis and anterior superior iliac spine on raised side lying in the midline of the table. Cassette is placed with its upper border at level of anterior superior iliac spine.

Centring – 2.5 cm above pubic symphysis

## 8) Radiography in Special Situations

- a) Emergency Radiography
- b) Pediatric Radiography
- c) Mammography

## Emergency Radiography

### Introduction

The main aim in emergency radiography is to radiologically demonstrate the injured part with minimal movement.



## Principles of Positioning

- (1) The first principle is to have two projections at  $90^\circ$  to each other. The usual choices for these two radiographs are AP and lateral view of the concerned region.

This is achieved by horizontal angulation of the of the central ray and corresponding placement of the film, without any manipulation of the part. In some situations where accurate positioning is difficult oblique or distorted view may be accepted.

- (2) Second important aspect in emergency and trauma radiography is to avoid missing out of any pathology. Therefore use of larger films or multiple films for the small part is acceptable. Thus, both the proximal and distal joints of a long bone requested to be radiographed should be included in the radiograph so as not to miss fractures. If this is not possible at least the joint near the site of injury should always be included while doing radiography of the limbs.

This concept is also applied to the chest and abdomen radiographs. The entire thorax or should be covered in the radiographs were though 2 film are required to do so.

- (3) Patients in emergency situations cannot be made erect and therefore radiograph has to be taken in the supine position using a horizontal beam for obtaining lateral radiograph for example patient with cervical injury.
- (4) Use of grid is mandatory in case of swelling of the part to be radiographed or where the part measures more that 10 cm.
- (5) Emergency and trauma radiography involves the use of mobile or portable radiography, therefore special precaution are to be taken to protect other people in the ICU or wards
- (6) In trauma setting higher factors are used for cast. Factors are increased by 5 to 7 kVp for dry caste and 8 to 10 kVp should be increased for wet cast

## Paediatric Radiography

Radiographic examination of children is challenging, requiring additional care by the radiographer due to risk radiation, physical and psychological risk to the little patients.

For examining the children one has to be kind and sympathetic towards them and understand the intellectual and emotional maturity of children.

## Risk in Paediatric Radiology

### I. Radiation Hazard

Bone marrow, which is active in the formation of blood cells and distributed throughout the skeleton in children can be damaged by the ionizing radiations. Therefore measures are taken to minimize the affect of radiation as follows-

Use proper immobilization devices to obtain radiography and thus avoid need of repeat exposures due to motion.



Use of gonadal shields for protection of testis and lead aprons to protect the sternum and gonads should be used wherever feasible.

## **II. Physical Risks**

Optimum exposure factors should be set before the child is positioned on the table.

For neonates warming devices should be present to prevent problems of changes in body temperature in them.

One should be well versed with the signs and symptoms of adverse reactions to contrast media and how to deal with them in children.

## **III. Psychological Trauma**

Children fear hospitals, doctors, nurses and technicians. Toys help them to adjust to the strange environment of a hospital.

Infants and majority of children cry when taken from their mother but usually calm down quickly when parents remain with the child in the examination room.

## **Radiographic Equipment**

One mobile unit should be stationed for use in the neonatal nursery.

Cassettes used in neonatal ICU should be kept extra clean and wrapped in disposable plastic bags on sterile sheets and should not be used in other areas of the hospital.

## **Approach to Parents and Children**

### **Approaching the Parents**

If the child is old enough, examination should be explained to him as well as along with the parents. If the child is young to comprehend, direct the explanation to the parent. As parents are under stress words spoken in a soothing tone, should be used for communication. Parents in radiography room should be protected from scatter radiation using lead apron and lead gloves.

### **Approaching the Child**

- ◆ Infants who are well fed are happy, playful or sleepy and allow a good examination unless painful.
- ◆ Children between 6 months and 2 years fear pain and separation from parents. This age group require the immobilization techniques and parental presence during the examination.
- ◆ Children between 2 to 4 years are very curious and can test one's patience and imagination. These children may be shown how the collimator light works, told that the x-ray is like a camera and will not fall on them.



- ◆ Praising a child (esp. between 3 to 7 years) is a powerful motivator. Engage children in chatting about their brothers, sisters, pets, school or popular cartoons.
- ◆ 5 to 8 years old are accommodating and easy to work with as their anatomical landmarks are easily identifiable.

### Approaching children requiring special care

- ◆ When entering NICU one must wash and wear a gown because of the risks of infection. Supine films of the chest and abdomen can be obtained by placing the cassette under the baby or under the mattress causing less cooling of the infant.
- ◆ In premature infants one of the greatest dangers is hypothermia leading to slowing of the heart. So infant's skin should not come in contact directly with the cassette. The room temperature should be elevated 20 to 30 min before arrival of the child by use of radiant heaters.

### Common Paediatric Radiographs

Chest radiographs must be acquired on maximal inspiration when the child takes a big gasp of air at the end of a cry, the abdomen expands, or the sternum rises.

Infants and young children are best examined supine. Head should not be turned even slightly to the side as this will make the chest oblique.

For 3 to 10 years old PA erect projection is used with child sitting and arms over their heads or draped over the x-ray cassette holder. For lateral projection, parents can assist by holding the child's head between the arms above the head.

For Hip Radiography symmetric positioning is crucial. Wet diapers should be removed as they can produce significant artifacts.

Children on stretchers may be examined without moving them to the table, by skilled radiographers.

A cross table lateral view is obtained, instead of the traditional 'invertogram' of a child with imperforate anus should no longer be made. For Gastrointestinal Procedures Children <2 years should never be kept fasting longer than 3-4 hours prior to the examination.

For Intravenous Urography make a conscious effort to keep number of exposures to the minimum. Infants may be fed once the contrast has been injected.

### Mammography

A special radiography exists to demonstrate the soft tissue detail of the breast. This technique is called mammography and is carried out with a dedicated, specialized radiography equipment called mammography equipment.





## Anatomy of the Breast

Breast or mammary glands is a hemispherical soft tissue structure located in the anterior chest wall from 2<sup>nd</sup> to 6<sup>th</sup> ribs superficial to the muscles. The size varies with the age, and under the effect of hormones eg. in menstrual cycle, pregnancy and lactation.

The nipple is a small projection containing a collection of duct openings from the secretory glands within the breast tissue. The dark area surrounding the nipple is termed the areola. The junction of the inferior part of the breast with the anterior chest wall is called the infra-mammary crease. The axillary tail is a band of tissue that wraps around the pectoral muscle laterally. The width of the breast greater than the vertical measurement.

The large pectoralis major muscle overlies the whole thorax. A fibrous sheet surrounds the breast below the skin surface and also covers the pectoralis major muscle, which join in the retro mammary space. This retro mammary space must be demonstrated on at least one projection during the radiographic study of the mammary gland.

### Two Basic views taken in mammography are

- ◆ Craniocaudal (CC) view
- ◆ Mediolateral oblique (MLO) view

### Technical Factors

- ◆ Film size-8x10 in., crosswise or -10 × 12 in., crosswise
- ◆ Moving grid
- ◆ 25 to 28k V p.

### Patient Position

- ◆ Standing or seated on a stool

### Part Position For Cranio caudal (CC) projection

- ◆ Film tray height is determined by lifting the breast to achieve a 90° angle to the chest wall. The tray will be at the level of the infra-mammary crease at its upper limits.
- ◆ The breast is pulled forward into the film holder centrally with the nipple in profile.
- ◆ The head is turned away from the side being imaged.
- ◆ Wrinkles and folds on the breast should be smoothed out and compression applied.
- ◆ The marker and patient ID information is always placed on the axillary side.

### Central Ray

- ◆ Perpendicular centered to the base of the breast, the chest wall edge of the cassette in suspended breathing.
- ◆ SID: is fixed for the machine, appropriately 60 cm.





## Mediolateral Oblique (MLO) Projection

### Technical Factors

- ◆ Film size-8 x 10 in., crosswise or -10 x 12 in., crosswise
- ◆ Moving grid
- ◆ 25 to 28 KVP.

### Patient Position

- ◆ Standing or seated on a stool.
- ◆ Part Position.
- ◆ Tube is angled about 45° to that the central ray enters from the medial side of the breast perpendicular to the patient's pectoral muscle.
- ◆ The film holder's height is adjusted so that the top of the film will be at the level of the axilla.
- ◆ The patient holds the bar on the side of the unit with the hand so that the axillary fold is placed on the cassette.
- ◆ Push the patient slightly towards the angled film holder and pull breast tissue and pectoral muscle anteriorly away from chest wall until the inferolateral aspect of the breast is touching the film holder.
- ◆ Apply compression slowly with the breast held away from the chest wall.
- ◆ The upper edge of the compression device will rest under the clavicle and the lower edge will include the infra mammary fold. Wrinkles and folds on the breast should be smoothed out and adequate compression applied.
- ◆ The marker should be placed high and at the axilla.

### Central Ray

- ◆ Perpendicular centered to the base of the breast at the level of chest wall.
- ◆ SID : approximately 60 cm.
- ◆ The patient should remain immobile and suspend her breathing while exposure is being made.

### Review Questions

- Q 1. What do you understand by lateral decubitus position?
- Q 2. What do you understand by antero- posterior projection?
- Q 3. In right lateral decubitus projection the central ray passes from which side to which side of the patient.



- Q 4. Which anatomical structures are best visualised in cervical spine AP view with open mouth. How will you position a patient for this view.
- Q 5. To see the odontoid process which view should be done?
- Q 6. How will you position a patient for cervical spine lateral view and what are the imaging criteria for a perfect cervical spine lateral view?
- Q 7. Which is the best view for intervertebral foramina in cervical spine?
- Q 8. How will you do X- Ray hand for suspected fracture of scaphoid?
- Q 9. Describe the Stryker's view?
- Q 10. Which is the best view to see the sternoclavicular joint of right side?
- Q 11. What is the swimmer's view?
- Q 12. What is Frankfurt line?
- Q 13. What is Schuller's view?
- Q 14. How will you do the X- ray skull for sella turcica?
- Q 15. How will you do x- ray for Para nasal sinuses?
- Q 16. Which is the best view of nasal bone?
- Q 17. How will you do the X –ray for temporo- mandibular joint?
- Q 18. What should be the focus film distance for a good chest X – Ray PA view?
- Q 19. What is apicogram? How will you take an apicogram?
- Q 20. What is lordotic view?
- Q 21. How will you take radiograph for sternum?
- Q 22. Which is the best view of chest X- ray to study heart and aorta?
- Q 23. What is the indications of AP Chest Film?
- Q 24. How will you do the skyline view?
- Q 25. What is the townes's view?
- Q 26. What is the orbito-meatal base line?
- Q 27. What is the cross table lateral view and what are the indication for it?
- Q 28. What are the indications for lateral decubitus view of abdomen?
- Q 29. What is invertogram? How it is performed?
- Q 30. What are the series of film for acute abdomen.
- Q 31. What bowel preparation is required for X Ray abdomen?
- Q 32. What are the basic view of mammogram?



## Chapter-2

# Special Radiographic Procedures

### Excretory System

### Biliary System

### Gastrointestinal system

### Angiography

### Myelography

### Miscellaneous

**Objectives – After studying the chapter the students will be able to:**

- ➔ Elaborate the radiography procedures for excretory, biliary, gastrointestinal and reproductive system
- ➔ Demonstrate the procedures for excretory, biliary, gastrointestinal and reproductive system

### 1) Urinary Tract

The urinary tract consists of the kidney, ureters, urinary bladder and urethra. The radiological procedures used to diagnose the abnormalities in the urinary tract are:

- 1) Intravenous Urography (IVU)
- 2) Retrograde Pyelography (RGP)
- 3) Antegrade Pyelography (AGP)
- 4) Voiding Cystourethrography (VCUG)
- 5) Retrograde Urethrography (RGU)

#### Intravenous Urography (Ivu)

It is the investigation most commonly used for evaluation of disorders of the urinary tract, (kidneys, ureter and bladder). It provides information regarding the status of the kidneys as well as the functional anatomical information on the kidneys, the pelvicalyceal system the ureters and the urinary bladder. However, it is not advisable to do it in patients with previous reaction to contrast media, pregnancy, multiple myeloma or overt cardiac and renal failure.

#### Patient Preparation

1. (Preliminary plain x-ray/prerequisite) for KUB region (AP view) after proper bowel preparation is a must before IVU.



2. Laxatives and gas absorbents (2 Dulcolax and 6 Charcoal tablets) are given on the night previous to the examination to adults and the patient is kept fasting on the morning of IVU.
3. A blood urea and Serum creatinine level report to show the functional status of the kidney should be available before planning an IVU.
4. A history of allergy to drugs and contrast medium.
5. Any history of significant systemic illness of cardiac or respiratory system e.g. asthma is a must before any IVU study.
6. For elective pre-planned IVU study the menstrual history of a female patient must be taken and the study planned during the safe (10 day) period of the menstrual cycle.
7. An informed consent of the patient must be taken before giving contrast, after explaining the risk of contrast reaction to the patient.

### Procedure

On the day of IVU study, a scout film (X-ray KUB-AP view) is taken to see

- 1) The bowel preparation
- 2) To judge the exposure factors
- 3) To confirm the position of calculus or work for the abnormality already visible on the previous plain x-ray film.

### Contrast Medium

- ◆ Approximately 40ml of Urografin 76% is given as a bolus intravenously in adults with normal renal function.
- ◆ In children about 1ml/kg body weight of Urografin 60% is given. In high risk patients or with underlying disease like diabetes, a non-ionic contrast medium like Iohexol/ Iopamidol should be used.

The contrast is injected intravenously (as a bolus) observing the patient for any signs of untoward reaction. In case of any reaction the injection is stopped and the radiologist must be informed immediately and appropriate measures taken.

For most mild reaction reassurance and antihistaminic drug injection is sufficient while for moderate to severe reactions, appropriate measures need to be taken.

Abdominal binder if applied must be released.

ABC should be evaluated and restored as soon as possible.

- A) Airway Patency
  - B) Breathing
  - C) Circulation
- ◆ The vitals i.e. pulse, blood pressure, respiration and level of consciousness of the patient must be examined and recorded.



- ◆ Intravenous drip must be started immediately.
- ◆ Oxygen should be given by intranasal catheters or mask.
- ◆ The doctor and nurse must be assisted in giving medication through appropriate route, as required

### Filming Sequence

The first two films are taken for renal areas crosswise 1 min and 5 min from the time of injection with cassette 10" x 12" placed. An abdominal binder may be applied across the patient's abdomen after the 5 min film. This helps to retain the contrast within the pelvicalyceal system and the ureters for better visualization. However, the binder is omitted in children, patients with abdominal mass or suspected renal injury. Further films are taken on 12" x 15" cassette for the whole KUB (Kidney, Ureter, Bladder) region after releasing the binder at 10-15 minutes after injection. Sequence of films taken 1 min (10" x 12") – nephrographic phase shows the renal function, 5 minute – pyelographic phase shows contrast excretion into the pelvicalyceal system (PCS). Therefore 10 – 15 min (12" x 15") Binder release film for KUB region. Prone film is taken to visualize the lower ureters if not seen in previous film. Full bladder film (10" x 8") for urinary is followed by a radiologist bladder postvoid bladder film.

Each film is processed immediately after exposure and seen before the next film is exposed.

Oblique views under fluoroscopy may be required to show the relationship of a radio-opaque shadow to the urinary tract, i.e. whether it is a calculus or a lymph node lying outside the line of ureters. Delayed films after 24/48 hrs may be required for demonstration of functionally impaired kidneys.

Injection Lasix may have to be given intravenously during the procedure to confirm or rule out the diagnosis of pelvic-ureteric junction obstruction.

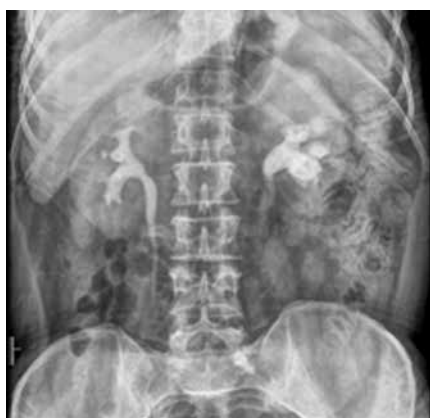
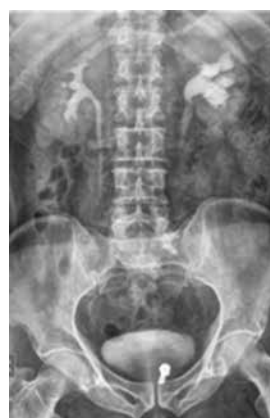
Fig. 67: 5 min film



15 min. IVU film (Prone) of Abdomen

### Retrograde Pyelography (RGP)

When IVU fails to demonstrate the whole or part of ureter, and when ectopic ureteric openings are seen, demonstration of the course of ureter is done by injecting contrast directly into the

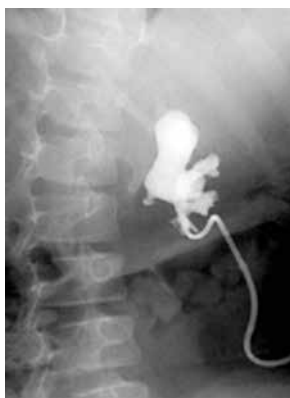



ureter from its opening into the urinary bladder. It is contra indicated in acute urinary tract infection. The catheter in the selected ureter is put by the urologist cystoscopically. The catheter is retained by fixing it with tapes.

Under fluoroscopic control contrast (8-10 ml Conray 280) is injected into the catheter and films are taken demonstrating the ureter in its entire length till the pelvicalyceal system, or any obstruction in it.

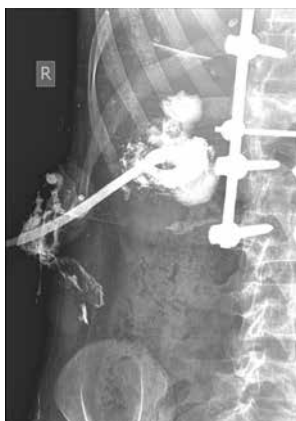### Antegrade Pyelography (AGP)



**Fig. 68: Antegrade Pyelography done through nephrostomy tube showing dilated calyceal system and proximal ureter**

When nephrostomy has already been done on a patient for a drainage procedure or for PCNL (Percutaneous Nephrolithotomy or when RGP is not possible because of difficulty in catheterization of the ureter, antegrade pyelography is done. In post operative cases of ureter implantation also, this study is required as RGP is not possible.

Nephrostomy is performed under ultrasound/fluoroscopic guidance. Contrast (8-10 ml of Conray 280/Urografin 60%) is injected under fluoroscopy guidance. The needle is positioned in the nephrostomy tube which is clamped distal to the needle. The head end of the fluoroscopic table may need to be raised to facilitate flow of contrast through the ureter. Films are taken under fluoroscopic control to demonstrate the course of ureter.

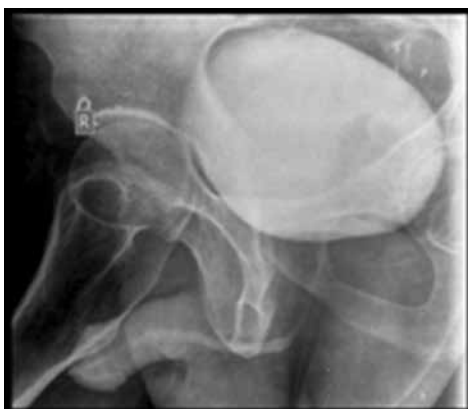

**Fig. 69: Nephrostogram**





## Cystography and Micturating Cysto-Urethrography (MCU) / Voiding Cystourethrography (VCUG)



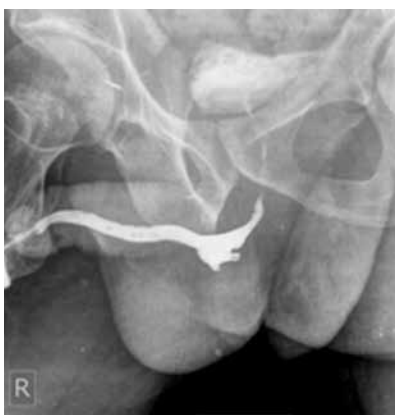**Fig. 70 - Voiding cystourethrogram**

Patient is supine on the radiography table. Diluted contrast (50% dilution Conray 280) is used. Contrast is instilled via a supra pubic catheter in-situ or via catheter inserted per urethra. Films are taken in AP and both oblique positions to demonstrate the urinary bladder.

If an obstructive disease at the level of urethra is suspected or evaluation for vesicoureteric reflux is required, VCUG is performed in which the patient is asked to micturate while lying on the table. Films are taken under fluoroscopy during micturition as the contrast fills the urethra. Post-voiding films are taken to assess the residual urine in the bladder.

## Retrograde Urethrography (RGU)

When the patient is unable to micturate due to urethral obstruction, the anterior urethra is delineated by injecting contrast through a catheter whose tip is positioned in the distal tip of the urethra. Alternatively a Foley's catheter with its bulb inflated in the navicular fossa is used to instill the contrast. Contrast is injected under fluoroscopy and films are taken in oblique positions to show the anatomy of penile and bulbar urethra.



**Fig. 71: Retrograde urethrography**



## 2) Biliary Tract

The biliary tract, comprises of the Gall Bladder, intra hepatic Biliary Radicals and extra hepatic bile ducts. Contrast studies needed to radio graphically study the biliary system to diagnosis various disease conditions are:

- (1) Percutaneous Trans hepatic Cholangiography (PTC)
- (2) Endoscopic Retrograde Cholangio Pancreaticography (ERCP)
- (3) Per Operative Cholangiography
- (4) T-tube Cholangiography

With the introduction of Ultra-Sonography, the initial modality for evaluating the Biliary tract is Ultrasound, which is non invasive and non-radiating.

### Radiological Investigation of Biliary Tract

#### Oral Cholecystography – (OCG)

In modern Radiology practice there is no role of the OCG which was used for demonstrating gall stones in the Gall Bladder in the past. It has been replaced by Ultrasound which is much simpler, safer, non-ionizing, quicker and more accurate. The contrast is given orally in the form of tablets, which is excreted through bile and reaches the gall bladder.

#### Intravenous Cholangiography (IVC)

This procedure requires the use of Intravenous contrast medium to opacify the Biliary Tree. It has been now abandoned because of high chances of developing contrast reactions and availability of better alternative techniques for evaluation of biliary system.

#### Direct Cholangiography Techniques

- i) PTC &
- ii) ERCP

Although they are still the most sensitive methods for demonstrating the nature and extent of Biliary pathology, use of direct cholangiography appears to be declining due to its invasive nature. Simultaneously development of Ultrasound, CT and MR Imaging, the biliary tract is noninvasively studied by these techniques.

Because of the risk of complications, discomfort and the limitation of availability and cost PTC and ERCP these techniques are used after non invasive technique like USG and MRI confirm obstruction of the biliary tract and require intervention like removal of stone from the common bile duct, need for biopsy or biliary drainage in patients with malignant obstruction is required.



## Percutaneous Transhepatic Cholangiography (PTC)

### Patient Preparation

1. Six-eight hours fasting is required before examination;
2. Hemoglobin, Prothrombin time, and Platelet count are checked. Any indication for increased risk of bleeding is corrected.
3. Prophylactic antibiotics is given 24 hours before and continued for 3 days after the procedure.

### Procedure

Patient is asked to lie supine on the x-ray table. Taking aseptic precautions, Chiba needle is introduced through a skin puncture in mid axillary line. Into a central intrahepatic duct under fluoroscopic or ultrasound guidance directly through the liver substance. About 20-40 ml, water soluble iodinated contrast is injected to fill the dilated biliary radicles. Patient position is adjusted to fill all the ducts. The needle is withdrawn and films are taken in supine, prone, oblique and erect positions. Vitals i.e. pulse, respiratory rate and BP is checked and recorded. Patient is restrained in bed for 24 hours.

### Complications

1. Infections / Septicemia
2. Bleeding at the site of liver puncture
3. Bile leakage into peritoneal cavity
4. Hypertension

## Endoscopic Retrograde Cholangio-Pancreatography (ERCP)

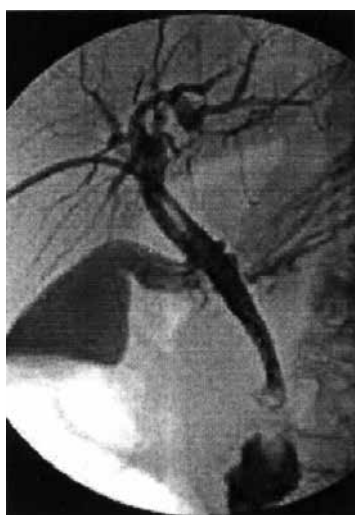

Fig. 72: ERCP – Endoscope in situ with contrast filling CBD and pancreatic ducts



## Patients Preparation and Technique

This procedure is used to image the obstructed biliary or pancreatic ducts by opacifying with iodinated contrast. It accurately shows the level, extent and cause of obstruction and is considered to be the gold standard investigation in cases of dilated biliary tract. The patient should be fasting for 6 hours. ERCP is performed under conscious sedation with the patient lying almost prone on a fluoroscopy table.

An endoscope is passed into the duodenum and a 5F Endoscopic cannula is guided into either the bile duct or pancreatic duct through the papilla of the Vater, depending upon the indication.

For Pancreaticography high-density water soluble contrast medium is used while for the bile ducts less contrast medium is used so as not to obscure the gall stones.

Patient is turned to obtain optimum views of the duct under fluoroscopy so as to prevent the endoscope from obscuring contrast filled ductal system.

## Complications

1. Acute Pancreatitis.
2. Risk of upper Gastrointestinal endoscopy e.g. perforation of esophagus and cross infection.

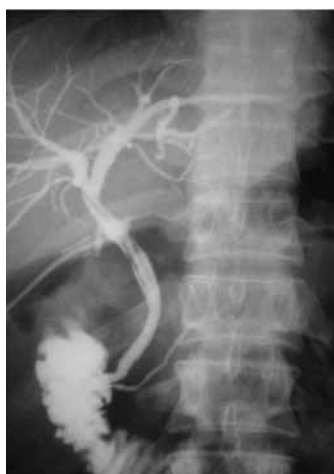## Per Operative Cholangiography

This examination is performed during cholecystectomy to evaluate any suspected calculus in the CBD. The diluted contrast is injected via a thin polythene catheter into the exposed cystic duct after cholecystectomy by the surgeon to opacify the CBD. Care is taken to avoid injecting air bubbles into the CBD which may be confused with stones, Radiographs are taken. In AP position with centering over Right Hypochondrium. Short exposures films are taken and processed immediately to decide whether further CBD exploration is required or not.

## T-Tube Cholangiography

This examination is done 7-10 days after cholecystectomy in cases where the T-Tube is placed in the CBD. The purpose of the examination is to assess whether any residual calculi are present in the biliary system and whether the biliary system is patent, before the drainage tube is removed.

Under fluoroscopic control - The T-Tube is clamped and diluted Conray-280 is injected into it proximal to be clamp. Care is taken to avoid introducing air bubbles into the CBD. The ductal anatomy and the drainage of the contrast into the duodenum is demonstrated on the films taken subsequently in left oblique position. Immediate contrast passage into the duodenum rules out any residual obstruction.



**Fig. 73: T-Tube Cholangiogram**

### 3) Radiological Investigation of the Gastrointestinal Tract

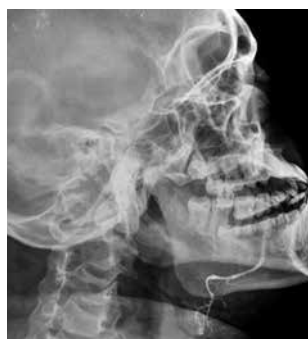The GI tract consists of the oesophagus, stomach, duodenum, small intestine and large intestine. A numerous radiological techniques are available for the evaluation of the GI tract. Traditionally barium studies are used to study the diseased portions and are named according to the part of the GI tract studied.

–	A radiographic study of the salivary Glands	–	Sialography
–	A radiographic study of the oesophagus	–	Barium Swallow
–	A radiographic study of stomach and duodenum	–	Barium Meal
–	A radiographic study of the small intestine	–	Barium Meal Follow Through
–	A radiographic study of the large intestine	–	Barium Enema

#### Sialography

Sialography is the radiographic study of the salivary glands and ducts after injection of contrast medium into the salivary duct.

The parotid gland can be examined by injecting the contrast medium in the Stenson's duct and submandibular gland by injecting the contrast in Whart on's duct.



**Fig. 74: Sialography of right submandibular gland**





**Contrast medium** – Conray 280 or Urografin 60% - 2ml

**Equipment** – Punctum dilator, lacrimal cannula or catheter, syringe, lemon/citric acid.

**Preparation** – Remove all radioopaque artifacts e.g. dentures, ear rings and hairpins from the area of interest

### Scout films

#### 1. For parotid

AP with face tilted 5° away from side of evaluation.

Lateral oblique with 20° cephalad tilt of tube, centering over angle of mandible.

#### 2. For submandibular gland

Infero superior view using occlusal film

Lateral with floor of mouth depressed with a wooden spatula

Lateral oblique as for parotid, centering 1cm anterior to angle of mandible

### Barium Swallow

The radiographic evaluation of the hypopharynx and oesophagus is called a barium swallow. The entire length of the oesophagus upto the gastro-esophageal junction where it joins the stomach is studied for its position, length, lumen calibre and peristaltic portion.

#### Preparation

No patient preparation is needed

#### Procedure

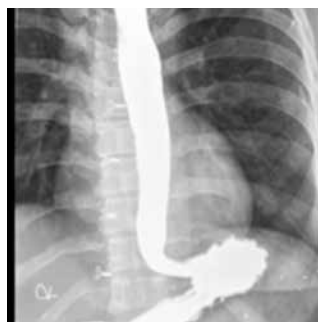##### Single Contrast study

1. Barium swallow is performed under fluoroscopy as the patient swallows the barium suspension.
2. The patient is given a mouthful of thick paste of barium sulphate to swallow and films are taken under fluoroscopy.
3. AP and Lateral views are taken separately for the hypopharynx and cervical oesophagus.
4. The act of swallowing and peristaltic activity is noted.
5. Oblique films are taken for thoracic esophagus with the arms raised above the head. Patient is asked to hold his/her breath before exposing the X-ray films for the thoracic esophagus to prevent motion blurr.
6. Both full column films, (i.e. with the esophagus fully distended with barium) and mucosal relief films (taken when the bolus of barium has passed down) are taken in every case.





7. The gastro esophageal junction is studied for its position and calibre.

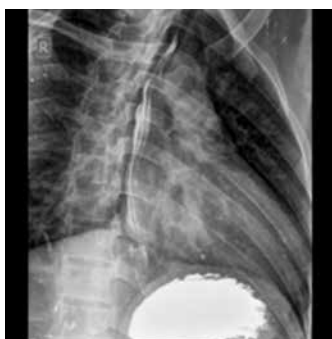

**Fig. 75: Single Contrast Barium Swallow Examination**

### Double Contrast Study

The patient is asked to swallow an air producing substance like Gastro vision followed by a bolus of high-density barium and films are taken under fluoroscopy in the erect position.

Patient should be sent away only after all films taken under fluoroscopy have been checked by the radiologist. No other care of the patient is required.



**Fig. 76: Double Contrast Barium Swallow examination**

### Barium Meal

This is performed to evaluate lesions of stomach and duodenum. Single contrast is performed with barium sulphate suspension while in double contrast study the negative contrast provides to view mucosal details.

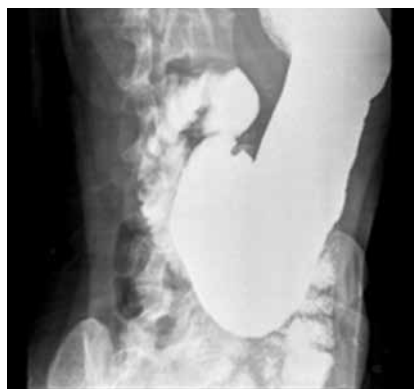**Preparation** – Patient should be nil orally on the morning of examination

### Single Contrast Study

150 – 300 ml of thin barium (95% w/v) is given by mouth and films are taken in different positions under fluoroscopy. Patient is standing with arms raised and both hands folded behind the head. The first film is taken after swallowing only a mouthful of thick barium to study the mucosal pattern of the stomach and duodenum. Then the patient is made to drink the entire quantity of barium and AP, Supine oblique, prone oblique and lateral films are taken for stomach. The radiographer must be informed about the position of the patient before making an exposure.



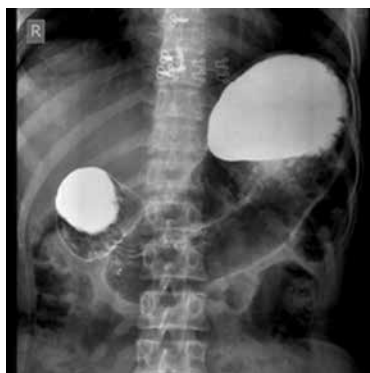Duodenum cap is studied in right and left anterior oblique position, with or without compression, in different phases of peristaltic activity. Spot films for duodenum are taken in RAO, prone, supine and LAO position. Additional views are also taken as and when required. These are essential to document minimal lesions, which are visible on compression films. Peristaltic activity is also studied and any abnormality noted. The sequence of filming and the number of exposures are not fixed and can be varied according to the need of the patient and the choice of the radiologist.



**Fig. 77: Single Contrast upper GI Barium Examination**

### Double Contrast Study

Small amount (100-120ml) of high density barium (150-200% w/v) is given before, along with or after a packet of gas-producing substance like Gastrovision. This releases CO<sub>2</sub> within the stomach and distends it. The patient is then made to turn and roll on the table from side to side a few times so that the mucosa gets uniformly coated and adequate distension occurs. X-rays are then taken under fluoroscopy just as for single contrast study but using lesser kv.



**Fig. 78: Double Contrast upper GI Barium Examination**

**Hypotonic duodenography** – This is the radiographic examination of the duodenal loop in its relaxed state.

This is done by introducing barium through a tube positioned in the duodenum and giving anticholinergic substance like buscopan by injection. Tubeless hypotonic duodenography can also be performed without putting the tube by giving barium orally with gas-producing agents.



All peristaltic activity ceases and mucosal detail of the duodenum can be studied along with abnormalities of contour of the head of pancreas.

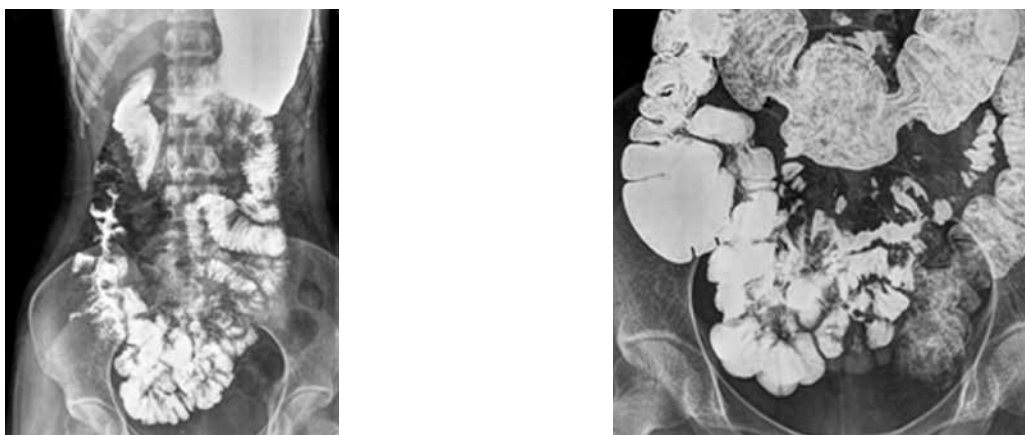
### Barium Meal Follow Through Study

This radiographic examination is needed to study the entire small intestine from the duodeno-jejunal flexure to the ileocaecal valve.

**Patient Preparation** – The patient is asked to report to the X-ray department fasting, on the morning of examination. The patient is informed at the time of booking his appointment for this examination that this procedure may take more than 12 hours and that he should come adequately prepared with lunch etc.

**Method** – About 400ml of Barium sulphate (90% w/v) is given to the patient to drink. Time of ingestion of barium is noted. First X-rays are usually taken at 15 minutes after the patient drinks barium. Further intervals of taking films of the abdomen can be varied, combined with intermittent fluoroscopy in between, from 30 to 60 minutes. Films of the jejunum, ileum and ileocaecal junction should be taken to complete the series. The time at which the films are taken must be marked on the corner of the film for evaluation of transit time.

After the stomach empties itself, food can be given to the patient to propel the barium further in the intestines. Sometimes the drug metoclopropamide is used to hasten the gastric emptying. Fluoroscopy may be needed for clear delineation of the ileocaecal junction.

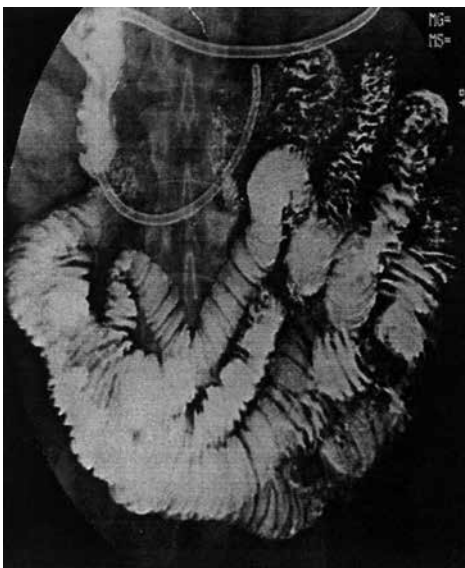

**Fig. 79: Barium meal follows through**  
a) Showing the jejunal and ileal loops b) The ileocaecal junction

**Small Bowel Enema/Enteroclysis** – It is the procedure in which the contrast medium is directly instilled into jejunum through a tube positioned beyond the duodeno-jejunal flexure. It is usually performed as a double-contrast technique. This study is advantageous because it shows the small bowel loops in their continuity; they are not overlapped by stomach. The procedure is faster than barium meal follow through study. Use of dilute barium followed by



infusion of methyl cellulose/water give double contrast effect in the small bowel enema examination.

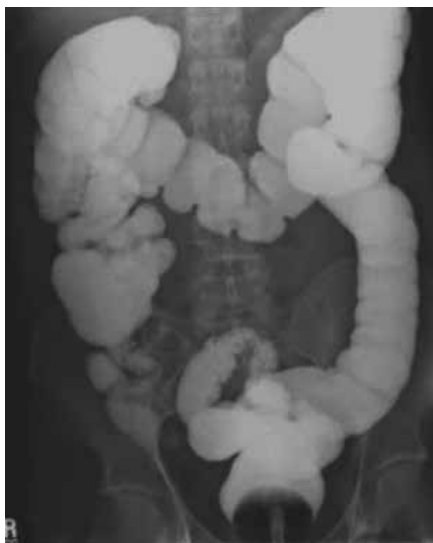

**Fig. 80: Small Bowel Enema examination**

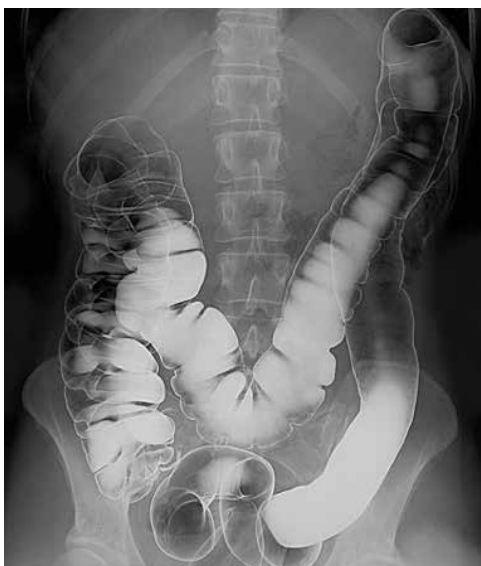The radiologist follows the barium column carefully under fluoroscopy and spot radiographs are taken at appropriate times.

### Barium Enema

This is an examination of the entire large bowel using barium by the single-contrast or double-contrast method.



**Fig. 81: Single Contrast Barium Enema**



**Fig. 82: Double Contrast Barium Enema**

### Patient preparation

The large bowel should be completely empty of faecal matter which is accomplished by cleansing enema/bowel wash given 2-4 hours prior to the study and or purgatives on the day before the study and by use of low residue diet for a couple of days before the study. A scout film of the abdomen is taken before commencing the study to check for bowel preparation.

**Technique** – The procedure must be explained to the patient. He is instructed to retain the rectal tube and report as soon as he feels it is not in position. Patient should take deep breaths during tube insertion and follow instructions given for turning or breath-holding by the radiologist.

**Single Contrast Study** – A lubricated rectal tube or ‘Foley’s catheter’ is introduced per anus and barium suspension is instilled to fill the colon. Filming is done for separate regions of the intestine in various oblique positions including a lateral view for the rectum and pre sacral space under fluoroscopy. Post evacuation films are also taken.

**Double Contrast Study** – 300-500ml High density (100% w/v) barium is instilled till just beyond the splenic flexure in the prone head-down position and propelled further by air insufflations, thus giving a double-contrast to the colon. In the head-up position barium column is brought into the mid transverse colon and the rectum is drained. Then the patient is turned so that barium cascades around the hepatic flexure. Finally the patient is made head-up and barium falls into the dependent caecum. Rest of the barium is drained from the rectum and air may be insufflated to achieve the best possible mucosal coating and lumen distension. A series of spot and over head films are taken in prone, oblique, erect, lateral and lateral decubitus positions. Double contrast studies are invaluable for the study of polyposis, ulcerative disease and malignant lesions.





#### 4) Circulatory System – Angiography

The radiological study of cardiovascular system of body by injecting iodinated contrast medium for its visualization is called Angiography. It includes arteriography, cardiac angiography, venography and lymphangiography.

As the blood flows at a very high speed, the contrast gets cleared of very rapidly. Therefore, the injection as well as the filming needs to be done simultaneously using automatic injector and rapid filming sequence. Rapid film changer or cine radiography devices with videotape facility which permit rapid sequence exposures at the rate of 3-13 per sec (60/sec in cine-fluoroscopy) are required. These machines have to be high mA machines with focal spots that can withstand high temperature loads. Contrast injection with Automatic pressure injectors is also rapid which synchronizes injection with the filming sequence. There should also be ECG, heart rate and BP monitoring devices; emergency resuscitation equipments and machines should also be accessible.

##### Arteriography

Angiography means visualization of arteries by injecting contrast medium directly within their lumen. This contrast study is performed to visualize the arteries themselves, and the organs supplied by them. This procedure usually forms the bases for interventional procedures to treat most of the vascular diseases.

Arteriography procedures are named according to the region under study e.g. Carotid, femoral angiography, aortography etc.

Contrast medium – Conray 280 or Angiografin may be used. Non-ionic low osmolar contrast media are safer and are therefore used more often at present times.

**Preparation** – Fasting 4-6 hours prior to study.

##### Technique

**Preparation of catheterization site** – shaving and cleaning with antiseptic solutions is done over the selected vessels. Usually the femoral artery is catheterized by Seldinger's technique.

Patient lies supine on the x-ray table. Both femoral arteries are palpated and the easier or the right side is selected for puncture. The appropriate catheters and guide wire are selected and their compatibility checked by putting the guide wire through catheter and needle before making the puncture.

Using aseptic technique, local anesthesia is infiltrated at the site of injection. Artery is immobilized by placing index and middle finger of left hand on either side of artery and needle held with right hand. Both walls of artery are punctured with a stab. The stilet is removed and needle is slowly withdrawn until a gush of blood is seen to flow from the needle which indicates a satisfactory puncture.





A vascular sheath is placed over the puncture needle.

A long guide wire is then introduced through the sheath and pushed along the vessel to the required position.

Then the catheter is threaded on the guide wire and positioned wherever required under fluoroscopic guidance.

Guide wire is withdrawn and the end of the catheter connected to a syringe filled with heparinised saline.

### Complications

**Local puncture site** – hematoma, arterial spasm, thrombosis, sub-intimal dissection.

**Distant to puncture site** – embolism, thrombosis, septicemia, perforation, guide wire/catheter tip fractures.

**Due to contrast reaction** – Toxic and hypersensitivity reaction.

### Carotid Angiography

It is used to demonstrate the abnormalities and displacement of vessels in and around the brain. The catheter is positioned in the carotid artery from a femoral puncture. Preliminary films of skull are taken in AP, lateral and Towne's position after removing all artifacts.

After injection of 10-20 ml of contrast by fast hand-injection/pressure injectors, 3-5 films/second are taken for 1 sec, followed by 1 exposure/second for the next 2 sec. Films are taken in AP, lateral and Towne's position just as for preliminary films.

Subtraction, if available is valuable in visualizing the vascular pattern.

Digital Subtraction Angiography (DSA) allows better images to be taken with use of smaller doses of contrast medium.

### Femoral Arteriography

It is done by injecting the contrast into the external iliac artery or even higher at the level of aortic bifurcation when simultaneous, evaluation of both sides is required.

When good flow is obtained, the guide wire is inserted through the needle and advanced up to the entry using fluoroscopy to follow its travel.

The tip of the pigtail catheter is positioned in lower abdominal or lumbar aorta at L 3-4 level and 50-70 ml of contrast is injected at the rate of 8-12 ml/second. The radiographs are taken at the rate of 1/sec for 8 seconds and then at every alternate second for 12-20 second.

Projections are taken in two planes so that the arterial anatomy is shown clear from the underlying bones.



Subtraction films may be required to subtract the images of bones from the final films.

Aortography, Renal angiography, selective arteriography etc. are other commonly performed angiographies with a catheter placed in the artery of interest.

### Phlebography/Venography

Lower limb venography is the technique in which contrast medium is injected into one of the tributaries of lower limb venous to visualize superficial/deep system of veins draining the lower limb. It is usually done for varicose veins, deep venous thrombosis or even IVC thrombosis.

**Patient preparation** – Fasting for 4-6 hours prior to study. If the limb to be examined is edematous, it is elevated to reduce edema and facilitate puncture.

#### Procedure

1. Patient lies supine on the table with 20-40° foot down tilt. A tourniquet is applied above ankle. Skin on the dorsum of foot is cleaned and under aseptic conditions a 21G butterfly needle is inserted into a distal vein on dorsum of foot and attached to a saline syringe.
2. A second above-knee tourniquet is applied to occlude superficial venous system and promote the filling of deep venous system.
3. Saline syringe is replaced by syringe with 60 ml of contrast.
4. With table 20-40° in foot down position contrast is injected under fluoroscopic control. These exposures are made in AP position for views from ankle to knee. Separate exposures are made in lateral position for calf veins.
5. Leg is brought to AP position and above knee tourniquet is removed.
6. Contrast reaches superficial and common femoral veins. Skiagrams of this area are taken. A last film of groin and pelvis is taken after removal of tourniquet.
7. Veins are cleared of contrast medium by elevation of leg and injection of normal saline.

## 5) Central Nervous System

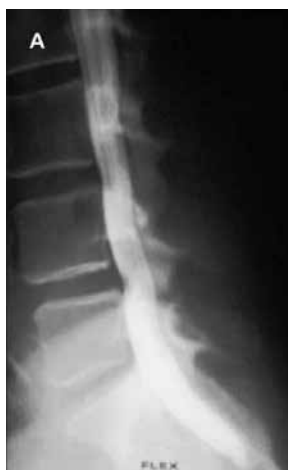### Myelography

Myelography is a contrast investigation carried out for visualization of contents of the spinal thecal sac. In present times it has been replaced by MRI and CT myelography. It is still performed where these modalities are not feasible or available.

Myelography is performed by instilling nonionic water soluble contrast into the subarachnoid space either by lumbar puncture between L3-L4 or by cisternal puncture performed between occipital and atlas (C1 vertebra). Location and extent of lesions like herniated intervertebral disc, cord tumors can be demonstrated. Water soluble non-ionic contrast media like iopamidol,



iohexol etc. are mostly used nowadays. Myodil (oil-based contrast) and metrizamide are not used any more.



**Fig. 83: Lumbar Myelogram**

### Technique

1. Lumbar/cisternal is done under aseptic condition using a (20 gauge) spinal needle and contrast is instilled into the subarachnoid space after free flow of CSF is observed through the needle.
2. The needle is then withdrawn and puncture site is sealed and the patient appropriately positioned for the radiograph.
3. Oblique views are also taken of the region of interest. Flexion or extension if required by the radiologist and lateral projection are taken.  
Erect views may be required to delineate the lower extent of the cul de sac.  
Case should be taken to keep the head elevated throughout and after the procedure to prevent contrast medium from flowing into the CSF space of brain.
4. The flow of contrast column is observed under fluoroscopy and positioned in the region of interest by changing the patient position. Spot radiographs are taken at the level of blockage or distortion in the contrast column. Both frontal supine or prone and lateral radiographs are taken or desired according to the case by the radiologist. The cross table projections are made with grid front cassettes or a stationary grid.
5. After the procedure is done the patient is shifted to the ward on the trolley with the neck flexed for observation. Any hypotension, headache or acute back or limb pain should be reported to the referring clinician.

## 6) Miscellaneous Diagnostic Procedures

Special investigation using contrast mediums are also available for other organ systems of the body. For example hysterosalpingography is a radiological study of the female genital tracts



i.e. uterus and fallopian tubes; Arthorgraphy is for joints; Bronchography is for bronchial tree; Dacryocystography (DCG) is a study of the lacrimal system. Sinogram and Fistulograms are performed by installing contrast medium into an abnormal body surface opening for showing the abnormal tract which ends blindly or is in communication with the underlying hollow viscera or organ.

- |                           |                              |
|---------------------------|------------------------------|
| (1) Hysterosalpingography | (2) Sinogram and Fistulogram |
| (3) Dacryocystography     | (4) Arthrography             |
| (5) Loopogram             | (6) Bronchography            |

### Hysterosalpingography (HSG)

In the present times Ultrasound has almost replaced conventional radiology for practically all obstetric and gynecological pelvic diseases. The only indication of doing a Hyserosalpingogram, is in the investigation of the infertile patients for evaluation of the fallopian tube patency.

HSG involves introduction of the contrast medium into the uterine cavity and delineates the anatomy of the endometrial cavity and the luminal details of the fallopian tubes and their patency.

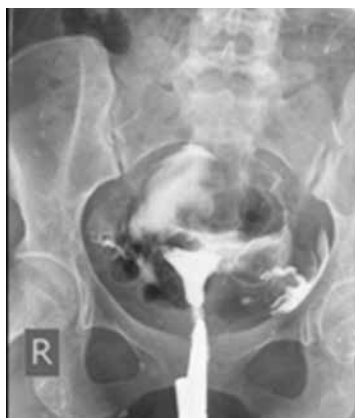#### Prerequisite

Examination should be performed during 7-10 days after the last menstrual period (LMP) to avoid dislodgement/radiation to an early pregnancy.

- (1) Preliminary film is avoided to prevent unnecessary radiation exposure of the ovaries in females with infertility.
- (2) Active cervical/vaginal discharge or infection is ruled out before starting the procedure
- (3) Diazepam is given a night before the procedure in anxious patient.
- (4) Patient should void immediately before the radiological examination.

**Technique** – A gynaecological examination is done prior to cannulating the cervix. In the presence of any signs of infection, HSG is abandoned. The cervix is cannulated under all aseptic precautions using a metallic cannula or a foley's catheter. The Foley's bulb is partially inflated in the cervical canal. The diluted water soluble iodinated contrast (60% urografin) is loaded in a syringe and attached to the cannunla/catheters. The contrast material is now injected under fluoroscopy slowly and is allowed to fill the uterus and the tubes until free peritoneal spill is observed. An exposure is made under fluoroscopy to assess the uterus and tubes, and another exposure is made to document free peritoneal spill of contrast through the tubes if they are patent. If the patient has pain during the procedure and the fallopian are not visualized, injection Buscopan may be given i.v. for relieving tubal spasm immediately.

Analgesics, antibiotics and anti inflammatory drugs are prescribed to the patient before she leaves the radiography room.



**Fig. 84: Hysterosalpingography**

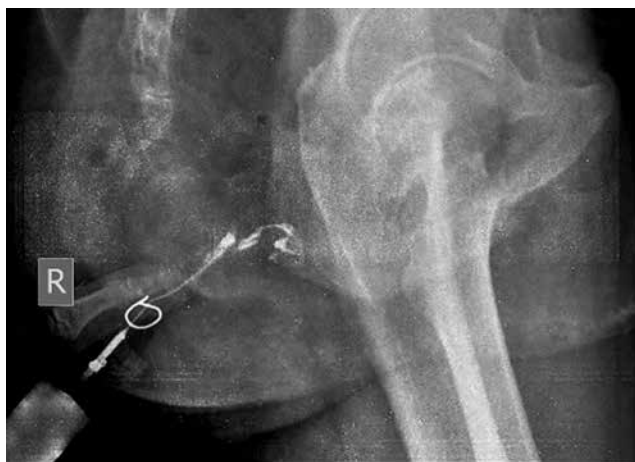### Sinography/Fistulography

In this procedure, the abnormal skin opening is cannulated for instillation of water-soluble contrast. If a blind tract is visualized the study is referred to as a Sinogram. If the visualized tract is seen to communicate with a hollow viscus e.g. bladder or bowel, the tract is referred to as a fistula and the contrast study is called a Fistulogram.

The preliminary plain film is taken with a metallic marker placed at the site of the external opening to identify its position on the radiograph.

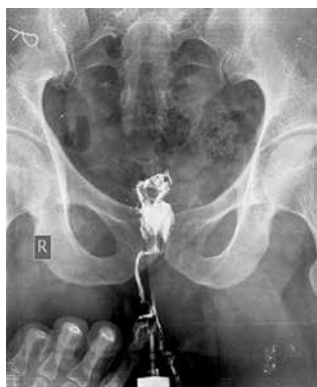Water-soluble contrast is instilled under all aseptic precautions via a fine catheter placed in the orifice, and the Spot radiograph AP, Lateral or oblique are taken to delineate the tract.

Complications like bleeding from the tract may occur due to probing by the catheter. The procedure abandoned in this situation.



**Fig. 85: Sinogram**





**Fig. 86: Fistulogram**

### **Dacryo Cystography (DCG)**

This is the radiographic investigation of lacrimal system following injection of contrast to look for the site and degree of obstruction in cases of suspected obstructive epiphora i.e. watering from eye due to obstruction to its drainage system.

No patient preparation or pre medication is required and 2-5 ml of Conray-280 is adequate for instillation.

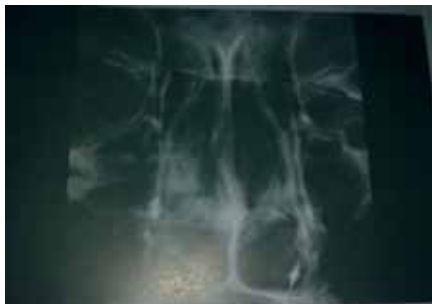**Preliminary film** – Occipito mental and lateral views of paranasal sinuses are made before the cannulation to confirm proper positioning and exposure factors for the investigation.

#### **Technique**

Lower eyelid is everted to locate the lower punctum at the medial and of the lid after putting local anesthetic in the eye. Punctum is dilated and a smallest size (No. 25-26) cannula is inserted. The contrast is instilled very slowly and radiographs taken immediately afterwards or during the instillation. If there is no regurgitation of contrast the patient can feel the contrast entering the throat due to its bitter taste. Films are checked and repeated, if necessary.

The same occipitomental and lateral views are taken as the scout images.

Macro dacryocystography is obtained by using x-ray tube 0.3 cm focal spot to cause geometrical enlargement of the part radiographed.



**Fig. 87: Dacrocystography**





## Arthrography

It is the radiographic examination of the synovial joints to demonstrate its internal anatomy by using single or double contrast technique. Although any synovial joint can be evaluated, it is usually done for hip, knee and shoulder.

### Contrast Medium

**Water soluble ionic contrast** - Conray 280/Urograffin 60% is appropriate for the study. A volume of 4 ml-10ml water soluble ionic contrast is adequate depending on the joint to be studied. Air is used for providing the contrast in a double contrast study.

Sometimes only air is used to delineate the synovial cavity. The examination is then called pneumo-arthrography.

### Technique

Preliminary film taken before injecting contrast are –

1. Shoulder joint - AP view and lateral view. Additional views like axial and Stryker's views may be required for evaluation of recurrent dislocation.
2. Knee Joint – AP and Lateral view
3. Hip Joint – AP and Lateral view

Under local anesthetics & taking all aseptic precautions a needle is introduced into the joint space. In cases of synovial infection, fluid is aspirated and contrast medium followed by air is injected. The joint is gently exercised to allow even distribution of contrast.

Films to be taken are similar to the preliminary films. For knee joint additional stress films are taken under fluoroscopic control to evaluate for meniscal and ligamentous injuries.

### Loopogram

Contrast study of the distal bowel loop in a patient with ileostomy/colostomy (i.e. the ileum/colon) opening on the surface of the abdomen is done to evaluate its patency before the surgical reversal. Besides the patency of the distal loop, leakage from the bowel is also noted. The foleys catheter is placed in the opening, the Foleys bulb inflated to block the opening and diluted water soluble contrast is instilled through it. The passage of the contrast is seen under fluoroscopic control till the entire distal bowel loop is opacified. Spot films of the region and over couch films of the entire abdomen are taken.

Half an hour delayed films may be useful for demonstration of intra articular loose bodies.

### Bronchography

It is the radiographic examination of the bronchial tree following the administration of non-ionic



water soluble iodinated contrast medium. It was mainly done for the investigation of bronchiectasis and to establish the cause of hemoptysis when other investigations are negative.

Contrast Medium Iohexol 12 ml/side for adults, and 1ml/year/side for children

### **Prerequisite**

Chest physiotherapy 3 days before the examinations. Antibiotic treatment if required.

### **Technique**

After the pharynx and larynx is sprayed with the local anesthetic, a polythene catheter is introduced through the nostril or introduced through puncture of cricothyroid membrane into the major bronchus of the lobe to be studied, using bronchoscopic technique if available. Contrast is injected under fluoroscopic control and patient positioned so that the area to be studied fills with contrast. Chest PA view, lateral view (Right or Left) and 45° oblique films are taken (Right or Left).

Adequate After care is given by encouraging the patient to cough and practice chest physiotherapy. Patient is kept nil orally till anesthetic effect passes off.

**Complications** – Bronchospasm during the procedure.

### **Review Questions**

- Q 1. What is the full form of IVU?
- Q 2. How will you prepare a patient for IVU?
- Q 3. What are the contraindications for IVU?
- Q 4. What are the contraindications for the use of binder in IVU?
- Q 5. How many films are taken in IVU, elaborate?
- Q 6. RGP stands for?
- Q 7. What are the contraindications of RGP?
- Q 8. What is AGP? How it is Performed?
- Q 9. What is VCUR/MCU? What are Indications for it.
- Q 10. What is RGU?
- Q 11. What are various techniques for cholangiography?. Describe briefly.
- Q 12. How will you prepare a patient for PTC?
- Q 13. How will you prepare a patient for ERCP?
- Q 14. What is Myelography? What Precautions one must take after myelography.
- Q 15. What is arteriography? Describe the technique of arteriography.
- Q 16. Describe the technique of venography?



- Q 17. What does DSA stands for?
- Q 18. A radiographic study of oesophagus is called as .....?
- Q 19. A radiographic study of small intestine is called as .....?
- Q 20. What is barium meal study? How it is performed?
- Q 21. What is the difference between barium meals follow through and enteroclysis?
- Q 22. How will you prepare the patient for barium enema?
- Q 23. Discuss the procedure of hysterosalpingography?
- Q 24. What are the pre procedural and post procedural precautions to be taken for HSG?
- Q 25. What are the correct time of menstrual cycle to perform HSG?
- Q 26. DCG stands for? What is the indication for procedure?
- Q 27. What is the contrast and its amount used in broncography?
- Q 28. What is Pneumoarthrography?
- Q 29. Which contrast media is used in arthrography and its amount?
- Q 30. What is a sinus? How it is different from a fistula?



## Chapter-3

# Contrast Media Used in Radiology and Imaging

### Introduction

In diagnostic radiology, contrast media for x-ray are either negative such as air, oxygen and carbon-dioxide or positive media such as barium sulfate ( $\text{BaSO}_4$ ) or iodinated contrast media. These contrast media are also used in CT examination.

Agitated micro air bubbles are used to increase the ultrasound contrast. In MRI paramagnetic water soluble contrast media are used.

*Objectives – After going through this chapter you will be able to*

- Enlist different type of contrast media
- Classify contrast media
- Discuss characteristic of good contrast media
- Recognise adverse reaction of contract media
- Initiate appropriate treatment for management of adverse reactions
- Take appropriate measures for presenting adverse reactions

### Contrast media used in Radiology

#### Positive

Barium Sulphate

Iodinated contrast media

#### Negative

$\text{CO}_2$

air

### Barium Sulphate

It is an x-ray contrast medium for examination of the gastrointestinal tract. The particles used in barium a relatively uniform size in the range of 0.6-1.4 $\mu\text{m}$ . Barium sulfate is water insoluble and is available either as a powder or as a suspension. Large organic molecules, such as gum Arabic, pectin and methylcarboxycellulose may be added to give the suspension good characteristics such as easy flow, good mucosal adhesion without cracking, high radiographic density in thin layers, and for preventing foaming, antifoaming agents are added as well. The density of the suspension varies with the type of examination. Single contrast barium enemas require low density suspensions (e.g. 0.1-0.2 g/ml), while double-contrast examination of the stomach use medium (0.8-1.0 g/ml) or high density (2.0 -2.5 g/ml) suspensions. When there is a risk of



aspiration or peritoneal contamination, a water-soluble contrast medium should be used instead of barium sulphate.

### Iodinated Water Soluble Contrast Media

Iodine was recognized as an x-ray absorber, i.e. positive x-ray contrast media (CM) as early as 1886. The earliest preparation of iodized CM was iodized oil Lipiodol which caused complications of fat microemboli and foreign body granulomata, therefore they are now obsolete.

Later in 1925, various pyridine compounds containing iodine were used as CM. At the beginning of the 1950s, the change was made from diiodinated pyridine derivatives to benzene with three substituted iodine atoms i.e., triiodinated benzoic acid derivatives. Hydrophilic side groups and the meglumine cation improved the tolerability of the ionic CM considerably, while the third iodine atom bound to the molecule led to higher contrast density.

**The present CM can be classified under four categories:**

1. Ionic monomers, characterized by one triiodobenzene ring containing one carboxyl groups.

**Examples :** Metrizoate (Isopaque), diatrizoate (Urografin)

These can also be used in GIT along with sweetening and stabilizing agents. These commercial preparations are called gastrograffin, gastrovision etc. If these commercial preparations are not available in the market, then these can be prepared in the department by adding the sweetening agents and diluting with water.

2. Ionic monoacid diamers, characterized by two triiodobenzene rings linked together by a carbon-chain bridge, with one of the triiodobenzene groups carrying a carboxyl group.

**Example :** Ioxaglate (Hexabrix)

3. Nonionic monomers, characterized by one triiodobenzene ring carrying more than three hydroxyl groups, with no carboxyl or other ionizing groups.

**Examples :** Iohexol (Omnipaque), Iopamidol (Iopamiro, Niopam), Iopromide (Ultravist), Ioversol (Optiray), Iopentol (Imagopaque)

4. Nonionic diamers, characterized by two triiodobenzene rings linked together by a carbon-chain bridge, carrying several hydroxyl groups and without ionizing groups.

**Example :** Iodixanol (Visipaque), Iotrolan (Isovist). Ionic monomers are called high osmolar contrast media (HOCM). Ionic diamers and nonionic monomers are low osmolar contrast media (LOCM), having almost half the osmolality of the HOCM, but more than that of blood. Monoionic diamers are iso-osmolar to blood.

### Characteristic Properties Desirable in a Good Contrasts Media

1. **Water solubility:** high aqueous solubility without their being any danger of crystal formation in the vials or syringes, or in the body.



2. **Osmolality:** Parenteral injections having osmolality as close to that of blood decreases the chances of toxicity and adverse reactions (AR).
3. **Chemical Stability:** The contrast media should be stable with a long shelf life in years when stored at room temperature. However CM are sensitive when exposed to strong light, high temperature and radiation. EDTA (Ethylene diaminetetraacetic acid) is added as a stabilizing agent.
4. **Viscosity :** For high viscosity solutions it takes longer for the CM to be diluted by blood flow. Heating the CM to body temperature reduced viscosity of the medium up to 50% and improved the ease of injection.
5. **Low toxicity :** This prevents adverse reactions to the contrast media.

These contrast media are used for injection by intravascular route, injection into body cavities such as nephrostogram or, hysterosalpingogram etc. The same CM is used in CT examination. For opacification of the **gastrointestinal tract barium sulfate** preparations are used in x-ray studies. However, for opacification of gastrointestinal tract in CT studies, water-soluble contrast can also be used in appropriate dilutions. Most of these soluble CM are excreted by kidneys, therefore they are not to be injected in patients who have poor renal function.

## Contrast Media Reactions

### A) Minor and Moderate Reactions

1. Severe urticaria, severe vomiting and nausea
2. Severe dyspnea.
3. Bronchospasm
4. Moderate hypotension

### B) Severe Reactions

1. Severe bronchospasm
2. Severe hypotension
3. Edema of glottis
4. Poor circulatory output (by the heart) leading to “shock”
5. Cardiac arrhythmias
6. Cardiac arrest and death





### Treatment of Contrast Media Reactions

	Reaction	Treatment
I	Minor	Reassurance of the patient and injection avil (antihistaminic/antiallergic). If rash occur it is advisable to give a steroid injection also (prednisolone injection up to 500mg or more can be given I/M or I/V depending on the severity).
II	Moderate	For patients with bronchospasm and hypotension, the treatment is to raise the foot end of the patient table and start oxygen immediately with the facemask and start the I/V drip of glucose and give steroids and bronchodilators. For moderate reaction give high doses of prednisolone as high as up to 2000mg can be given along with oxygen.
III	Severe	In severe reactions with bronchospasm and dyspnea always give bronchodilator injections (deriphylline) in the drip along with sodabcarb to over come the acidosis. In severe reactions it may be necessary to give noradrenaline drip along with diuretics to reduce load on the heart.

### Prevention of Adverse Reaction

1. Avoidance in patient with risk factors like renal failure, multiple myeloma and patients with poor liver, cardiac function.
2. Use of safer low osmolar contrast media (LOCM) in high risk patients.
3. Steroids 24 hrs before injection of contrast are useful in patients giving history of allergy
4. Treating doctor should not arouse anxiety or fear.

### MRI Contrast Media

Gadopentate dimeglumine, or GD-DTPA or magnevist. It is a small molecular weight linear CHELATE based on the DTPA molecule, which tightly binds the Gd atom and is widely used as an MR contrast medium. The substance is excreted almost exclusively by the kidneys. There is also an enteral formulation used to contrast enhance bowel structures. Dosage 0.1-0.2 mmol Gd/kg

Another compound used as MRI contrast agent in the gadoterate meglumine, or Gd-DOTA (Dotarem). It is a small molecular weight macrocyclic CHELATE, which tightly binds the Gd atom and is widely used as an MR contrast medium. The substance is almost exclusively excreted through the kidneys. Dosage 0.1 -0.2 mmol Gd/kg bw (Body Weight)

Since MRI contrast media are also excreted by kidneys, the precautions and contraindications for their use are similar to those for water-soluble contrast media in X-ray and CT.



## Ultrasound Contrast Media

These are exogenous substances that alter the echo amplitude in ultrasonography. The altered echo amplitude may be due to changes in the absorption (absorption, ultrasonic), reflection and/or refraction of the ultrasound. Many substances may act as contrast media, e.g. orally ingested fluids (water) may expel gas from the stomach and create an acoustic window to the pancreas. Echo-free fluids, e.g. water or saline may distend body cavities to improve visualization of the luminal walls.

Most of the newer ultrasound contrast media are designed for intravascular use, and are intended to increase Doppler signals from blood or to increase the echogenicity of tissue. The most promising contrast media are based on either gas microbubble solutions or solid particles suspended in solutions or emulsions.

## Drugs Used in X-ray Department

Now a days in diagnostic medical imaging lots of number procedure have to be done some of invasive and some of them non invasive.

During these various procedures lots of complications is to be faced. These complicated procedures use of drugs required for patient preparation, therapeutic applications and for preventing complications of the radiological procedures.

The radiologist are no longer supervising only contrast administration and managing contract reactions but also providing therapies for many diseases. The present imaging dept. thus is equipped with modern imaging equipment's and a large number of drugs that will be required in various invasive and non invasive for management of contrast reaction.

**Medications commonly used in radiology dept. can be dividing in to the following categories.**

- 1) Drugs used in patient preparation.
- 2) Drugs used for optimizing imaging evaluations.
- 3) Drugs affecting coagulation and anti palette.
- 4) Drugs used for patient preparation

**Sedative – Midazolam** – Its short – acting benzodiazepine that's process anxiolytic, amnestic, anti convulsant skeletal muscle relaxant, and sedative properties.

**Dose** – adult dose 1 to 2.5 mg IV and can be repeated every 5 to 10 minutes.

**Local Anesthesia – (LA)** effectively and reversibly block impulse conduction along nerve



axons and other excitable membranes that use sodium channels as the primary means of action potential generation.

### They are of the type

- ◆ **Amino amines Eg** – Lignocain, Bupivacain.
- ◆ **Amino esters** – Procain, Benzocain, Cocain etc.

### Drugs used for optimizing Imaging Evaluation

- ◆ **Diurtics** – Eg. Furasemide used for optimizing urologic diagnostic procedures.
- ◆ **Vasodilators** – They are used angiography and clinical vasospasm.
- ◆ **Diphenhydromine** – used for Urticaris dose – 50 mg orally.  
But sever Urticatia – Cimetidine 300 mg- IV or Ranidine 50 mg by IV slowly.
- ◆ **Epinephrin** – for moderate reacclam  
Epinephrin 1:10000 IV – for sever.
- ◆ **Isotonic Fluid** – for hypotension with techycardic  
Atropine – dose - 0.6 – 1mg replaced every 3-5 minutes up to 3 mg dose. For vasovagal reaction.
- ◆ **Furosemide and Morphine** – for pulmonary edema.

### Contrast agents

- 1) For GIT used :- Barium sulphate into form
  - A) Powder
  - B) Suspension form

**Oral Contrast – PEG** – Polyethylene glycol its C/M and gas producing agents for carbondioxide

### Iodine Contrast based Media

1. Ionic – monomers – Urografin
2. Ionic – dimmers – Hexabrix
3. New ionic monomer – Iohexol
4. Non Ionic monomer – visipaque

### Analgerices Drugs

- ◆ Diclofenac- 75mg/ml.
- ◆ Paracetamole

### Other Adjuvant Drugs

- ◆ Pantoprazole, Ranitidine, Metoclopramide.
- ◆ Furesemide



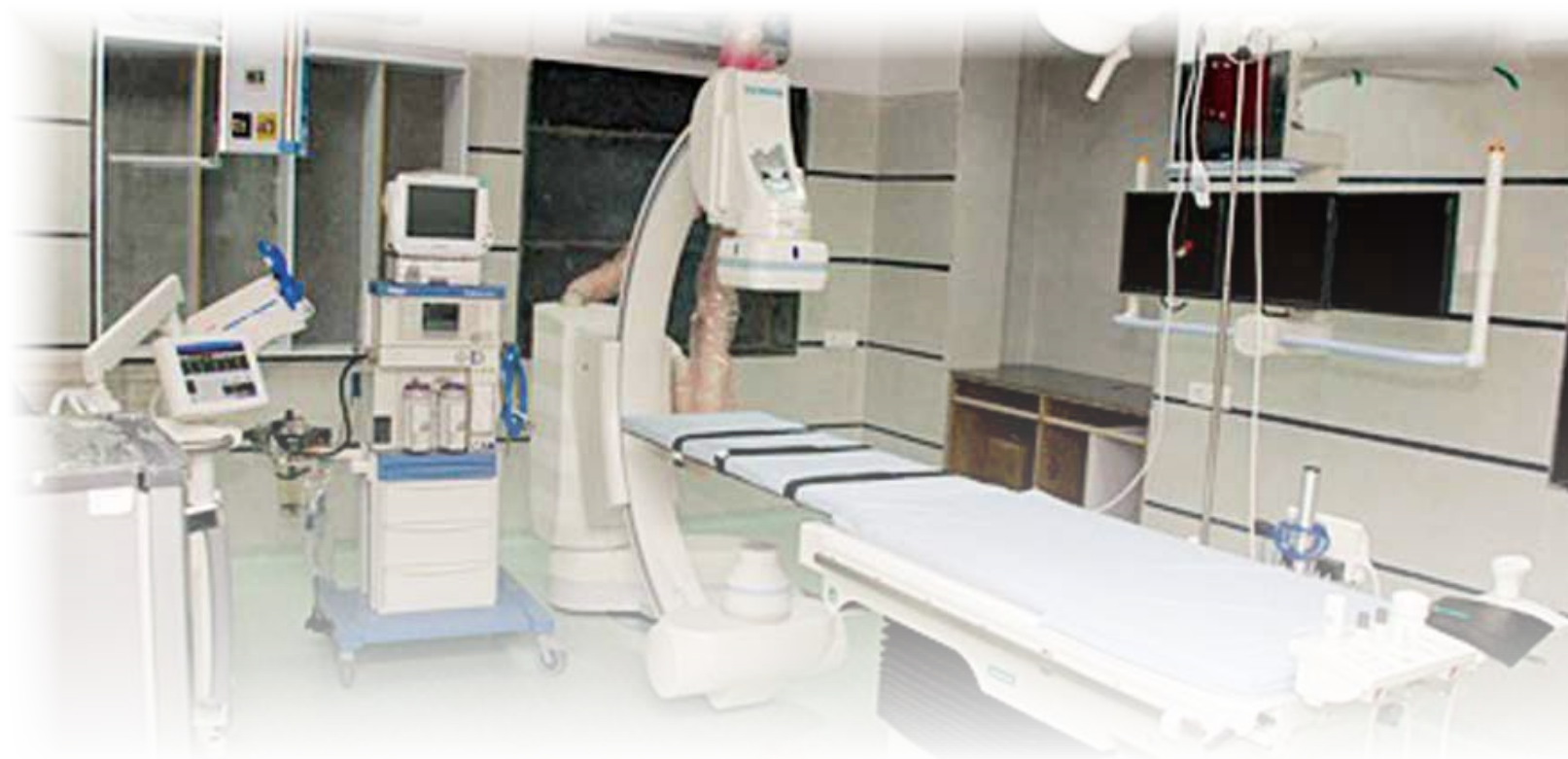## Review Questions

- Q 1. What are the various contrast media used to opacity the gastrointestinal tract?
- Q 2. What are the various types of water soluble contrast media?
- Q 3. What are the contraindications and precautions before injection of water soluble contrast media?
- Q 4. What are the adverse reactions to contrast media and what are their treatments?
- Q 5. What do you know about MRI contrast media?
- Q 6. What do you know about ultrasound contrast media?
- Q 7. Give few examples of positive contrast media?
- Q 8. What are the mild adverse reaction of contrast media?
- Q 9. What are the moderate adverse reaction of contrast media?
- Q 10. What are the various Drugs used is x-ray Department?



## MODULE - VI

# *Various Imaging Modalities and Recent Advances*







## Chapter-1

# Ultrasound and Applied aspect of sonography

### Introduction:

Ultrasonography is a non-ionizing diagnostic imaging technique with high frequency sound waves which allows evaluations of various organs without giving any radiation to the patients.

In this chapter we will learn the basic principle of Ultrasonography and its uses in diagnostic images.

**Objectives - After studying the chapter the students will be able to :**

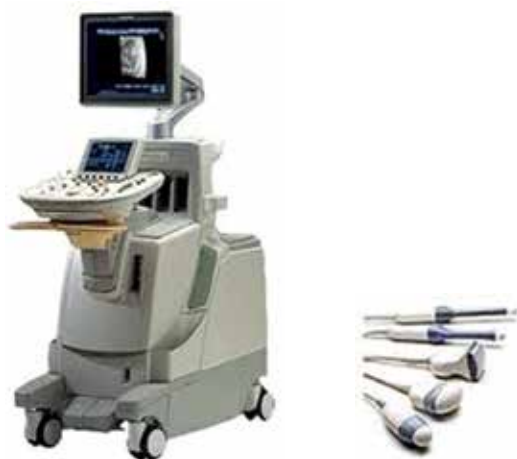- ➔ Explain the principle of ultrasonography
- ➔ List the types of USG and differentiate between them
- ➔ Identify various types of probes and their uses
- ➔ Discuss the clinical application of USG
- ➔ List the advantage and disadvantage of USG

### Ultrasound and Applied Aspect of Sonography

A human being can hear the sound waves between 20 Hz to 20 KHz & vibrations with frequencies higher than 20 KHz are termed ultrasonic. These ultrasonic beams used in diagnostic imaging have frequencies ranging from 2 MHz – 15 MHz

1 MHZ = 1000 KHZ

### Ultrasound Machine:



USG Machine and Probes





Ultrasound machine looks like a desk top computer with various probes attached to it. These probes are of different frequencies and used for different purpose.

Higher the frequency better is the resolution but poor penetration into the soft tissue. A balance between resolution and penetration is required

These probes are made up of a specific type of piezoelectric crystal.

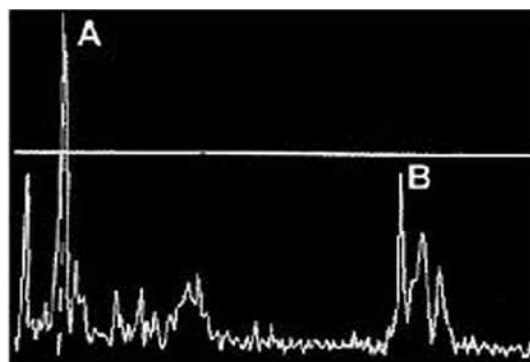
### Principle of Ultrasound

Ultrasound waves are generated from piezoelectric crystals (like zirconate titanate) that vibrates when compressed and decompressed by an alternating current applied across the crystal. These high frequency sound waves travel in straight lines like electromagnetic beams in body. These waves are partly reflected and partly transmitted between different tissue interfaces. These reflected waves are detected by the same crystal and converted into electric impulse which are amplified and displayed on TV monitor and can also be photographed. The remaining transmitted wave goes deeper and again reflected from the tissue interfaces and again read by the crystal. Ultrasound waves are almost completely reflected at interfaces with gas and bone and thus are poor in imaging gas containing organs and bony structures. Ultrasound is ideal in differentiating solid from cystic structures.

Four different modes of ultrasound are used in medical imaging. These are

**A Mode:- (Amplitude Modulation) :** This is the simplest type of ultrasound. The received energy at a certain time i.e. from a certain depth can be displayed as energy amplitude. The greater the reflection at the interface, the larger the signal amplitude will appear on the A mode screen.

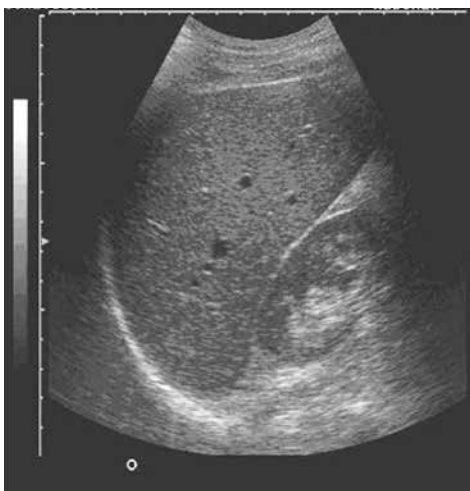This is used in ocular (eye) ultrasound by ophthalmologists.



A Mode Usg

### Mode :- (Brightness) :

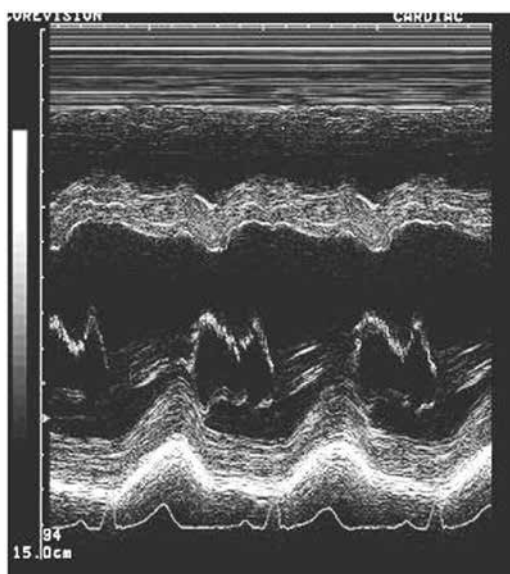
The amplitude of returning echoes are displayed as varying shades of grey between black and white. Black is due to weak signal and white signifies high amplitude i.e. a strong signal. This is the most commonly used mode of ultrasound.



**B Mode USG**

### **M Mode**

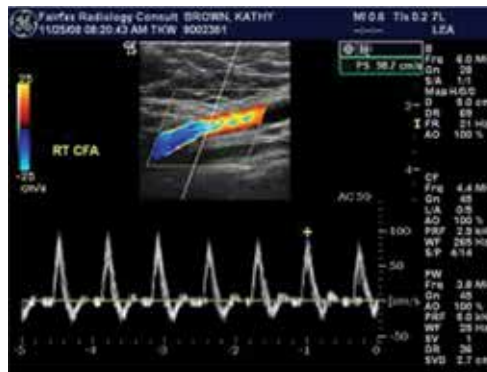
Developed from A mode and returning echoes are recorded as bright dots along the time base. This make observations of moving structures during a specific time interval. It is extensively used in echocardiography to show movement such as mitral valve etc.



**M Mode Ultrasound**

### **D Mode Or Doppler Mode**

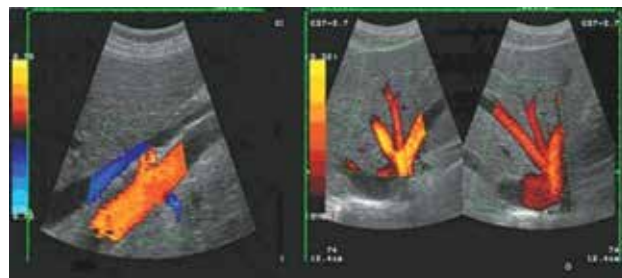This is based on Doppler Effect in which there is a change in frequency of a signal due to the relative movement of the source of signal and the observer. To detect blood flow within the arteries and vein the continuous wave doppler can only tell velocity while the pulsed Doppler give information both about depth, velocity and direction of flow.



Doppler Mode

## Duplex Scanning

It combines real time scanning with pulsed Doppler. It can study the structure details of vessels along with blood flow pattern. Lately colour Doppler has also been introduced, the pattern may be red / blue or mixed depending upon the direction of blood flow.



Colour Doppler

## Clinical Indication of Ultrasound

### Ultrasonography

Ultrasound or ultrasonography (USG) is now a widely available and safe imaging modality. This lesson will familiarize you with the spectrum of its use.

There are competing claims for the superiority of one imaging modality over another i.e. Ultrasonography, Computed Tomography (CT), Magnetic Resonance Imaging (MRI) and Radionuclide Scanning. None the less, since ultrasonography is non-invasive, non-ionizing, relatively inexpensive and widely and readily available, it should still be used first whenever feasible. The non-invasive and expensive technique such as CT and MRI should be reserved for those cases in which ultrasound has not been able to provide an answer to the clinical questions.

### Clinical Applications

Ultrasonography has become the major screening modality in suspected disease of the parenchymal organs of the abdomen. It is the imaging modality of choice for evaluation of disease



of the gall bladder and biliary tract. It is also used for evaluation of the infant's brain; eyes; neck including the thyroid glands, chest, breast, scrotum, joints etc. Ultrasonography is one of the principal modalities in evaluation of the pelvis, particularly the female reproductive system. The urine-filled bladder is used as an acoustic window and allows multiplanar evaluation of the uterus, ovaries and vagina. The development of trans-vaginal ultrasound offers an alternative approach to viewing the pelvis.

Sonography does not utilize ionization radiation and is therefore preferred in the paediatric patients and in patients of childbearing age, and when a non-neoplastic mass, such as follicular cyst, or ectopic pregnancy is thought to be present. USG is the method of choice for imaging the ovary. Furthermore, with the simplicity and flexibility, ultrasonography has proved to be a major tool for guiding diagnostic and therapeutic aspiration procedures. The portability of small real-time units allows useful clinical contributions to be made at the patient's bedside, in critically ill patients, particularly in the intensive care unit, and for guiding procedures, even in the operating room.

### **Disadvantages of USG**

A major disadvantage of sonography is that the quality of the images is variable depending on the expertise of the operator, the resolution of the equipment / and the patient's body habitus.

Presence of gas in bowel lumen prevents proper evaluation of the bowel. Moreover it acts a strong reflector of sound waves, preventing visualization of structures behind air-containing bowel, like retroperitoneal nodes and pancreas.

Bony structures cannot be evaluated with sonography.

Most of the referring clinicians are uncomfortable with ultrasound images and find them difficult to interpret and correlate.

### **Pre Examination Details and Patient Preparation**

A complete history taking of the patient is mandatory since goal-oriented examination is more likely to be diagnostic than on that is not goal-oriented.

Abdominal sonography is ideally performed after the patient has been overnight fasting to minimize bowel gas. Overnight fasting is necessary if a good examination of the gall bladder is required. These patients are kept fasting for 8-12 hours to ensure gall bladder distension and to reduce the amount of gastric and intestinal gas.

If there is inadequate visualization of the pancreas, the stomach may be distended with water given orally, to act as an acoustic window.

For pelvis evaluation, distended bladder is essential as urine-filled bladder is used as an acoustic window. In patients with a urinary catheter, evaluation of the pelvis requires the clamping of catheter to distend the bladder. Bladder is emptied prior to endovaginal sonography.



For a successful pediatric sonography, it is important to immobilize children and obtain their cooperation. For this infants may be breast fed, and older children may be distracted with toys. Some may even need to be sedated. It is important to monitor the vitals of a child who is sedated.

To evaluate an infant's bladder or pelvis, the child may have to be repeatedly taken for USG examination, every 15-20 minutes, to see whether his bladder is full because the child may void spontaneously as soon as his bladder is full.

### **Scanning Technique**

The patient is placed in the supine position on the examining table. Mineral oil or gel, preferably warm, is used as an acoustic coupling agent applied to the skin over the entire upper abdomen. An appropriate transducer is selected for the size of the patient and area to be examined. Usually there is a 3.5 MHZ curved linear array transducer for the abdomen. This generally provides optimum resolution while maintaining adequate depth penetration. A 5.0 MHZ curved / 7.5 MHZ linear array transducer provides greater resolution for children and thin individuals. A more tightly curved linear array transducer can be used to scan from a small window, such as an intercostal or subcostal space. 7.5 MHZ transducer is suitable for small parts e.g. brain, eye, thyroid, breast, scrotum, joints, etc.

To maximize the diagnostic sensitivity and minimize the scanning time and effort required, we use a thorough, standard, sequential, organ oriented scanning technique. Emphasis on certain structures and areas depends on the history given and the pathology found. After all organs and their contiguous structures are individually and thoroughly examined, diagnostic impression is formulated. If no pathology is seen, a limited number of standard hard-copy images are recorded. These generally contain sufficient anatomic landmarks to allow easy identification of the organ and projection. Images of all definite or suspicious lesions should be frozen and photographed in multiple projections to show not only the lesion but also the relationship to the surrounding identifiable structures.

### **Doppler Study**

Doppler is done to derive the following information:

- ◆ If there is moving blood present (to detect presence of thrombosis or occlusion).
- ◆ Which way it is going (direction of flow)
- ◆ How fast it is moving (speed of flow)
- ◆ Character of flow (laminar, turbulent, etc.)

Power Doppler is a variant of Doppler, in which there is only information about the presence or absence of flow, but without any information about direction of flow. However, Power Doppler is more sensitive than Doppler ultrasound to detect the presence or absence of flow.





## Applications of Doppler

- (i) Carotid Doppler
  - For evaluation of stenosis
  - For evaluation of carotid plaque
- (ii) Peripheral Doppler  
(Evaluation of extremities)
  - (a) Arterial system
    - For evaluation of stenosis
    - For evaluation of atherosclerotic plaque
  - (b) Venous system
    - For evaluation of varicose veins
    - For evaluation of Deep venous thrombosis
- (iii) Abdominal Doppler
  - (a) Renal Doppler
    - For evaluation of renal artery Stenosis
    - For evaluation of renal vein thrombosis
  - (b) Doppler ultrasound of portal venous system
    - For evaluation of portal hypertension
  - (c) Obstetrics Doppler
    - For evaluation of blood flow in uterine and umbilical arteries.

## Review Questions

- Q 1. Blood flow in vessels are studied by which ultrasound technique?
- Q 2. What are the commonly used frequencies of sound waves in diagnostic ultrasound?
- Q 3. What do you understand by ultrasound?
- Q 4. What is Piezo-electric effect?
- Q 5. What are various image display mode?
- Q 6. How will you deal with children who come for sonography?
- Q 7. What are the advantage of sonography?
- Q 8. What are the limitations of sonography?
- Q 9. Which transducer will you select for sonography of children, adult breast, thyroid, carotid arteries and peripheral veins respectively?
- Q 10. What is real time sonography?
- Q 11. How will you prepare a patient for abdominal sonography?
- Q 12. Write principle of ultrasound?





## Chapter-2

# CT Scan and its Applied Aspect

### Introduction

Computed tomography (CT) refers to radiographic examination of the patient displayed as a thin, cross-sectional, grayscale, tomographic images. A computer assisted (mathematical) reconstruction of numerous x-ray absorption differences of the various organs and tissues helps to build up the CT image.

**Objective – After studying the chapter the students will be able to :**

- ➔ Define CT scan
- ➔ Summarize the principles of CT scan
- ➔ Explain generations of CT scan
- ➔ Recognise equipment competent of CT – scanner
- ➔ Appreciate the use of CT scan in body imaging
- ➔ Devise patient preparation plan for CT scan
- ➔ Assist in administering contrast media used in CT examination
- ➔ List advantage and disadvantage of CT over other imaging modalities

The person credited with the first successful clinical demonstration of CT was G.N. Hounsfield, a research scientist at EMI Research Laboratories in England, who in 1972 produced the first cranial scan, using X-rays with a computer reconstructed image displayed on a television monitor.

CT scanners have now come a long way with the advancement in technology related to software & hardware in computer science. CT scanners are now available to the ordinary man at reasonable cost. With the evolution in technology, present day CT scanners are able to minimize patient examination time and radiation exposure. Faster scanners are now available even for CT imaging of heart.

### The General Principle of Computed Tomography (CT):

Principal of CT is similar to conventional tomography in which there is a slice of tissues which comes into focus and the slices above and below are blurred out and not in focus. The “tomogram” is obtained by making the x-ray tube and the image detectors move about a focal point during the exposure.

The primary difference, between conventional and computed tomography, is that in conventional tomography the image is recorded on a conventional X-ray film and in CT computers are used to reconstruct the focused image or tomographic “slice” as received by the image detectors.



The principle of computed tomography is that the internal structure of any three – dimensional subject can be reconstructed from many different projections or views of that subject. This necessitates the collection of large amount of data in order to reconstruct an accurate picture of the original structure.

### Advantages Over Conventional Radiography

Computed tomography has three distinct advantages over conventional radiography.

First, dimensional information is displayed which is not available in conventional tomography.

Second, the system is much more sensitive when compared to conventional radiography so that differences in soft tissue can be clearly delineated.

Third, CT measures x-ray absorption of individual tissues accurately, allowing the basic nature of tissue to be studied. This is possible by displaying or reading off CT or Hounsfield numbers or Hounsfield Units (HU) of various tissues:

Lung air is – 1000 HU (minus 1000) or less,

Fluid such as CSF is 18-20 HU,

Calcification is above 500HU,

Grey and white matter of brain is 30-40HU,

Fresh blood is above 50HU and so on.

### Disadvantage of CT

1. Compare to other diagnostic test CT scan deliver a relatively high dose of radiation to the patient.
2. Some time patient may develop allergic reaction to contrast media. Usually it is mild but some time it may be severe and even may take the life of patient.
3. It is a costly investigation and not readily available in towns and small hospitals.

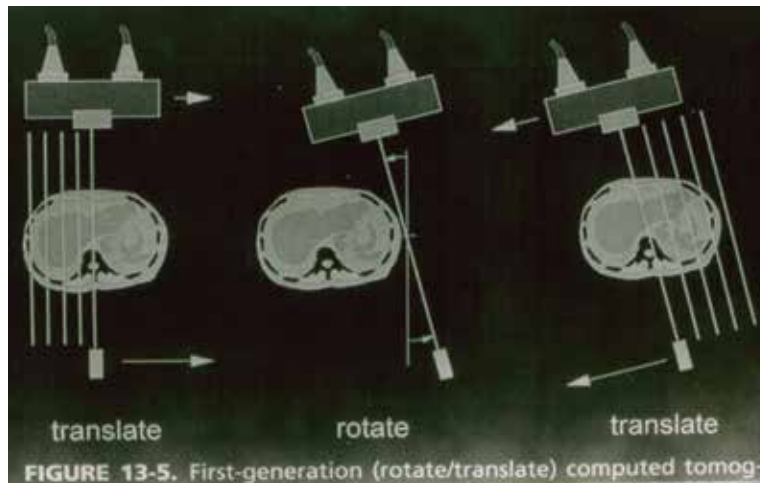
### Generations of CT Systems

Since the introduction of clinical CT scanning in 1972, equipment systems have evolved through stages, commonly referred to as generations. Each generation of scanners decreased the scanning time, the time required to gather the information for each scan. The difference between the succeeding generations of scanning systems primarily involved the x-ray tube and detector arrangements. The addition of more detectors reduced the scanning times considerably.

**First Generation Scanners:** The original CT scan unit was first generation scanners. It had a pencil like X-ray beam and single detector. The Xray tube and detector movements were both linear and rotatory (Translate and rotate).

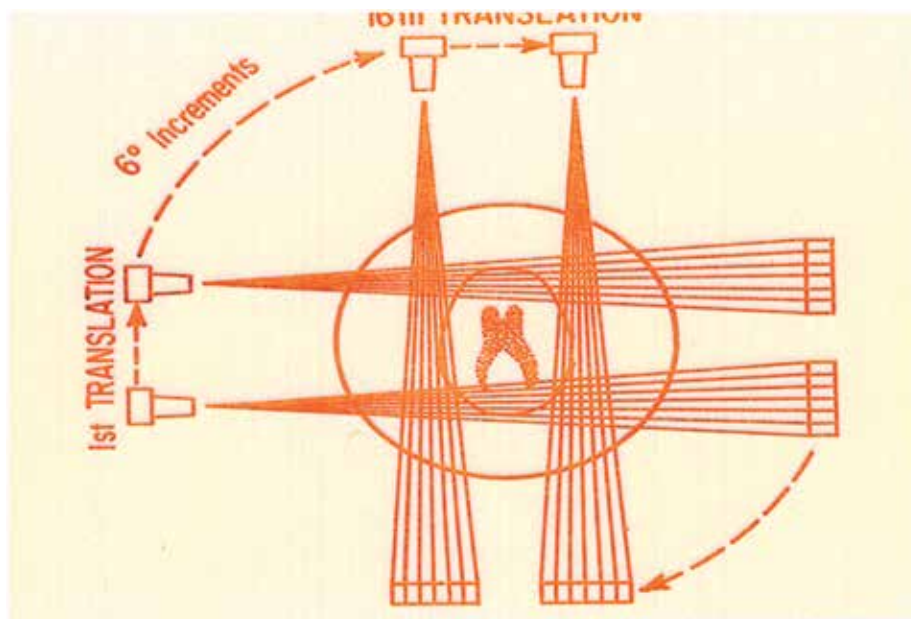


One tomographic section of head used to take 5 minutes.



- ◆ Single Detector
- ◆ Translate – Rotate geometry (rotator movement was 1 at the end of each linear scan)
- ◆ Total rotation 180° semicircle
- Pencil beam of X-rays
- Scan time 5 minutes approximately


**Second Generation Scanners** – To shorten the scanning time for each tomographic section pencil beam and single detector were replaced by fan beam and multiple detectors in second generation scanner. Number of detectors vary and may be upto 30 or more. The movement of Xray tube- detector array are both linear and rotatory. In second generation scanner, time taken per tomographic section was 30 seconds.





- ◆ Multiple detectors (as many as 30)
- ◆ Translate - rotate (Rotatory steps are larger (upto 300))
- ◆ Small fan beam (3-100)
- ◆ Scan time — 30 seconds/slice

**Third Generation Scanner** – In the third generation scanner translation movement was completely eliminated. In this both xray tube and detector array rotates around the patient. Multiple detectors (700 in numbers) are arranged along the arc of circle opposite the x-ray tube which together rotate around the patient in a complete 360 degree cycle to create one tomographic slice. The patient and table are then moved on increment superiorly or inferiorly and the tube and detectors rotate a full 360° cycle in the opposite direction to create a second slice of tissue data and so on. Time taken in one slice is 1 to 3 second approximately.



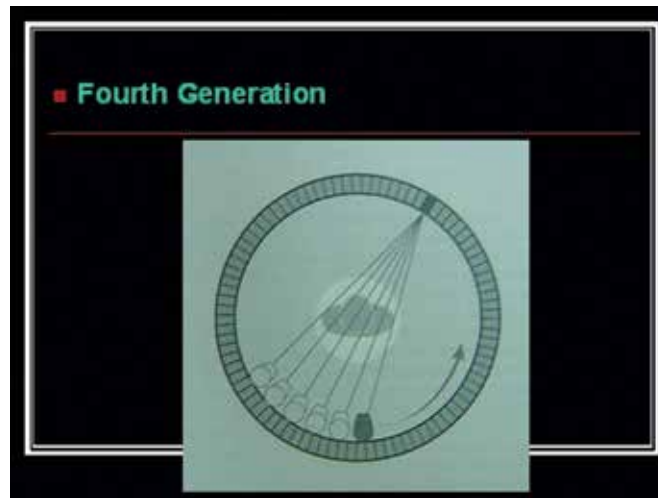
- ◆ Multiple detectors
- ◆ Rotate-rotate
- ◆ Large fan beam (50-55°)
- ◆ Scan time – 1-3 seconds/slice

**Fourth Generation Scanner** – Fourth generation scanners developed during the 1980s possess a fixed ring of as many as 4800 detectors, completely surrounding the patient in a full circle within the gantry. A single x-ray tube rotates through a 360° arc during data collection.

- ◆ 360° circular array of fixed detectors
- ◆ Rotate-fixed



- ◆ Large fan beam (50-55°)
- ◆ Scan time – 1-3 seconds/slice

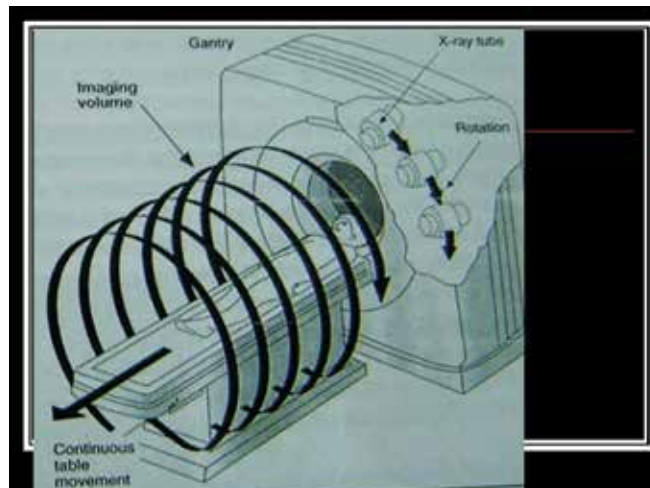


Both third (rotate – rotate) and fourth (rotate - fixed) CT units gives excellent results, with no clear advantage of one over the other.

**Helical CT Scanners** – During the early 1990s a new type of scanner was developed termed as helical CT scanners. In this system the patient continuously moves slowly in or out during the 360° circling of the x-ray tube creating a helical or “coiled spring” type of data acquisition. In this way a **volume of tissue** is examined and data collected rather than individual slices as with other systems.

Helical CT systems utilize either third or fourth generation type detector arrangements with most helical systems utilizing the third generation type.

Formerly the x-ray tube with attached high tension cables was limited to one 360° rotation in one direction comprising one slice, followed by another 360° rotation in the opposite direction creating a second slice, the patient moved one increment between slices.







The development of slip ring engineering technology allows for continuing tube rotations, which when combined with patient movement creates a helical type scan data with total scan time that are one half or less than that of other third or fourth generation type scanners.

### **Components of the Computer Tomographic System**

#### **1. Scan Unit**

All computed tomographic systems consist of two major elements:

1. Scan unit and
2. Operator console.

The scan unit provides information to the computer. The scan unit is housed in a separate room (scanner room) and is the part of the system seen by the patient.

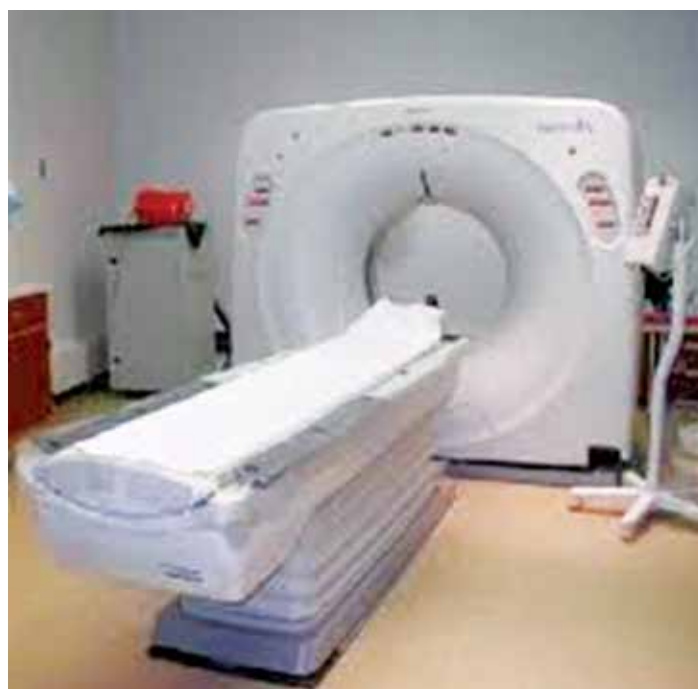The scan unit in the scanner room consists of two parts:

1. The patient table (couch), and
2. The gantry.

The patient table or couch provides a comfortable surface for the patient in lying down (recumbent) position the scanning time.

The gantry is a rigid support structure that houses the x-ray tube and the radiation detector array.

The patient table moves in and out within the central opening of the gantry, which is called the gantry aperture.



**CT equipment – Gantry and Patient table**





## Operator Console

A second major element of any computed tomographic system is the operator control console, which includes the processing unit or computer that takes raw data and converts it into a picture form.

All the necessary controls to process through each examination are located at the operator control console which is located just outside the scanning room. This includes controls for the exposure factors (kVp, mA, scan time) as well as slice thickness and pitch selections, scan directions and other variables that may be specific to the equipment being used. Image manipulation such as edge enhancement, zoom, brightness and contrast controls are also possible at the control console.

Most modern control consoles include two color monitors, one for the control displays, and one for viewing the radiographic image.

Image recording and storage can be done by two methods.

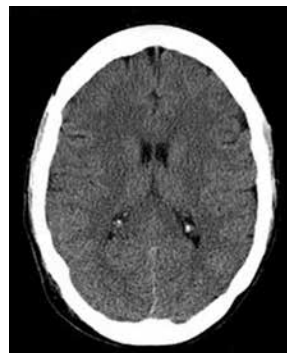- ◆ Most modern systems use laser printers to print out of films.
- ◆ For permanent storage of data information in digital form CD or DVD can be used. This information can be readily retrieved at any time.

## Clinical Indication for CT Scan

**Indications:** Usually after primary investigation as x-ray and USG patient is referred for CT scan for better characterization or detection of disease. Depending upon various part indications may be as;

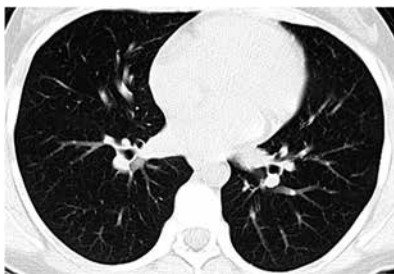### 1. Head

Virtually any suspected disease process involving the brain is an indication for cranial computed tomography. Some of the common indications for cranial computed tomography include suspected brain neoplasms or mass, brain metastases, intracranial hemorrhage, aneurysm, abscess, brain atrophy, post-traumatic abnormalities such as epidural and subdural hematomas, and acquired or congenital abnormalities.

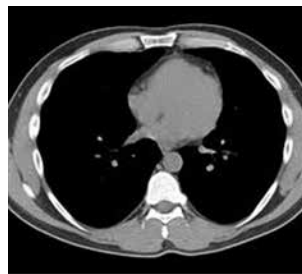



## 2. Thorax



Lung Window



Medistinal Window

Most lung and mediastinal abnormalities of the chest, as documented on plain radiographs, are an indication for computed tomography. Some of the more common indications for CT of the chest are non-resolving lung and pleural diseases, mediastinal and hilar lymphadenopathy, aortic aneurysms, cardiac and pericardial diseases.

## 3. Abdomen & Pelvis

**Abdomen:** Some of the more common indications for computed tomography of the abdomen include suspected primary or metastatic lesions of the liver, pancreas, kidney or spleen. Computed tomography is a preferred choice for examination of suspected adrenal gland pathology.

**Pelvis:** In the region of the pelvis, computed tomography is primarily used to provide information on the state of advancement of pelvic disease. Computed tomography has proven valuable in the evaluation of prostatic, cervix, urinary bladder, and ovarian carcinomas. Other indications are evaluation of soft tissue masses and disease of the pelvic muscles, suspected abscesses and evaluation of the hip joint, especially in trauma patients.

## 4. Whole Body CT

Trauma is the most common indication of whole body CT. As it is very fast and gives complete information from soft tissue to bone and from head to toe.

### Contraindications for CT

There are no major contraindications of computed tomography except pregnancy and history of allergy to the contrast media.

In a patient of drug allergy it is advisable to carry out the procedure in the supervision of anesthetists or do only a plain CT.

### Contrast Media

The contrast media utilized for computed tomography are identical to those used for excretory urography. These iodinated contrast media are administered as an intravenous injection.

First CT scanning is done without contrast and then after I.V. injection of contrast media scanning is repeated. The use of contrast media can provide valuable information and useful



in separation of soft tissue lesion from lymphnodes and vascular structure. The enhancement pattern of various lesions also helps to characterize them, Intravenous contrast is also important for visualization of ureter and bladder. We can tailor the study according to the indication or patient. Like in child we can avoid plain scan to reduce the radiation dose. Or in some cases we can take more than two scans.

### Patient Preparation

1. Patient should be empty stomach to prevent complication of vomiting after I.V. contrast media.
2. All metallic objects should be removed in the radiographic area of interest / because metal will produce artifacts. It is better to change the clothing of patient to prevent unwanted artifacts from buttons, coins in pocket or keys etc.
3. Patient motion during the procedure impairs the quality of the CT. Patient should be given breath holding instruction (for thorax & abdomen) and informed about time required for the CT examination.
4. For abdominal CT large bowel should be free from fecal matter as far as possible prior to the examination. The patient should take a laxative in the evening prior to CT exam.
5. The use of oral and rectal contrast media to opacify the gastrointestinal tract is necessary for examination of abdomen and pelvis. Non opacified portion of small and large bowel can be misdiagnosed as lymphnodes, abscess or masses.
6. Water soluble iodinated contrast media are used to opacify the bowel in most department which is ingested orally or inserted per rectally in diluted form.

### Contrast Scale for Viewing

- ◆ After scanning the patient images can be seen in different scale (also known as window) and in different planes.
- ◆ Soft tissue window is used to see the abdomen, brain and mediastinum.
- ◆ Bone window is used to see bones.
- ◆ Lung window is used to see lung parenchyma.

### Multiplanar Reconstruction

By this technique axial images can be constructed in sagittal and coronal plane.

### Review Questions

- Q 1. Who has invented the first CT scanner?
- Q 2. Which types of radiation is used by CT scan to produce image?
- Q 3. Gray scale unit to measure CT density is called \_\_\_\_\_ .
- Q 4. What are the major component of CT machine?



- Q 5. How will you prepare a patient for CT brain?
- Q 6. How will you prepare a patient for CT chest?
- Q 7. How will you prepare a patient for CT abdomen?
- Q 8. What are the major indications for CT scan of various body parts?
- Q 9. What are the contrast media used for CT scan?
- Q 10. What are the contraindications for CT scan?
- Q 11. What is helical CT scan?
- Q 12. What are the advantages of CT scan over conventional radiography?
- Q 13. What is the major disadvantage of CT scan?



## Chapter-3

# MRI and its Applied Aspect

### Introduction

MR imaging involves the utilization of nuclear magnetic resonance property to produce the body images. This is modality in the field of medical body imaging which does not involve the use of ionizing radiation. This modality provides high resolution of images and is especially useful in evaluation of brain, spine and musculoskeleton.

**Objectives – after studying the chapter the students will be able to :**

- Define MRI and its basic principle
- Enlist the various component of the equipment
- List the type of magnet and coils
- Appreciate the clinical applications of MRI
- Take safety precaution and prevent hazards
- List the contra indications of MRI
- Prepare the patient for MRI
- Assist in the administration of contrast agents in MRI

### Definition

Magnetic resonance imaging (MRI) refers to the use of magnetic fields and radio waves to obtain a mathematically reconstructed image. This image represents difference among various tissues (of the patient) regarding the number of nuclei, and in the rate at which these nuclei recover from stimulation by radio waves in the presence of a magnetic field.

The steps of an MRI are as follows:

- ◆ Patient is placed inside a magnet
- ◆ A radio wave (radio-frequency) sent in
- ◆ The radio wave (radiofrequency wave) is turned off
- ◆ The patient emits a signal which is received and is used for
- ◆ Reconstruction of the picture



## General Principles of MRI

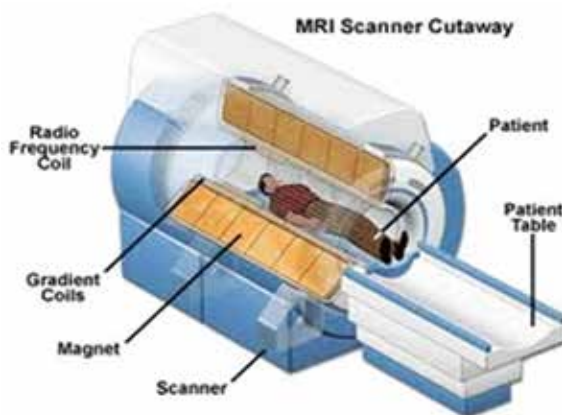
Certain nuclei in the body will receive and re-emit radio waves of specific frequencies when these nuclei are under the influence of a magnetic field. These re-emitted radio signals contain information about the patient that is captured by a receiver or antenna. The electrical signal from the antenna is transmitted through an “analog-to-digital” converter and then to a computer, where an image of the patient is reconstructed mathematically.

## Equipment Components

### MRI System Components

The six main components of the MRI system are as follows:

- ◆ Magnet
- ◆ Gradient Coils
- ◆ Radio Frequency Coils
- ◆ Electronic support systems
- ◆ Computer
- ◆ Display



MRI Machine

### Types of Magnets

The most important component of the MRI system is the magnet. The magnet provides the powerful static (constant strength) magnetic field about which the nuclei process. At the present time there are three types of MRI system magnets. Field strengths used vary from 1.5 to 3.0 Tesla.

#### 1. Resistive Magnets

The resistive magnet works on the principle of the electromagnet, wherein a magnetic field may be created by passing an electrical current through a coil of wire. These are no longer in clinical use.





## **2. Permanent Magnets**

For MRI use, certain very large permanent magnets may be made with field strengths up to 0.4 Tesla. A disadvantage, the inability to turn off the power of the magnetic field.

## **3. Superconducting Magnets**

The superconducting magnet also uses the principle of the electromagnet. In addition, it uses a property that is demonstrated by some materials at extremely low temperatures, the property of superconductivity. A superconductive material is a material that has lost all resistance to electrical current.

Higher magnetic field strengths are possible with the superconducting magnet, with values as high as 3 Tesla for clinical use. These are currently a common type of magnet in clinical use because of their greater magnetic field strength.

### **Types Of Coils**

These are of two types: Gradient and Radiofrequency Coils

#### **1. Gradient Coils**

In addition to the powerful magnets, a second major component of the MRI system is the gradient coil. The gradient magnetic fields allow the computer to determine the location within the patient from which the received MRI signal originated. This information is, of course, crucial to the reconstruction of an image of the patient. The gradient fields are much weaker than the static magnetic fields and can be produced by relatively simple coils of wire.

#### **2. Radio Frequency (RF) Coils**

A third key component of the MRI system is the radio frequency (RF) or “send and receive” coils. These RF coils act as antennas to produce and detect the radio waves that are referred to as the MRI “signal”.

A typical RF coil is encased or enclosed in the gantry of the magnet and thus is not specifically visible. These encased RF coils, sometimes referred to as body coils, completely surround the patient including the table on which the patient lies. Some surface coils, such as the shoulder coil, are placed on the area to be imaged. Generally, this type of surface coil is used to image more superficial structures.

### **Computer**

The fifth component of the MRI system is the computer, a key component of an MRI unit. It processes information from all parts of the MRI system. During a scan it controls the timing of pulses to coincide with changes in gradient field strengths. After a scan it reconstructs the image of the patient using techniques like computed tomography. External memory includes the various types of digital storage media, such as hard disks, optical disks, and tape cartridges that are used to store information for future use.



## Display

The sixth and last component of the MRI system to be discussed is the display or workstation, which allows the technologist to control the operation of the system and view images as they are reconstructed. A workstation, contains the controls used by the technologist to select pulse sequences, set the various operator adjustable parameters, and to initiate the scan. Controls on the display allow brightness and contrast to be altered to bring out significant features in the image.

## Clinical Applications

Diagnosis of disease such as those involving the CNS can be made with MRI by making comparisons between the signal produced in normal tissue and the signal produced in abnormal tissue.

Unlike CT, nuclear medicine and radiography, no ionizing radiation is used in MRI. Therefore MRI is deemed safer in terms of biological tissue damage. Even though the MRI scanner does not use ionizing, there are safety considerations that must be identified and understood.

## Basic Safety Considerations

Safety concerns for the technologist, patient and medical personnel must be recognized and are due to the interaction of the magnetic fields with metallic objects and tissues. During an MR scan, patients as well as other personnel in the immediate area are exposed to magnetic field.

Safety concern of MRI resulting from the interaction of these magnetic fields with tissues and metallic object are as follows:-

1. Potential hazard of projectiles.
2. Electrical interference with implants.
3. Local heating of tissues and metallic implants
4. Electrical interference with the normal function of nerve cells and muscle fibers.

## Occupational Hazards

To date there have been no documented long term biological adverse effects for technologists working in the MRI department. As a precaution, some MRI centers have recommended that technologists who are pregnant remain outside the scan room. Radiobiologists continue to investigate the possibility and occurrence of adverse effects due to electromagnetic fields.

## Contraindications

There are certain absolute contraindications to patient MR scanning, as shown in table. Although not an absolute contraindication, pregnancy is also often considered a contraindication. When



an MRI examination is indicated with pregnancy, an informed consent should be obtained and documented.

### **Contraindications to MRI**

- Pacemakers
- Ferromagnetic aneurysm clips
- Metallic fragments in the eye
- Cochlear implants
- Prosthetic heart valves
- Internal drug infusion pumps
- Neuro stimulators
- Bone growth stimulators

### **Patient Preparation**

Information when preparing a patient for an MR scan may include;

1. A description about the MR scanner
2. The importance of lying still
3. The knocking sound they will hear
4. The length of time a sequence will last
5. The two-way communication system and the monitoring that will take place.
6. The lack of ionizing radiation
7. The importance of removing all metal

Certain pulse sequences generate a high - volume knocking noise. The patient must be informed of this and ear protection may be required during these sequences.

### **Contrast Agents**

Contrast agents have become increasingly popular for MR examination. The contrast agent that is most popular is Gadolinium DTPA (Gd-DTPA).

The major route of excretion is through the kidneys, therefore renal failure would be a contraindication for its use. Pregnancy may also be a contraindication for the use of Gd-DTPA.

### **Positioning and Coil Selection**

The patient lies in the bore of the magnet in the supine, prone, oblique or decubitus position. In most situations, the patient is supine with the anatomy of interest centered to the RF coil. Three



of the most frequently used coil designs are the (1) circumferential whole-body coils, (2) surface coils and (3) phased array coils.

Care must be taken when placing the coils. For safety reasons, the coil must be connected properly and the lines not loped as they extend from the magnet. This reduces the chance of electric “arcing” of sparks that may burn the patient.

There are different types of pulse sequences which are used in MRI images.

1.  $T_1$  Weighted images.
2.  $T_2$  Weighted images.
3. Proton density images.

In MRI scanning is done in different planes as sagittal, coronal, axial unlike CT in which scanning is done in one plane and images are reformatted.

Typically an MRI examination consists of two to six imaging sequences each lasting two to 15 minutes. Each sequence has its own degree of contrast and shows cross section of body in one of the several plane.

## Clinical Indication

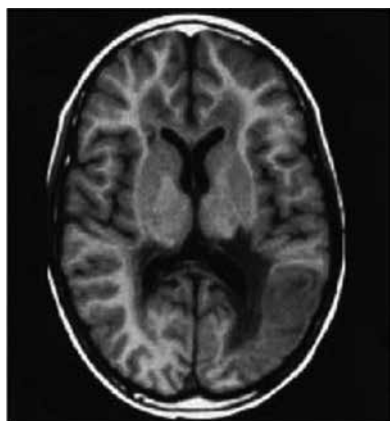
### Introduction

Magnetic resonance imaging (MRI) uses radiofrequency waves and a strong magnetic field rather than x-rays to provide remarkably clear and detailed pictures of internal organs and tissues. The technique has proven very valuable for the diagnosis of a broad range of pathologic conditions in all parts of the body, including cancer, heart and vascular disease, stroke, joint and musculoskeletal disorders.

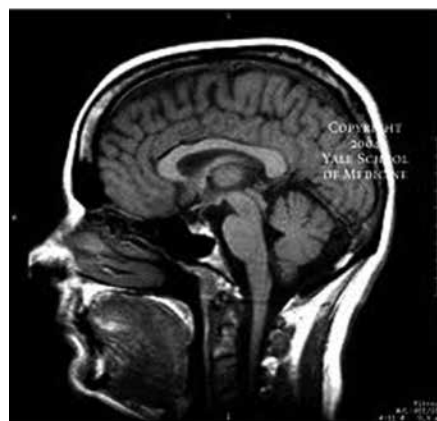### What are Some Common Uses of the MRI?

Because MRI can give such clear pictures of soft tissue structures near and around bones, it is the most sensitive examination for spinal and joint problems. MRI is widely used to diagnose sports-related injuries, especially those affecting the knee, shoulder, hip, elbow and wrist. The images allow the physician to see even very small tears and injuries to ligament and muscles.

Organs of the abdomen - including liver, kidney, spleen, pancreas and abdominal vessels - can also be examine in high detail with MRI, enabling the diagnosis and evaluation of tumors and functional disorders. MRI is growing in popularity as an alternative to traditional x-ray mammography in the early diagnosis of breast cancer. Because no radiation exposure is involved, MRI is often the preferred diagnostic tool for examination of the male and female reproductive systems, pelvis and hips and the bladder.



Axial Section of Brain



SAG Section of Brain

### Preparation For The MRI Scan

Because the strong magnetic field used for MRI will pull on any ferro-magnetic metal object implanted in the body, ask the patient whether he has a prosthetic hip, heart pacemaker (or artificial heart valve), implanted port, infusion catheter, intrauterine device (IUD), or any metal plates, pins, screws, or surgical staples in his/her body. In most cases, surgical staples, plates, pins and screws pose no risk during MRI if they have been in place for more than four to six weeks. Tattoos and permanent eyeliner may also create a problem. If there is any doubt of metal fragments, ask the patient to have an x-ray that will detect any such metal objects. Tooth fillings usually are not affected by the magnetic field, but they may distort images of the facial area or brain, so the radiologist should be aware of them. The same is true of braces, which may make it hard to “tune” the MRI unit to your body. Tell the patients to remove anything that might degrade MRI images of the head, including hairpins, jewellery, eyeglasses, hearing aids, and any removable dental work.

Ask the patient about drug allergies. Also some patients who undergo MRI in an enclosed unit may feel confined or claustrophobic. If they are not easily reassured, a sedative may be administered. Roughly one in 20 patients will require medication to reduce the anxiety associated with claustrophobia.

### How is the Procedure Performed?

The patient is placed on a sliding table and positioned comfortably for the MRI examination. Allow a friend or family member, and if a child is being examined, a parent to stay in the room with the patient. Depending on how many sequences are needed, the exam will generally take 15 to 45 minutes, although a very detailed study may take longer. Tell the patient not to move during the actual imaging process, but between sequences some movement is allowed. Patients are generally required to remain still for only a few seconds to a few minutes at a time.





Depending on the part of the body being examined, a contrast material may be used to enhance the visibility of certain tissues or blood vessels.

### Advantage of MRI

1. MRI gives better soft tissue contrast so images are clearer and more detailed than any other imaging method. This makes MRI an invaluable tool in early diagnosis and evaluation of tumors.
2. MRI enables the detection of abnormalities that might be obscured by bone with other imaging methods.
3. MRI contrast media is less likely to produce an allergic reaction than iodine based contrast media used for conventional X-rays and CT scan.
4. Exposure to radiation is avoided.

### Disadvantage

1. Bone is better images by conventional X-ray or by CT scan.
2. MRI does not detect calcium when this is present within a tumor.
3. MRI is not safe with metal implants.
4. MRI is costly than CT scanning and time consuming also.
5. MRI is generally avoided in early pregnancy (first trimester). It should not be done unless there is a strong medical reason to use MRI.

### Review Questions

- Q 1. Discuss the MRI principle.
- Q 2. Describe the equipment component of MR machine.
- Q 3. Discuss the contraindications and hazards of MRI.
- Q 4. Mention the important points of patients preparation and patient comfort in MR imaging.
- Q 5. Discuss the advantage and disadvantage of MRI over other imaging modalities.
- Q 6. Which is the unit measuring magnet field strength in MRI.
- Q 7. What is claustrophobia?
- Q 8. What are the types of magnet used in MRI?
- Q 9. Commonly used coil in MRI.
- Q 10. Which is the main atom responsible for producing signals in MR imaging in human body?
- Q 11. What are the disadvantages of MRI over CT scan?
- Q 13. Is MRI safe in pregnancy.





## Chapter-4

# Radio Nuclide Scanning

### Introduction

Radionuclide scanning is an imaging modality which delineates the anatomy and function of body organs. It is useful especially in evaluation of renal dysfunction and malignancies in various organs. It gives radiation to the patients hence to be used only when indicated.

**Objectives – After studying the chapter the students will able to :**

- ➔ Understand what is radionuclide and how it is useful in imaging of body organs
- ➔ To learn about commonly used radionuclide
- ➔ To learn the technique of radionuclide scanning
- ➔ To know the uses of radionuclide scanning in different body system
- ➔ Describe the principle of positron emission tomography
- ➔ Enlist the clinical application and disadvantages of PET

### Radionuclide Scanning

While conventional radiography and CT scanning produce images that depend on a physical difference among body structures, radionuclide scanning uses a different approach. In radionuclide imaging a tiny amount of a radioactive labeled substance is injected into the vein. The substance that is injected into the vein is called a tracer. Tracers are quickly distributed throughout the body, even in the heart, where they are visible by using a gamma camera. Each image will be displayed on a screen where it can be used to study body tissues.

It is an imaging modality, which can demonstrate both the anatomy and function of an organ. It depicts the distribution of radioactivity in body tissues.

### Ideal Radio Nuclide

- ◆ Emits (gamma) rays of medium energy (80-200keV) with single photon peak.
- ◆ Does not emit any particles.
- ◆ Has a suitable half-life for adequate examination
- ◆ Nontoxic and capable of being labeled to a pharmaceutical component, this is chemically inert with a suitable metabolic pathway.



## Commonly Used Radionuclides

1.  $^{99m}\text{Tc}$  – fulfils most of the above criteria. Its half-life is 6 hrs and gives a single photon of 140 keV energy.  
It is used to label different compounds for different organs.  
Brain –  $^{99m}\text{Tc}$  labeled glucoheptonate and pertechnetate  
Liver –  $^{99m}\text{Tc}$  labeled sulphur colloid.  
Kidneys –  $^{99m}\text{Tc}$  DTPA,  $^{99m}\text{Tc}$  DMSA (dimercapto succinic acid)  
Skeleton –  $^{99m}\text{Tc}$  labeled phosphonates
2.  $^{81m}\text{Kr}$  has a very short half-life of 13 seconds and is used for lung ventilation studies.
3.  $^{131}\text{I}$  has a half-life of 8 days and is used for thyroid scans.

For all radioactive compounds proper handling and disposal should be done according to BARC guidelines.

## Instructions to Patients

For GIT imaging, 6 hours fasting is required prior to investigation.

When iodine compounds are used for organs other than thyroid, premedication with Sodium perchlorate helps prevent unnecessary radiation to thyroid.

Oral potassium perchlorate before brain scintigraphy to decrease choroidal plexus activity.

Laxatives after gallium studies to clear excreted compound from gut.

Diuretics used to fasten diuretic renogram study.

Patient in general should be asked to drink lot of water for rapid excretion of compound so as to decrease radiation dose.

## Bone Scanning

In bone scanning the patient is injected with 600-800 MBq of a technetium –  $^{99m}\text{Tc}$  phosphonates compound after proper thyroid blockage with sodium perchlorate. The patient is then asked to ingest 500 – 1000ml of fluids before scanning, which is performed at least 2 hours post injection, in order to accelerate renal excretion of the compound not taken up into the bone. Spot images or a whole-body scan are obtained. This procedure is used when looking for bone metastases.

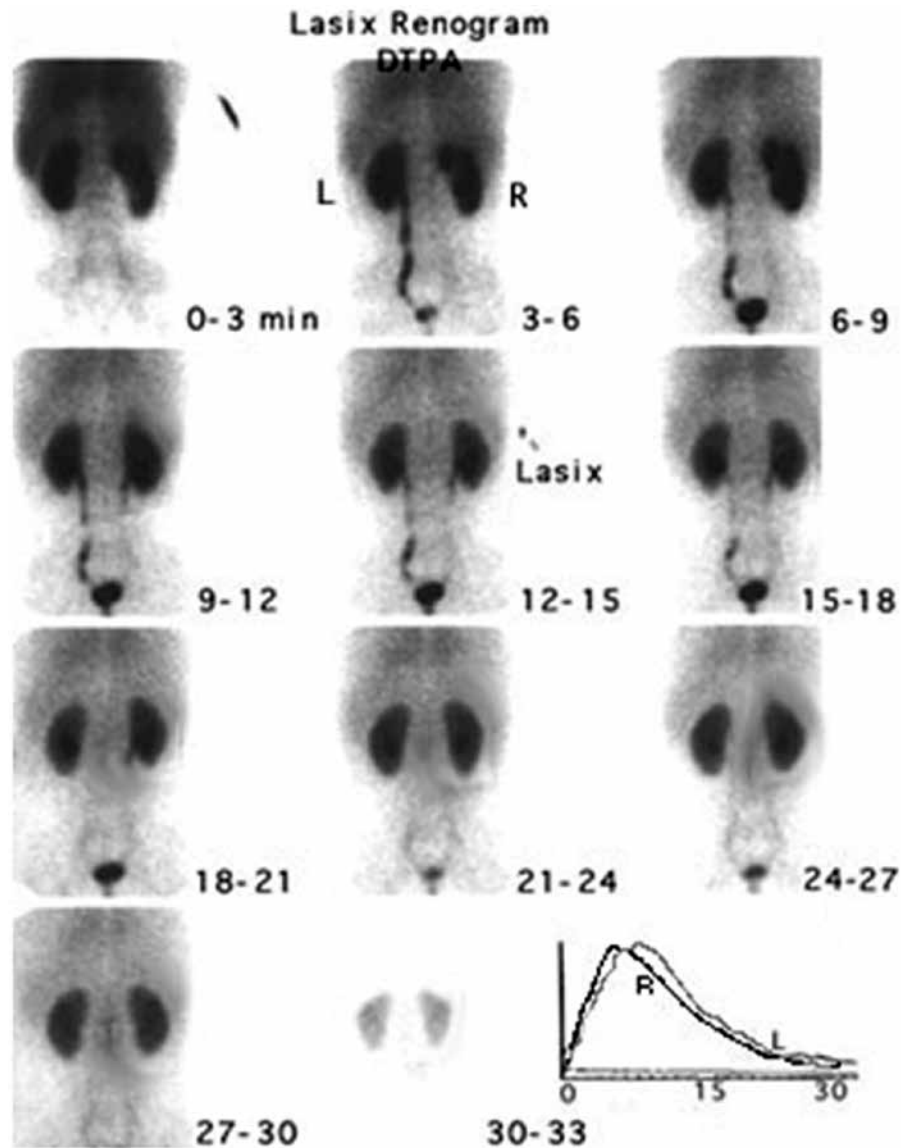
## Cardiac Scanning

Nuclear scanning uses small amounts of radioactive substances (for example, thallium 201) that are injected into a vein to produce images of the heart. These images are used to assess the blood supply to the heart muscle (myocardial perfusion) at rest and during exercise or medicine-induced stress. The most common nuclear test of the heart is known as myocardial perfusion scan. Myocardial perfusion images are obtained



while the patient is lying down under a special camera or scanner (known as single-photon emission computed tomography [SPECT] or positron emission tomography [PET] that generates a picture of the radioactivity coming from the heart. When there is a significant blockage of a coronary vessel, the heart muscle may not get adequate blood supply during exercise or stress temporarily induced by medication administered during the test. Decreased blood flow to the heart muscle can be detected on the images as a perfusion defect.

## Kidney Scan



## Radioisotope Scan of Kidneys

**Dynamic Renal Scan (A Renogram Or A DTPA Scan)** – This investigation gives information about the blood flow to the kidneys and how well each kidney is functioning for the production of urine. The radiopharmaceutical is administered i.v. and dynamic image acquisition is started immediately.



**Static renal scan (DMSA scan)** – This scan gives information about the size, shape and position of the kidney, and whether there are scars on the kidney from a previous infection / infarction.

### Ventilation / Perfusion Lung Scan

Ventilation and perfusion scans are used for two major reasons: detection of pulmonary emboli and assessment of regional lung function. When a blood clot blocks a pulmonary artery, blood flow ceases to the lung region normally supplied by that vessel, and a corresponding “perfusion defect” results.

For lung perfusion scanning, the most common technique involves injecting clusters of human albumin with a radioactive particle into a vein. These clusters travel through the right side of the heart, enter the pulmonary vasculature and lodge in small pulmonary vessels.

Only areas of the lung receiving perfusion from the pulmonary arterial system demonstrate uptake of tracer, while regions that are blocked by blood clots show no uptake of the chemical.

For ventilation scanning, radioactive gas, usually xenon, is inhaled and sequential pictures are obtained showing how the gas distributes within the lung.

### Adrenal - MIBG Scan

It is a radionuclide imaging method, in which metaiodobetaguanidine is labeled with I - 123 and taken up by tissue which secretes catecholamines such as pheochromocytoma.

### Positron Emission Tomography

Positron emission tomography is a nuclear medicine imaging technique which produce a three dimensional image or map of functional process in the body. The system detect pair of gamma rays emitted indirectly by positron emitting radionuclide(tracer),which is introduced into the body on a biological active molecule. Images of tracer concentration in 3-diamentional space within the body are then reconstructed by computer analysis.

To conduct the scan, a short-lived radioactive tracer isotope, is injected usually into blood circulation. The tracer is chemically incorporated into a biologically active molecule, and eventually decays, emitting a positron. The molecule most commonly used for this purpose is fluorodeoxyglucose (FDG), a sugar, for which the waiting period (i.e. time to generate positron once injected into system) is typically an hour.

As the radioisotope undergoes positron emission decay, it emits a positron,

After travelling up to few millimeters the positron encounters and annihilates with an electron, producing a pair of annihilation (gamma) photons moving in opposite directions. These are detected when they reach a scintillator material in the scanning device. But the data set collected in PET is much poorer and so reconstruction techniques are more difficult.



PET scans are increasingly used along with CT or magnetic resonance imaging (MRI) scans, the combination giving both anatomic and metabolic information. Because PET imaging is most useful in combination with anatomical imaging, such as CT, modern PET scanners are now available with integrated high-end multi-detector-row CT scanners.

### Disadvantage

The major disadvantage of PET is its very high cost.

As on site cyclotron unit is required for the shorter lived radionuclides and this has high capital and running cost.

Another disadvantage is radiation.

### Clinical Application

1. Oncology: FDG-PET can be used for diagnosis, staging and monitoring treatment of cancers. It is useful in searching for tumor metastasis, or for recurrence after a known highly active primary tumor is removed.
2. Neurology: it is useful in evaluation of patients having dementia especially Alzheimer's disease. Also useful in seizure disorder and other neuropsychiatric and neurologic illness.
3. Cardiology: atherosclerosis and vascular disease study, can be used in evaluation of patients having myocardial infarction and stroke.

### Review Questions

- Q 1. What do you understand by radionuclide scanning?
- Q 2. What are the various radionuclides to be used for study of thyroid, bones, liver and the kidneys?
- Q 3. Describe briefly a gamma camera.
- Q 4. What is the use of Myocardial Perfusion Scan? Which radioisotope is used for it?
- Q 5. What is an ideal Radionuclide?
- Q 6. What instructions you will give to the patients before radionuclide study?
- Q 7. PET stands for?
- Q 8. What is the most commonly used radiotracer in PET?
- Q 9. What is the basic principle of PET?
- Q 10. What are the clinical applications of PET?
- Q 11. What are the disadvantages of PET?





## Chapter-5

# Recent Advances in Radiology

### Introduction

Till recent time we were able to generate only conventional X-Ray films but with newer development now we are able to capture and provide images in digital format.

In digital radiography system a digital detector replaces film and screen of conventional radiography. There are two basic type of digital radiography system depending upon type of detectors used to capture radiographic information.

1. Computed Radiography (CR) system.
2. Direct Digital Radiography (DR) system.

**Objectives – After studying the chapter the student will be able to :**

- ➔ Know the recent advances in radiology
- ➔ Describe the digital radiography
- ➔ Advantages and disadvantages of digital radiography
- ➔ Compare the computed radiography and direct digital radiography
- ➔ Summarize PACS
- ➔ Discuss the advantages and disadvantages of PACS

### Digital Radiography

In digital radiography system a digital detector replaces film and screen of conventional radiography. There are two basic type of digital radiography system depending upon type of detectors used to capture radiographic information.

1. Computed Radiography (CR) system.
2. Direct Digital Radiography (DR) system.

### Advantages of Digital Radiographic System

1. No silver based film or chemical are required to process film.
2. Reduced film storage costs because image scan be stored digitally.
3. Digital radiography often requires fewer retake due to under or over exposure which results in lower overall dose to the patients.
4. Image acquisition is much faster – image preview can be available in seconds.



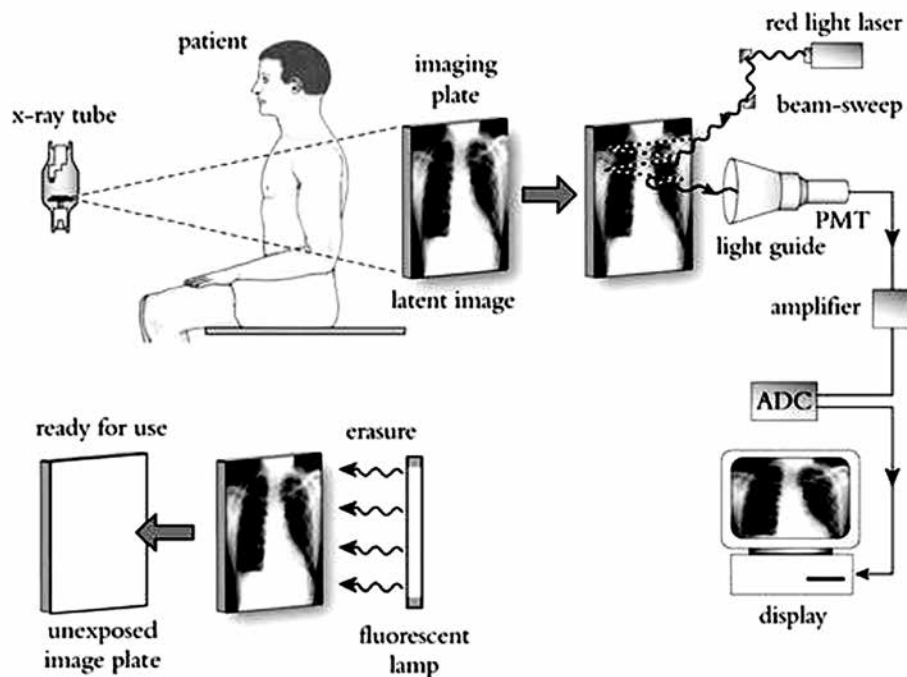


5. Post processing such as windowing, contrast enhancement, magnification etc is possible.
6. Images can be stored on disc or transmitted for offsite view.
7. Soft copy reporting can save cost of film.

Despite these advantages, there are certain limitations as digital system is costly.

### Computed Radiography

Computed radiography uses very similar equipment to conventional radiography except that in place of a film to create the image, an imaging plate (IP) made of photostimulable phosphor is used. The imaging plate is housed in a special cassette and these cassettes are used just like conventional cassettes. And then instead of taking an exposed film into a darkroom for developing in chemical tanks or an automatic film processor, the imaging plate is seen through a special laser scanner, or CR reader that reads and digitized the image. That digital image can be viewed on monitor.



CR System

### Direct Digital Radiography (DR)

Unlike computed radiography, no phosphor containing cassettes are used to generate and read an image in direct digital radiography. Instead DR system comes equipped with a detector that transforms X ray radiation into an electrical charge, which is later sent to a unit that process the image to be viewed and manipulated.



### Differences Between CR And DR

S. No.	CR	DR
1.	Existing X-ray equipment can be used.	Need a costly set up.
2.	This technique is faster than conventional.	This is quicker because it is more direct.
3.	Image resolution is not as good as in DR.	Higher image quality.
4.	Overall lose of radiation to patient is decreased as compare to conventional.	Radiation dose is further decreased.
5.	Though it is costly than conventional system but cheaper than DR.	High cost is the major limitation for DR system

### Picture Archiving And Communication System (PACS)

The aim of PACS is to replace conventional X-ray film and paper clinical request forms and reports with a completely computerized electronic network where digital images are viewed on monitors in conjunction with clinical details of the patient and associated radiological report displayed in electronic format.

The sources of digital information can be networked, within a department or hospital, with a central computer and video monitors in clinics, wards, etc.

Computing techniques can be used to increase information. Vascular structures can be enhanced by subtraction; fractures by edge enhancement; and soft tissue contrast by windowing. Images can be panned, zoomed, and scrolled. Images produced by different modalities can be registered and superimposed. High-resolution anatomical images (CT and MRI) can be overlaid with low resolution functional images (positron emission tomography and single-photon emission CT).

Images can be archived compactly in a optical disks, totaling approx 1 terabyte and rapidly accessed from the peripheral video consoles, and hard copies produced when needed using a laser camera. A PACS can be integrated with the department's reporting system and the hospital's computerized information system, including the laboratories. Digital images can also be transmitted to other hospitals.

### Advantages of Pacs

1. Once correctly acquired onto the PACS, no image can ever be lost or mystified and is always available when needed. This prevents the repeat radiation exposure to patient because of loss of previous key investigations.
2. PACS facilitates the comparison of patient's current and previous examinations, and examinations performed on the same body part using different imaging modalities.
3. All images remain accessible from the PACS archives every time.
4. Simultaneous multi location viewing of the same image is possible on any workstation



connected to the PACS network.

5. Image retrieval is much quicker from PACS than conventional film.
6. The benefits of a computerized system is that all images correctly and permanently remain in their correct orientation and chronological order.
7. Viewing the images on monitors allow post processing soft-copy manipulations.
8. With use of PACS there is no need of film packets, processing chemicals and dark rooms.
9. PACS sets the stage for practice of teleradiology.

### **Disadvantages of Pacs**

1. PACS is an expensive technology.
2. Complex nature of technology requires change of work pattern and training of users.
3. Absolute dependency of hospital on PACS once it becomes completely film less.
4. A dedicated maintenance program is required for proper functioning.

### **Review Questions**

1. What is the digital radiography? What are the advantages and disadvantage over film screen system?
2. What are the benefits and limitations of computed radiography?
3. What are the types of digital radiography?
4. What is the full form of PACS?
5. PACS is better than conventional X- ray film. Yes/No why?
6. Define the role of PACS in modern day radiology.
7. Write the basic principle of PACS.
8. Write the advantages and disadvantages of PACS

### **References**

1. Text Book of Radiology for Residents and Technicians, 4<sup>th</sup> Edition, Prof S.K. Bhargava, C.B.S. Publishers, Darya Ganj, New Delhi
2. Clark Positioning in Radiography, 11<sup>th</sup> Edition, Edited by: R.A. Swalkar & E. Naylor, Apan Publication. Rockwilli, Maryland
3. Principle of Radiological Physics by Donald T. Graham
4. Radiological Science for Technologists, by Stewart Carlyle Bushong, 9th Edition; Mosby, Elsvier
5. Radiological Procedure, Prof S.K. Bhargava, Peepee Bros, Darya Ganj, Delhi







## **CENTRAL BOARD OF SECONDARY EDUCATION**

Shiksha Kendra, 2, Community Centre, Preet Vihar, Delhi-110301

Tel: 011-22527183 • Fax: 011-22526580

E-mail : [voc.cbse@gmail.com](mailto:voc.cbse@gmail.com) • Website : [www.cbse.nic.in](http://www.cbse.nic.in)